Cureus
Part of SPRINGER NATURE

Open Access Case Report

# Pleural Metastasis in Epithelioid Angiosarcoma

Martha Milena Alfonso Gamba [1], Daniel Barragan [2], Luisa Gomez [3], Laura S. Camaro [3], Alejandro Corredor Cala [4]

1. Thoracic Surgery, Universidad El Bosque, Bogotá, COL 2. Emergency Medicine, Méderi Hospital Universitario Mayor, Bogotá, COL 3. Medicine, Universidad del Rosario, Bogotá, COL 4. General Medicine, Fundación Cardioinfantil, Bogotá, COL

**Corresponding author:** Daniel Barragan, barraganrativad@gmail.com

**Review began** 08/20/2026
**Review ended** 10/11/2026
**Published** 10/18/2026

© **Copyright** 2026
Alfonso Gamba et al. This is an open access article distributed under the terms of the Creative Commons Attribution License CC-BY 4.0., which permits unrestricted use, distribution, and reproduction in any medium, provided the original author and source are credited.

**DOI:** 10.7759/cureus.118090

## Abstract

Epithelioid angiosarcoma (EAS) is a rare, highly aggressive endothelial cell malignancy characterized by a propensity for rapid metastatic spread and an exceptionally poor prognosis. Diagnosing EAS remains a major clinical and histopathological challenge due to its atypical cellular morphology, mimicry of poorly differentiated carcinomas or mesotheliomas, and insidious, nonspecific clinical presentation, which frequently leads to diagnostic delays. Given the scarcity of literature on this entity, expanding the current clinical knowledge base is essential to facilitate early identification. In this report, we present the case of a 60-year-old woman with a history of pituitary adenoma resection who presented with progressive chest pain, weight loss, and symptomatic anemia, which initially suggested a non-ST-segment elevation myocardial infarction (NSTEMI), given the presentation of precordial pain and the results of the cardiac biomarker evaluation, but was later identified as metastatic disease. Imaging and biopsy revealed a rare metastatic EAS involving the liver, spleen, and pleura, prompting palliative care, video-assisted thoracoscopic surgery (VATS), and pleurodesis. This case serves as a critical reminder of the diagnostic challenges posed by atypical pleural metastases, which can uniquely mimic primary pulmonary or mesothelial malignancies. By highlighting this rare secondary manifestation, this report underscores the necessity of combining meticulous immunohistochemical analysis with a principal emphasis on thoracoscopic findings to confirm the diagnosis.

**Categories:** General Surgery, Oncology, Anatomy
**Keywords:** angiosarcoma, epithelioid angiosarcoma, pleural metastasis, thoracic oncology, thoracoscopy

## Introduction

Angiosarcoma is a rare malignant mesenchymal neoplasm arising from vascular and lymphatic endothelial cells, accounting for less than 1% of soft tissue sarcomas [1,2]. Although its etiology and pathogenesis are not completely understood, several associated risk factors have been identified, including radiation exposure, chronic lymphedema, family history, and exposure to environmental carcinogens such as vinyl chloride, arsenic, and thorium dioxide [1-3].

The histopathological diagnosis of angiosarcoma represents a significant challenge, as its morphological features may resemble those of benign vascular proliferations. This neoplasm typically exhibits an infiltrative growth pattern and lacks a well-defined capsule, making it difficult to distinguish tumor tissue from adjacent healthy tissue. The most characteristic histological feature is the presence of atypical malignant endothelial cells with marked pleomorphism, which may display round, spindle-shaped, or polygonal morphology and, in some cases, adopt an epithelioid phenotype, leading to diagnostic confusion with other neoplasms [1,3].

Epithelioid angiosarcoma (EAS) is characterized by a highly aggressive behavior, poor prognosis, and a strong tendency toward early metastatic dissemination. It is distinguished by the absence of typical morphology and clinical presentation; this can hinder timely recognition and contribute to delayed diagnosis [1,3].

This tumor most commonly arises in deep soft tissues and, less frequently, in organs such as the skin, liver, breast, and bone. It has a strong propensity for early metastasis to lymph nodes and multiple solid organs, with the lung being one of the most frequently involved sites [1].

In this article, we report a stage IV EAS with splenic, hepatic, and pleural involvement. This case is considered atypical because it occurred in an individual who did not meet the standardized risk criteria and because of the scarce literature describing pleural metastasis in this type of tumor, making the present report of significant clinical relevance.

## Case Presentation

A 60-year-old woman with a history of pituitary adenoma resection in 2023 presented to the emergency

department with progressive retrosternal chest pain associated with asthenia, adynamia, nausea, early satiety, paresthesia of the hands, unintentional weight loss of 12 kg over two months, and a transient syncopal episode. On admission, the patient exhibited sinus tachycardia and transient hypotension.

Initial laboratory evaluation demonstrated moderate microcytic anemia, marked thrombocytosis, hypoalbuminemia, mild hyponatremia, and elevated troponin I levels. Peripheral blood smear revealed anisocytosis, hypochromia, and microcytosis. Chest radiography showed no acute cardiopulmonary abnormalities or pleural effusion at the time of admission.

Given the elevated cardiac biomarkers in the setting of severe anemia and tachycardia, non-ST-segment elevation myocardial infarction (NSTEMI) was initially suspected. The electrocardiogram demonstrated sinus tachycardia without ST-segment elevation or significant ischemic changes. Accordingly, antithrombotic therapy was initiated while further evaluation was undertaken to clarify the etiology of the myocardial injury. During inpatient evaluation, computed tomography (CT) pulmonary angiography excluded pulmonary embolism but incidentally demonstrated multiple hepatic lesions. Subsequent abdominal magnetic resonance imaging (MRI) confirmed diffuse hepatic involvement and a hypervascular splenic mass (Figure *1*).

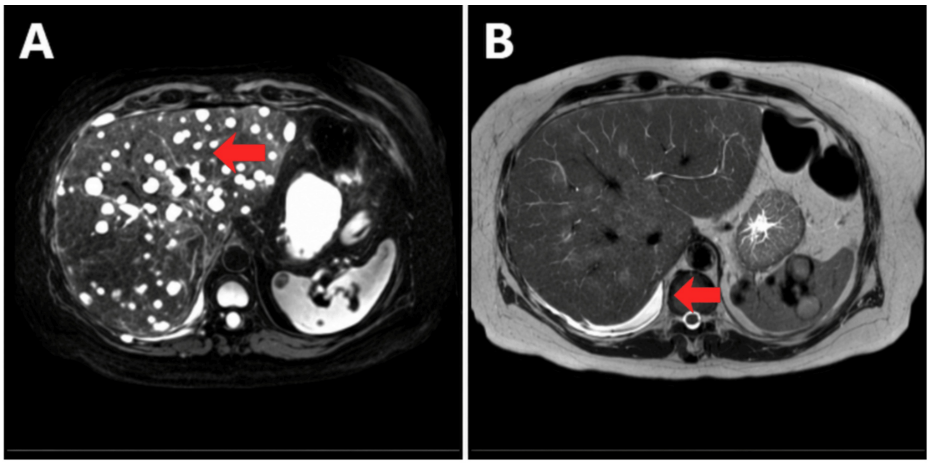


**FIGURE 1: Abdominal imaging findings**

(A) Contrast-enhanced abdominal computed tomography: Transverse view showing multiple hypoattenuating, ill-defined hepatic lesions (red arrow) involving both lobes, suggestive of diffuse metastatic involvement. (B) Abdominal magnetic resonance imaging (T2-weighted): Identification of a prominent, heterogeneous, vascularized mass (red arrow) consistent with a primary vascular neoplasm and pleural thickening, further supporting the diagnosis of systemic metastatic dissemination.

Ultrasound-guided liver biopsy demonstrated a poorly differentiated malignant neoplasm composed of atypical epithelioid cells. Immunohistochemical analysis showed diffuse positivity for CD31, vimentin, cytokeratin cocktail, and EMA, with focal D2-40 expression. CD34 and CDX2 were negative.

Following oncological counseling, the patient declined systemic chemotherapy and was discharged with palliative follow-up.

Two months later, the patient was readmitted with progressive right-sided pleuritic chest pain, dyspnea at rest, lower extremity edema, and a recurrent massive pleural effusion, previously treated at an outside institution with repeated therapeutic thoracenteses, without a definitive underlying diagnosis.

Physical examination revealed oxygen saturation of 85% on room air, absent breath sounds throughout the right hemithorax, and bilateral grade II lower-extremity edema. Laboratory tests demonstrated leukocytosis with neutrophilia, persistent anemia, and thrombocytosis. Chest radiography showed complete opacification of the right hemithorax secondary to massive pleural effusion.

Chest CT excluded acute pulmonary embolism and demonstrated free right pleural effusion associated with diffuse nodular pleural thickening. Diagnostic and therapeutic thoracentesis yielded 1600 mL of serosanguineous exudative fluid with lymphocytic predominance, consistent with malignant pleural effusion. An indwelling pleural catheter was subsequently placed for symptom control.

Follow-up imaging demonstrated progressive pleural and pulmonary disease characterized by irregular nodular pleural thickening and a subpleural spiculated pulmonary nodule in the right upper lobe. MRI

revealed hepatic, splenic, and pleural lesions with T1 hypointensity, T2 hyperintensity, restricted diffusion, and heterogeneous peripheral enhancement with central necrotic and hemorrhagic components (Figure 2).

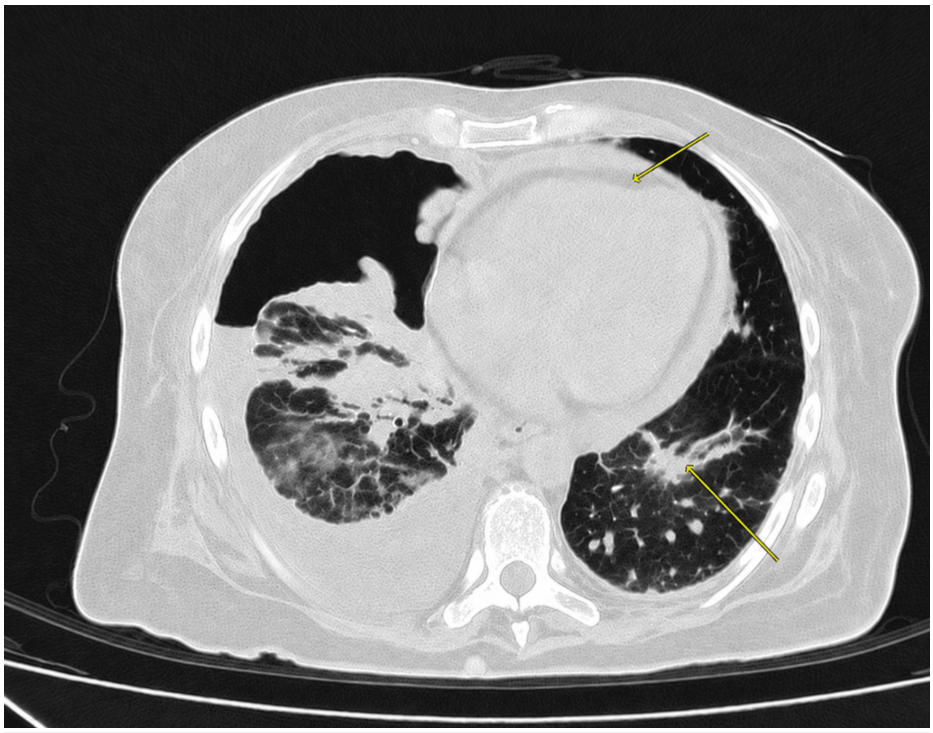

**FIGURE 2: Post-thoracentesis chest computed tomography scan**

Post-thoracentesis chest computed tomography scan demonstrating residual pleural effusion, right lung volume loss associated with passive subsegmental atelectasis and ground-glass opacities, right pleural thickening and nodular irregularity as signs of secondary seeding, spiculated nodule in the right upper lobe, and mild pericardial effusion.

Because of progressive pleural disease, the patient underwent video-assisted thoracoscopic surgery (VATS) with pleural biopsy and chemical pleurodesis using povidone-iodine due to the institutional unavailability of medical-grade talc. Thoracoscopic evaluation demonstrated extensive metastatic disease characterized by multiple friable violaceous nodules involving the parietal and visceral pleura, diaphragm, and pericardium. Representative biopsies from the pleura and pericardium were obtained (Figure 3).

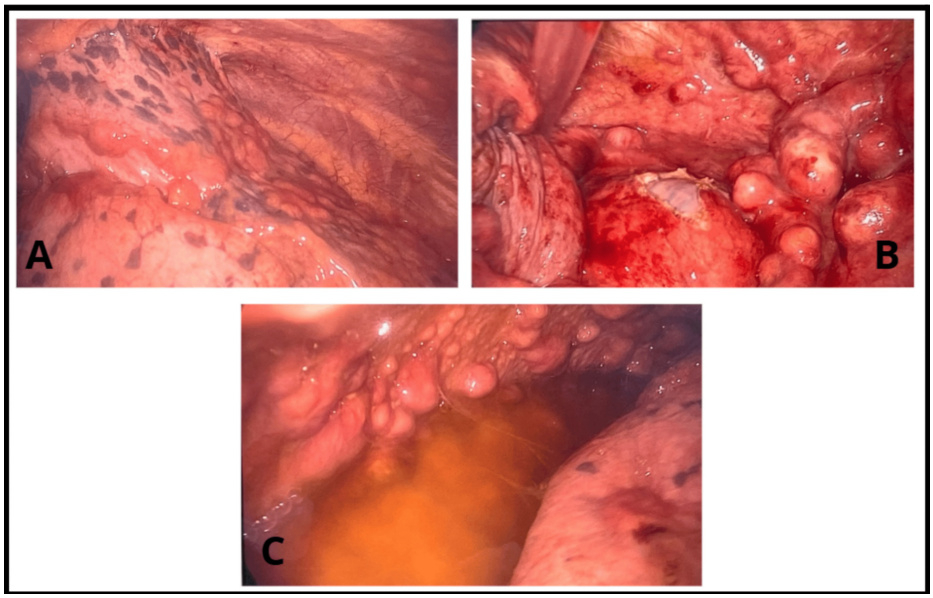


**FIGURE 3: Intraoperative thoracoscopic findings**

(A-C) Images demonstrating the widespread metastatic involvement of the thoracic cavity. Multiple nodular, erythematous, and whitish lesions consistent with malignancy are observed involving the parietal pleura, visceral pleura, and diaphragm, characteristic features of a primary vascular neoplasm with secondary dissemination. A moderate amount of serous fluid is also noted.

Histopathological examination revealed diffuse infiltration by malignant epithelioid cells with vesicular nuclei, prominent nucleoli, abundant eosinophilic cytoplasm, and focal primitive vascular lumina containing erythrocytes. Immunohistochemical staining demonstrated diffuse positivity for CD31, CK7, and AE1/AE3, with focal D2-40 and CD34 expression. Calretinin and WT1 were negative, arguing against mesothelial differentiation, while the absence of CK20 expression made metastatic gastrointestinal carcinoma less likely. The overall immunophenotypic profile, particularly the diffuse CD31 expression, supported an endothelial origin.

Postoperatively, the patient required short-term intensive care support because of persistent hypotension and recurrent febrile episodes. Extensive infectious workup was negative, and tumor-related fever was considered the most likely diagnosis. The patient subsequently improved clinically and was discharged after a 21-day hospitalization with outpatient follow-up by oncology, pain management, and palliative care services.

## Discussion

EAS is an exceedingly rare and aggressive neoplasm with a high propensity for metastatic dissemination. While its primary differential diagnoses include hepatocellular carcinoma, epithelioid hemangioendothelioma, and atypical cavernous hemangioma, these entities are distinguished by their histological architecture and degree of cellular atypia. Crucially, they lack the specific immunohistochemical profile of EAS, making the expression of vascular markers indispensable for definitive diagnostic confirmation [1,3].

This neoplasm is a highly aggressive endothelial malignancy characterized by infiltrative growth and a propensity for early nodal and distant metastasis, particularly to the lungs, bone, soft tissue, and skin, contributing to its aggressive clinical course and poor prognosis [2,3].

Clinical manifestations vary according to the anatomical site involved and may include constitutional symptoms such as weight loss, asthenia, adynamia, night sweats, and intermittent fever. In this case, pleural and diaphragmatic involvement manifested as progressive dyspnea, chest pain, cough, and recurrent pleural effusion [4].

Diagnostic imaging may support suspicion of EAS and help define disease extent, as it lacks pathognomonic findings. However, imaging can reveal findings suggestive of this highly aggressive tumor, depending on the affected organ. In the case presented, chest radiography is often the first-line imaging modality for diagnosis, despite its low specificity. Nonspecific opacities may be found in the lung fields, or pleural effusion may be present, frequently unilateral. CT also reveals pleural effusions, but additionally, it typically shows more specific findings such as heterogeneous lesions with areas of necrosis and hemorrhage, intense

enhancement after contrast administration demonstrating hypervascularity, irregular pleural thickening, the presence of pulmonary nodules, and pleural and pulmonary masses. Most of these findings were present in the case presented above. More specific imaging techniques such as MRI and positron emission tomography (PET)-CT provide better tissue characterization and metabolic uptake for the detection of metastases, respectively [5,6].

Despite these clinical and imaging findings, diagnostic confirmation relies on histopathological and immunohistochemical evaluation. EAS is characterized by epithelioid cells with abundant cytoplasm, pleomorphic nuclei, and frequent mitotic figures, which may mimic metastatic carcinoma or mesothelioma [7]. Zhang et al. emphasize that endothelial markers such as CD31, ERG, FLI-1, and factor VIII-related antigen are essential to establish the diagnosis, while epithelial markers may be negative or focally positive, increasing the risk of misdiagnosis if a complete immunohistochemical panel is not performed. This is a critical point, as treatment and prognosis differ significantly compared to other pleural malignancies [7,8].

EAS is also associated with early metastasis to lymph nodes and solid organs, particularly the lung, liver, and brain. Durani et al. reported a case of EAS presenting with pleural effusion and pericardial involvement, reflecting its ability to disseminate to serosal cavities and its potential to cause rapidly progressive complications [6]. The presence of pleural metastasis represents a sign of advanced disease and is associated with limited survival of approximately 6-12 months [9,10].

The management of EAS remains challenging because of its highly aggressive biological behavior and the absence of standardized treatment protocols. For localized disease, complete surgical resection with negative margins is considered the preferred therapeutic approach whenever feasible. However, in pleuropulmonary involvement, surgery is frequently limited by the diffuse and infiltrative nature of the tumor. In patients with metastatic or unresectable disease, systemic chemotherapy is the mainstay of treatment, with agents such as doxorubicin, ifosfamide, and paclitaxel demonstrating variable clinical benefit. Targeted antiangiogenic therapies have also been explored in selected cases, although their efficacy remains uncertain. Overall, the available evidence is limited by the extreme rarity of EAS, with current treatment recommendations largely based on small retrospective series and isolated case reports [9,11].

## Conclusions

This case describes an advanced EAS with pleural involvement, diagnosed through the integration of clinical presentation, imaging findings, histopathological evaluation, and a compatible immunohistochemical profile. The patient exhibited an aggressive clinical course with systemic dissemination, highlighting the diagnostic challenges posed by the nonspecific presentation and the morphological overlap of EAS with other pleural malignancies, particularly malignant mesothelioma and metastatic carcinoma.

The key learning point from this report is that EAS should be considered in patients with rapidly progressive pleural lesions, particularly those presenting with hemorrhagic pleural effusion, irregular pleural thickening, or pleural nodularity of unclear origin. Accurate diagnosis requires a comprehensive immunohistochemical panel and close clinicopathological correlation. Early recognition is essential to guide appropriate multidisciplinary management, despite the generally poor prognosis associated with this highly aggressive neoplasm.

## Additional Information

### Author Contributions

All authors have reviewed the final version to be published and agreed to be accountable for all aspects of the work.

**Concept and design:** Daniel Barragan, Martha Milena Alfonso Gamba, Luisa Gomez, Laura S. Camaro, Alejandro Corredor Cala

**Acquisition, analysis, or interpretation of data:** Daniel Barragan, Martha Milena Alfonso Gamba, Luisa Gomez, Laura S. Camaro, Alejandro Corredor Cala

**Drafting of the manuscript:** Daniel Barragan, Martha Milena Alfonso Gamba, Luisa Gomez, Laura S. Camaro, Alejandro Corredor Cala

**Critical review of the manuscript for important intellectual content:** Daniel Barragan, Martha Milena Alfonso Gamba, Laura S. Camaro, Alejandro Corredor Cala

**Supervision:** Daniel Barragan, Martha Milena Alfonso Gamba, Luisa Gomez

### Disclosures

**Human subjects:** Informed consent for treatment and open access publication was obtained or waived by all

participants in this study. **Conflicts of interest:** In compliance with the ICMJE uniform disclosure form, all authors declare the following: **Payment/services info:** All authors have declared that no financial support was received from any organization for the submitted work. **Financial relationships:** All authors have declared that they have no financial relationships at present or within the previous three years with any organizations that might have an interest in the submitted work. **Other relationships:** All authors have declared that there are no other relationships or activities that could appear to have influenced the submitted work.

## References

1. Kim WJ, Kim HK: Current understanding of angiosarcoma: disease biology and evolving treatment . Arch Craniofac Surg. 2023, 24:203-10. 10.7181/acfs.2023.00409
2. Woo JJ, Kim Y, An JK, Lee H: Primary pleural epithelioid angiosarcoma manifesting as a loculated hemothorax: a case report and literature review focusing on CT findings. Radiol Case Rep. 2021, 16:3072-5. 10.1016/j.radcr.2021.07.048
3. Hillenbrand T, Menge F, Hohenberger P, Kasper B: Primary and secondary angiosarcomas: a comparative single-center analysis. Clin Sarcoma Res. 2015, 5:14.
4. Samargandi R: Etiology, pathogenesis, and management of angiosarcoma associated with implants and foreign body: clinical cases and research updates. Medicine (Baltimore). 2024, 103:e37932. 10.1097/MD.0000000000037932
5. Dörr-Jerat NM, May C, Knolle J, Schmidt S, Krüger M: Case report: epithelioid angiosarcoma of the pleura . Front Surg. 2024, 11:1393159. 10.3389/fsurg.2024.1393159
6. Durani U, Gallo de Moraes A, Beachey J, Nelson D, Robinson S, Anavekar NS: Epithelioid angiosarcoma: a rare cause of pericarditis and pleural effusion. Respir Med Case Rep. 2018, 24:77-80. 10.1016/j.rmcr.2018.04.008
7. Kuang R, Li S, Wang Y: Primary cerebral epithelioid angiosarcoma: a case report . BMC Neurol. 2023, 23:49. 10.1186/s12883-023-03085-x
8. Zhang S, Zheng Y, Liu W, Yu X: Primary epithelioid angiosarcoma of the pleura: a case report and review of literature. Int J Clin Exp Pathol. 2015, 8:2153-8.
9. Sakamoto A, Takahashi Y, Oda Y, Iwamoto Y: Aggressive clinical course of epithelioid angiosarcoma in the femur: a case report. World J Surg Oncol. 2014, 12:281. 10.1186/1477-7819-12-281
10. Sinkler MA, Ullah A, Wehrle CJ, Ibrahim MA, White J: Primary pleural epithelioid angiosarcoma with extensive and rapid metastasis to brain and bilateral adrenal glands. Cureus. 2020, 12:e9982. 10.7759/cureus.9982
11. Rojas S, Rey Chaves CE, Robledo S, Conde D, Sabogal Olarte JC: Primary hepatic angiosarcoma: a systematic review. Ann Med Surg (Lond). 2024, 86:1601-5. 10.1097/MS9.0000000000001584