Cureus
Part of SPRINGER NATURE

Open Access Case Report

Small Bowel Obstruction Secondary to Trichobezoar: A Case Report and Review of the Literature

Review began 10/24/2026
Review ended 11/22/2026
Published 11/25/2026

© **Copyright** 2026
Washington et al. This is an open access article distributed under the terms of the Creative Commons Attribution License CC-BY 4.0., which permits unrestricted use, distribution, and reproduction in any medium, provided the original author and source are credited.

DOI: 10.7759/cureus.120268

Miles J. Washington [1], James C. Montgomery [2], Saptarshi Biswas [3]

1. Medical Education, University of South Carolina School of Medicine Columbia, Columbia, USA 2. General Surgery, Grand Strand Healthcare System, Myrtle Beach, USA 3. Surgery, Grand Strand Medical Center, Myrtle Beach, USA

Corresponding author: Miles J. Washington, milesjw@uscmed.sc.edu

Abstract

Small bowel obstruction (SBO) secondary to trichobezoar is a rare etiology of mechanical obstruction, most commonly associated with trichotillomania and trichophagia in pediatric and adolescent patients. We present the case of a 15-year-old female with SBO caused by a trichobezoar. The patient underwent operative management with removal of the obstructing bezoar. This case highlights the importance of considering trichobezoar in the differential diagnosis of SBO in adolescent patients, particularly when relevant behavioral risk factors are present. Risk factors, diagnostic evaluation, treatment strategies, and relevant literature are reviewed.

Categories: General Surgery, Gastroenterology
Keywords: gastric trichobezoar, mechanical small bowel obstruction, rapunzel syndrome, terminal ileum trichobezoar, trichobezoar in adolescents

Introduction

Trichobezoar is a rare cause of mechanical small bowel obstruction (SBO). Bezoars are classified according to their composition into phytobezoars (plant material), trichobezoars (hair), pharmacobezoars (medications), and lactobezoars (milk protein) [1]. Bezoars account for approximately 0.4%-4% of mechanical bowel obstructions, while trichobezoars account for less than 6% of all bezoars [2,3]. Trichobezoars occur predominantly in adolescent and young adult females and are strongly associated with trichotillomania and trichophagia [4].

Trichotillomania, or hair-pulling disorder, is classified among obsessive-compulsive and related disorders and has an estimated current prevalence of approximately 1.7% among U.S. adults [5]. Trichophagia, the compulsive ingestion of hair, reportedly occurs in an estimated 5%-30% of patients with trichotillomania, and 1%-37.5% of those patients may develop a trichobezoar [6]. Because human hair is resistant to enzymatic degradation and peristaltic propulsion, chronic ingestion can lead to accumulation within the gastric folds and eventual trichobezoar formation [7-10].

Most trichobezoars are retained within the stomach by the pylorus; however, they may extend or migrate into the small intestine, resulting in mechanical obstruction [3,7,8]. Rapunzel syndrome is a rare variant in which a gastric trichobezoar extends beyond the pylorus into the small bowel, occasionally reaching the colon [1,10,11]. Although the exact incidence of Rapunzel syndrome is not well established, it remains an uncommon and potentially serious complication of trichobezoar formation [7-10]. Here, we present a case of SBO in an adolescent female caused by a small-bowel trichobezoar with a separate gastric trichobezoar.

Case Presentation

The patient was a 15-year-old female who presented to the emergency department with a five-day history of abdominal pain, bloating, nausea, and vomiting. Her last bowel movement was the day before presentation, and she denied passing flatus. Her medical history was notable for trichotillomania from 2022 to 2023, although she denied recent hair-pulling behavior. She had no history of abdominal surgery.

Computed tomography (CT) of the abdomen and pelvis demonstrated mechanical SBO with multiple dilated small-bowel loops and a transition point in the right lower quadrant associated with elongated intraluminal material, concerning for an obstructing trichobezoar. The stomach was also distended with fluid and intragastric material (Figures *1*-*3*). Given the mechanical obstruction and concern for an obstructing trichobezoar, the patient underwent exploratory laparotomy.

How to cite this article
Washington M J, Montgomery J C, Biswas S (November 25, 2026) Small Bowel Obstruction Secondary to Trichobezoar: A Case Report and Review of the Literature. Cureus 18(11): e120268. DOI 10.7759/cureus.120268

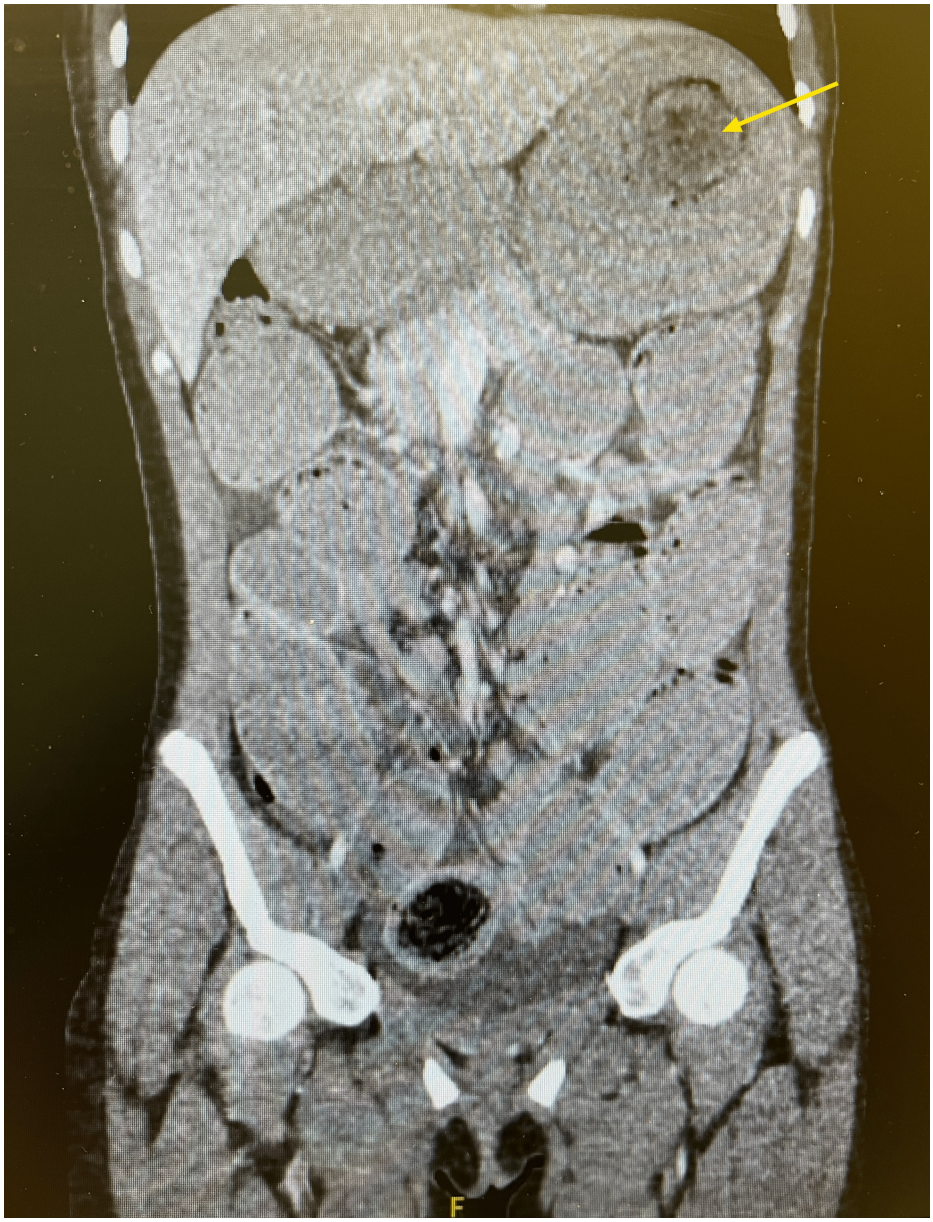

FIGURE 1: Coronal CT image demonstrating intragastric material.

The yellow arrow indicates intragastric material confirmed at surgery to be a gastric trichobezoar.

CT, computed tomography

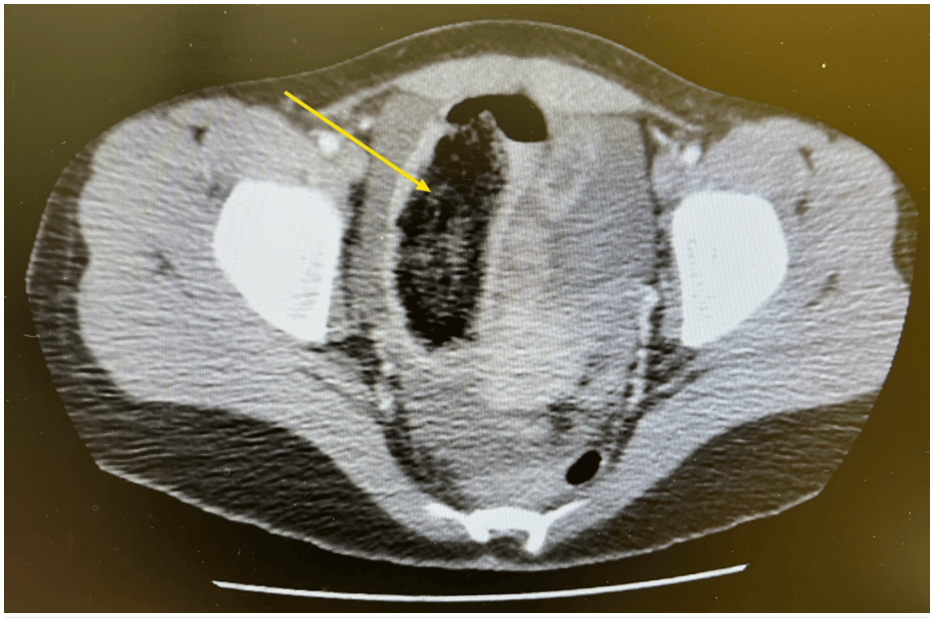

FIGURE 2: Axial CT image demonstrating a small-bowel trichobezoar.

The yellow arrow indicates an elongated intraluminal mass with a mottled gas pattern, corresponding to the surgically confirmed small-bowel trichobezoar responsible for the obstruction.

CT, computed tomography

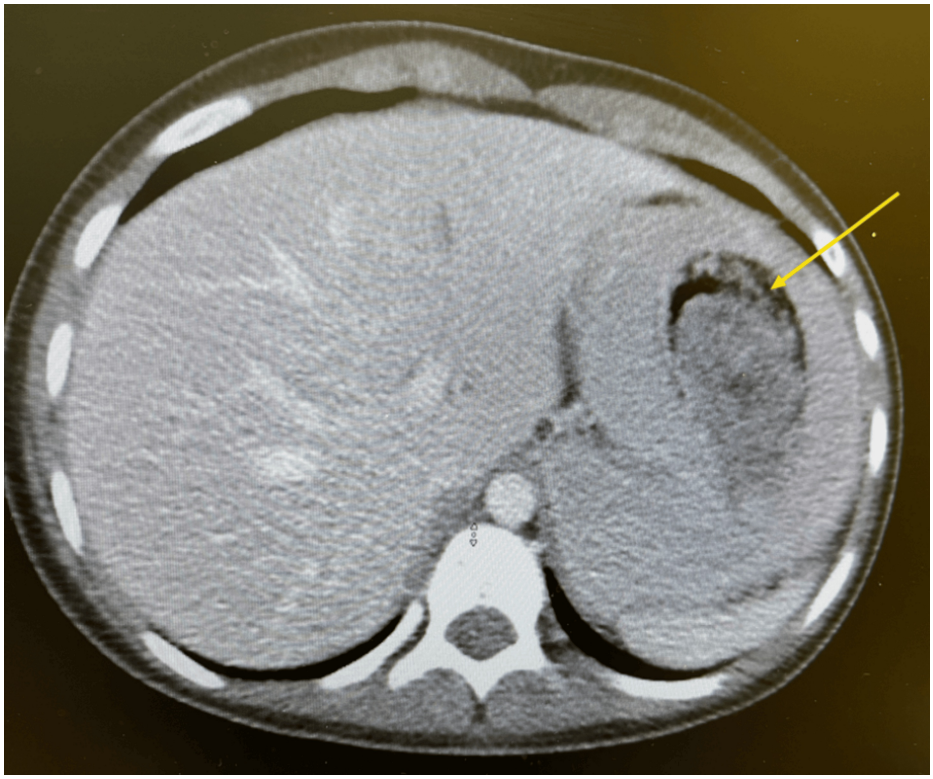

FIGURE 3: Axial CT image demonstrating intragastric material.

The yellow arrow indicates intragastric material subsequently confirmed at surgery to be a gastric trichobezoar. The gastric lesion was not definitively identified as a bezoar on the initial CT interpretation.

CT, computed tomography

Upon entering the abdomen through a lower midline incision, diffusely dilated loops of small bowel were encountered. The bowel was eviscerated and examined, revealing a clear transition point at a large intraluminal mass approximately 200 cm proximal to the terminal ileum. A longitudinal enterotomy was created proximal to the mass, which was milked back through the enterotomy and removed intact. Gross examination confirmed a trichobezoar, and the specimen was passed off the field (Figure *4*). The enterotomy was closed transversely in two layers using interrupted 3-0 Vicryl (Ethicon, Inc., Raritan, NJ) sutures followed by reinforcing 3-0 silk Lembert sutures.



FIGURE 4: Small-bowel trichobezoar removed intact through the enterotomy.

The remainder of the small bowel was inspected, and no additional small-bowel abnormalities were identified. Palpation of the stomach revealed a second intraluminal mass with similar characteristics. The stomach was stabilized with Babcock clamps, and an anterior gastrotomy was sharply created. The gastric mass was grasped and delivered through the gastrotomy intact, again grossly consistent with a trichobezoar (Figure *5*). The gastrotomy was closed using a size 60 TA stapler, and a 19-French round Blake drain was placed adjacent to the gastrotomy repair. The patient tolerated the procedure well, emerged from anesthesia without incident, and was transferred to the postanesthesia care unit (PACU) in stable condition.



FIGURE 5: Gastric trichobezoar removed intact through the gastrotomy.

Discussion

Trichobezoars are uncommon gastrointestinal foreign bodies that most often form in the stomach and are classically associated with trichotillomania and trichophagia. Patients may initially have nonspecific abdominal symptoms, but delayed recognition can lead to ulceration, bleeding, perforation, intussusception, or mechanical obstruction [7,8]. SBO caused by a trichobezoar is particularly uncommon because ingested hair typically accumulates within the gastric folds and is retained by the pylorus [7,8].

Our case is notable for mechanical SBO caused by a small-bowel trichobezoar with a second, separate trichobezoar in the stomach. This differs from classic Rapunzel syndrome, in which a gastric trichobezoar extends beyond the pylorus as a continuous tail [7,9,12]. Garcia-Ramirez et al. described SBO caused by a separate ileal trichobezoar in a patient whose gastric trichobezoar extended into the duodenum and therefore met criteria for Rapunzel syndrome [3]. In our patient, the gastric and small-bowel masses were

discrete. This pattern may represent distal migration of a detached fragment or separate bezoar formation. Regardless of mechanism, identification of one trichobezoar should prompt inspection of the remaining gastrointestinal tract for synchronous lesions [8,10].

Patients with trichobezoar-related obstruction often present with nonspecific symptoms, including abdominal pain, nausea, vomiting, bloating, early satiety, weight loss, and constipation [7,8]. As obstruction progresses, abdominal distention, obstipation, and inability to pass flatus may become more prominent [11]. A history of trichotillomania or trichophagia can support the diagnosis, but the history may be remote or difficult to obtain. Patients may not disclose the behavior because of embarrassment, stigma, or fear of reprimand [6,8]. Trichobezoar should therefore remain in the differential diagnosis for young female patients presenting with bowel obstruction, particularly when there is a known psychiatric or behavioral history [7,8].

In an adolescent presenting with abdominal pain, vomiting, distention, and inability to pass flatus, mechanical bowel obstruction is an important diagnostic consideration. Alternative causes of SBO include internal or external hernias, intussusception, volvulus, and inflammatory strictures [11]. A history of trichotillomania should additionally prompt consideration of a trichobezoar. In this case, CT demonstrated a transition point associated with elongated intraluminal material, supporting concern for an obstructing bezoar.

Management depends on bezoar size, location, and the presence of complications. Small gastric trichobezoars may be amenable to endoscopic removal, although dense or large hair conglomerates are difficult to fragment and remove endoscopically [1,8]. Large, complicated, or obstructing trichobezoars generally require operative removal [1,8,10]. In SBO, exploratory laparotomy permits identification of the transition point, assessment of bowel viability, removal of the obstructing mass through enterotomy, and inspection of the remaining bowel [10]. A synchronous gastric trichobezoar may require gastrotomy for complete removal. Surgical treatment addresses the acute complication but not the underlying behavior. Psychiatric follow-up is therefore an important part of recurrence prevention, particularly when trichotillomania, trichophagia, or associated psychiatric conditions remain active [8,10].

Limitations

This report is limited by the inherent constraints of a single-patient case report. The mechanism responsible for the two discrete trichobezoars cannot be determined with certainty; the small-bowel mass may have represented a detached and migrated fragment or a separately formed bezoar. The available literature remains composed largely of case reports and small case series, limiting direct comparison of endoscopic, laparoscopic, and open surgical approaches [8,10]. Postoperative information available to the authors was limited to the immediate recovery period. Subsequent inpatient recovery, discharge, and outpatient follow-up details were unavailable. Nevertheless, the operative findings reinforce the importance of examining the stomach and remaining bowel when one trichobezoar is identified.

Conclusions

Trichobezoar is a rare but important cause of SBO in adolescent patients with a history of trichotillomania or trichophagia. This case demonstrates that a small-bowel trichobezoar may coexist with a separate gastric trichobezoar without the continuous postpyloric extension seen in classic Rapunzel syndrome. A remote or denied behavioral history should not exclude the diagnosis. Operative management permits removal of the obstructing mass, assessment of bowel viability, and inspection of the stomach and remaining bowel for synchronous lesions. Long-term management should also include psychiatric follow-up to address the underlying behavior and reduce the risk of recurrence.

Additional Information

Author Contributions

All authors have reviewed the final version to be published and agreed to be accountable for all aspects of the work.

Acquisition, analysis, or interpretation of data: Miles J. Washington, James C. Montgomery

Drafting of the manuscript: Miles J. Washington

Critical review of the manuscript for important intellectual content: Miles J. Washington, Saptarshi Biswas , James C. Montgomery

Concept and design: Saptarshi Biswas

Disclosures

Human subjects: Informed consent for treatment and open access publication was obtained or waived by all participants in this study. **Conflicts of interest:** In compliance with the ICMJE uniform disclosure form, all authors declare the following: **Payment/services info:** All authors have declared that no financial support was received from any organization for the submitted work. **Financial relationships:** All authors have declared that they have no financial relationships at present or within the previous three years with any organizations that might have an interest in the submitted work. **Other relationships:** All authors have declared that there are no other relationships or activities that could appear to have influenced the submitted work.

References

1. Iwamuro M, Okada H, Matsueda K, Inaba T, Kusumoto C, Imagawa A, Yamamoto K: Review of the diagnosis and management of gastrointestinal bezoars. World J Gastrointest Endosc. 2015, 7:336-45. 10.4253/wjge.v7.i4.336
2. Dikicier E, Altintoprak F, Ozkan OV, Yagmurkaya O, Uzunoglu MY: Intestinal obstruction due to phytobezoars: an update. World J Clin Cases. 2015, 3:721-6. 10.12998/wjcc.v3.i8.721
3. García-Ramírez BE, Nuño-Guzmán CM, Zaragoza-Carrillo RE, Salado-Rentería H, Gómez-Abarca A, Corona JL: Small-bowel obstruction secondary to ileal trichobezoar in a patient with Rapunzel syndrome . Case Rep Gastroenterol. 2018, 12:559-65. 10.1159/000492810
4. Lyons D: Large gastric trichobezoar causing failure to thrive and iron deficiency anaemia in an adolescent girl: a case report emphasising the imaging findings and review of the literature. BJR Case Rep. 2019, 5:20180080. 10.1259/bjrcr.20180080
5. Grant JE, Dougherty DD, Chamberlain SR: Prevalence, gender correlates, and co-morbidity of trichotillomania. Psychiatry Res. 2020, 288:112948. 10.1016/j.psychres.2020.112948
6. Tiago S, Nuno M, João A, Carla V, Gonçalo M, Joana N: Trichophagia and trichobezoar: case report . Clin Pract Epidemiol Ment Health. 2012, 8:43-5. 10.2174/1745017901208010043
7. Gonuguntla V, Joshi DD: Rapunzel syndrome: a comprehensive review of an unusual case of trichobezoar . Clin Med Res. 2009, 7:99-102. 10.3121/cmr.2009.822
8. Alami Hassani Z, Andaloussi S, Annattah S, Dalero O, El Madi A: Trichobezoars in pediatric surgery: a narrative review of clinical perspectives, surgical strategies, and psychological considerations. Pediatr Med. 2025, 8:20. 10.21037/pm-25-41
9. Fallon SC, Slater BJ, Larimer EL, Brandt ML, Lopez ME: The surgical management of Rapunzel syndrome: a case series and literature review. J Pediatr Surg. 2013, 48:830-4. 10.1016/j.jpedsurg.2012.07.046
10. Gorter RR, Kneepkens CM, Mattens EC, Aronson DC, Heij HA: Management of trichobezoar: case report and literature review. Pediatr Surg Int. 2010, 26:457-63. 10.1007/s00383-010-2570-0
11. Schick MA, Kashyap S, Collier SA, Meseeha M: Small Bowel Obstruction . StatPearls, Treasure Island, FL; 2025.
12. Lopes LR, Oliveira PS, Pracucho EM, Camargo MA, de Souza Coelho Neto J, Andreollo NA: The Rapunzel syndrome: an unusual trichobezoar presentation. Case Rep Med. 2010, 2010:841028. 10.1155/2010/841028