Cureus
Part of SPRINGER NATURE

Open Access Case Report

Varied Oculomotor Presentations in Posterior Circulation Ischemic Stroke: A Case Series Highlighting Rare Fascicular and Nuclear Lesions

Enes Gumus [1, 2], Maimona Weisy [1, 2], Sevil Yusifli [2], Hatice Yelda Yildiz [2], Yavuz Bekmezci [2], Yakup Krespi [2]

1. Faculty of Medicine, Istinye University, Istanbul, TUR 2. Department of Neurology, Istinye University, Istanbul, TUR

Corresponding author: Sevil Yusifli, yusiflisevil21@gmail.com

Review began 09/09/2026
Review ended 11/24/2026
Published 11/27/2026

© **Copyright** 2026
Gumus et al. This is an open access article distributed under the terms of the Creative Commons Attribution License CC-BY 4.0., which permits unrestricted use, distribution, and reproduction in any medium, provided the original author and source are credited.

DOI: 10.7759/cureus.120331

Abstract

We describe two patients with posterior circulation ischemic strokes demonstrating distinct patterns of midbrain involvement. The first patient presented with a partial Weber-like syndrome characterized by ipsilateral isolated ptosis and contralateral hemiparesis. The second patient presented with bilateral ptosis and anisocoria, with preserved extraocular movements confirmed during the neurological examination performed 24 hours after treatment. Intravenous thrombolysis followed by mechanical thrombectomy achieved complete recanalization in the second patient, and both patients demonstrated substantial clinical improvement during follow-up. These cases illustrate distinct oculomotor presentations associated with posterior circulation ischemic strokes and emphasize the value of correlating the clinical examination with the neuroanatomical distribution of infarction.

Categories: Neurology, Radiology, Ophthalmology
Keywords: anisocoria, basilar artery occlusion, bilateral ptosis, mechanical thrombectomy, midbrain infarction, neuroanatomical correlation, oculomotor fascicular lesion, oculomotor nuclear lesion, posterior circulation stroke, top of the basilar syndrome

Introduction

Basilar artery occlusion (BAO) is responsible for approximately 1% of total ischemic strokes, with an incidence of nearly four per 100,000 individuals each year [1]. Top-of-the-basilar syndrome (TBS) is a clinical syndrome resulting from ischemia of the distal basilar artery and rostral posterior circulation, which presents with a broad spectrum of findings, such as diplopia, ataxia, confusion, hallucinations, and sometimes seizures [2]. Weber syndrome can also occur due to an occlusion in the branches of the basilar artery; this leads to contralateral hemiplegia and ipsilateral third nerve palsy, typically presenting with pupillary dilation, ptosis, and abnormal accommodation reflexes [3,4]. In a partial oculomotor (3rd) nerve lesion, a normal pupillary light reflex can be seen. Despite the frequency of brainstem strokes, Weber syndrome presentation is considered rare [5]. In this short case series, we present two distinct posterior circulation strokes to illustrate the clinical correlations of the oculomotor nuclear complex: one manifesting as partial Weber syndrome and the other as isolated bilateral ptosis.

Case Presentation

Case 1

An 85-year-old right-handed female patient presented to the emergency room with altered mental status, gait ataxia, and dysarthria. She has a medical history of chronic hypertension, type 2 diabetes mellitus (T2DM), coronary artery disease (CAD), chronic kidney disease (CKD), and atrial fibrillation (AF), for which she was prescribed oral anticoagulation but had not been using it regularly. On neurological examination at admission, the patient was somnolent but able to follow simple commands. Speech was found to be moderately dysarthric. Pupils were isocoric with intact bilateral light reflexes. A complete right eye ptosis was observed, while there were normal extraocular movements in both eyes. A mild drooping of the left eyelid was also observed, which may have been related to the patient's sleepiness (Figure *1*).

How to cite this article
Gumus E, Weisy M, Yusifli S, et al. (November 27, 2026) Varied Oculomotor Presentations in Posterior Circulation Ischemic Stroke: A Case Series Highlighting Rare Fascicular and Nuclear Lesions. Cureus 18(11): e120331. DOI 10.7759/cureus.120331

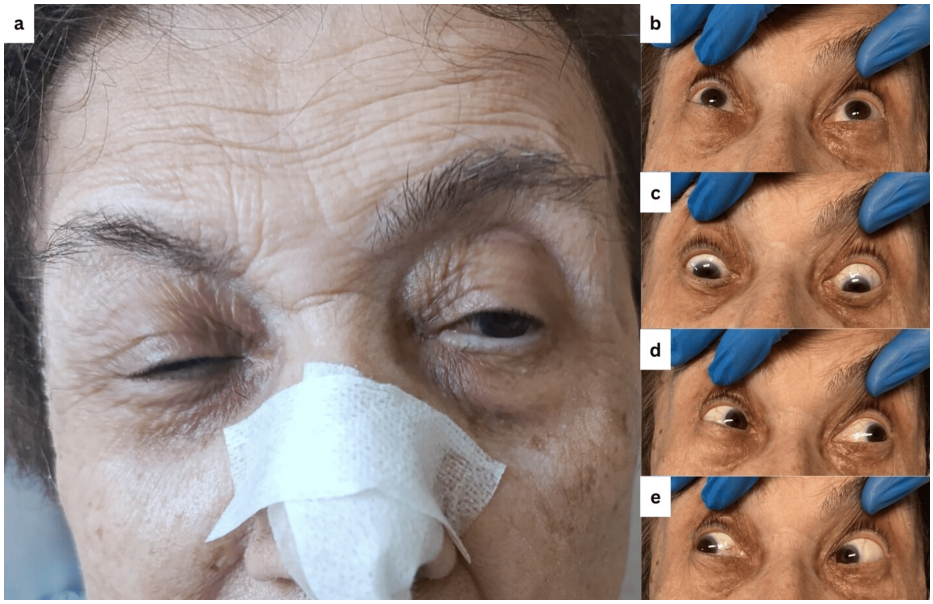

FIGURE 1: Right-sided ptosis with preserved extraocular movements

(a) Right-sided ptosis. (b-e) Intact extraocular movements, suggesting relative sparing of the oculomotor pathways responsible for extraocular muscle function.

The left nasolabial fold was flattened. Motor examination showed left-sided hemiparesis with 1/5 strength in both upper and lower extremities with a positive left Babinski sign. The initial National Institutes of Health Stroke Scale (NIHSS) score was 10. Diffusion-weighted magnetic resonance imaging (DWI) revealed multiple areas of restricted diffusion involving the right cerebellum, the right pontine tegmentum, the right cerebral peduncle and ventral mesencephalon, and the left occipital lobe. Computed tomography angiography (CTA) showed an occluded P1 segment of the right posterior cerebral artery (PCA) (Figure *2*). The left PCA P1 segment was patent on CTA. Given the acute DWI restriction in the left occipital lobe along with multifocal acute infarcts in other posterior circulation territories (right cerebral peduncle and ventral mesencephalon, pontine tegmentum, cerebellar hemisphere), the left occipital lesion was most likely caused by a distal embolic occlusion with spontaneous recanalization prior to CTA acquisition.

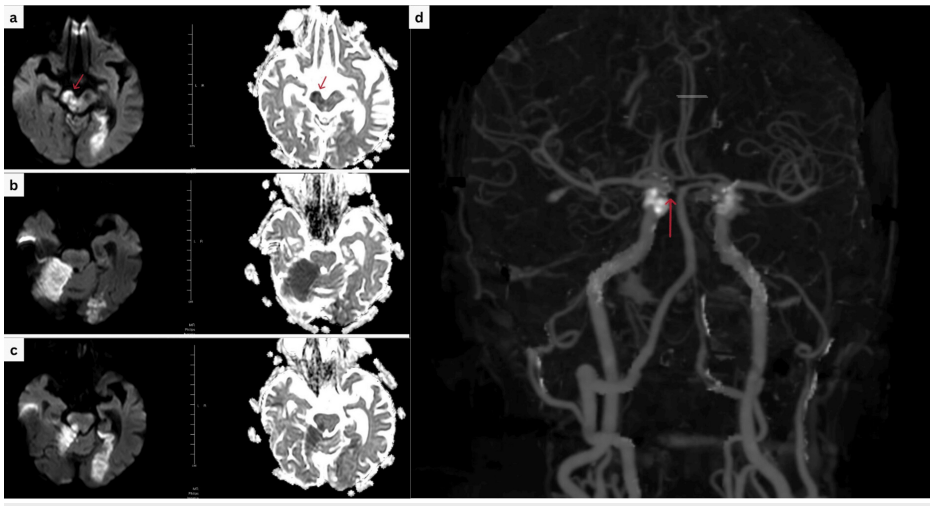

FIGURE 2: Radiological findings of Case 1

(a-c) Diffusion-weighted imaging (DWI) and corresponding apparent diffusion coefficient (ADC) maps showing acute infarcts in the right cerebral peduncle and ventral mesencephalon (red arrows), cerebellar hemisphere, right pontine tegmentum, and left occipital lobe consistent with involvement ofsuperior cerebellar artery (SCA), anterior inferior cerebellar artery (AICA), and posterior cerebral artery (PCA) territories. (d) CT angiography demonstrating occlusion of the right P1 segment of the posterior cerebral artery (red arrow); the left PCA was patent at the time of imaging.

Clinical presentation and radiological findings suggest partial Weber-like syndrome. The acute DWI restriction involving the right cerebral peduncle and ventral midbrain explains the contralateral left-sided hemiparesis, whereas the ipsilateral ptosis suggests selective involvement of the oculomotor fascicles. The ischemic stroke etiology is thought to be cardiogenic, considering the AT and inconsistent anticoagulant use history. At the one-month follow-up examination after intensive physical therapy and rehabilitation, her level of consciousness and cooperation had fully recovered. The right-sided ptosis had markedly improved (Figure *3*), and her left-sided hemiparesis had also shown significant clinical improvement, with both left upper and lower extremities showing 3/5 strength.



FIGURE 3: Follow-up ocular examination of Case 1

Follow-up photograph showing marked improvement of right-sided ptosis with preserved extraocular movements.

Case 2

A 66-year-old right-handed male presented to the emergency department with altered mental status and seizure-like activity presenting as a single, non-recurring episode of non-stereotyped jerking movements involving all four extremities. He had no known comorbidities and no history of regular medication use. AF was observed on his ECG. On neurological examination at admission, the patient was somnolent and had limited cooperation. Bilateral ptosis and anisocoria were observed. Both pupils were markedly dilated and non-reactive to light. Anisocoria was evident, with the left pupil measuring approximately 7 mm and the right pupil 5 mm. The patient had not undergone a recent ophthalmologic examination, and there was no history of medication use. Because the level of consciousness was somnolent, full cooperation could not be established with the patient for eye movements and extremity examination. However, his extremities were spontaneously mobile, and his bilateral flexor plantar responses were observed. On admission, the initial NIHSS score was 10. DWI revealed infarct areas in the midline mesencephalon and bilateral medial thalami. CTA demonstrated an occlusion in the distal segment of the basilar artery, consistent with TBS (Figure *4*).

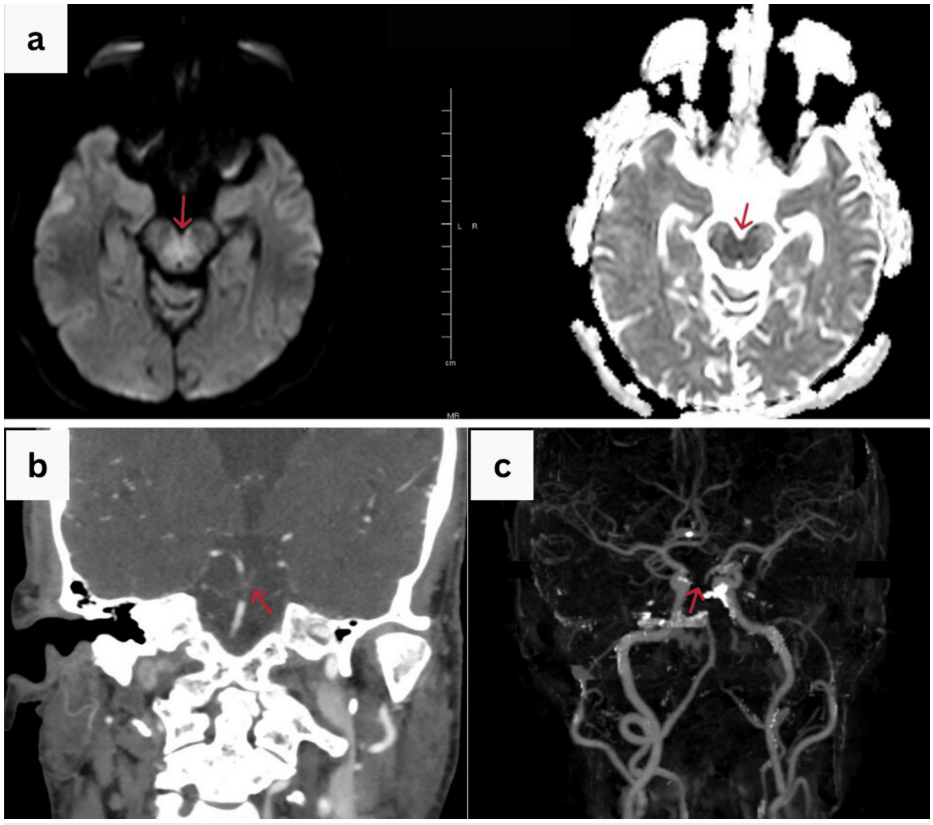

FIGURE 4: Radiological findings of basilar artery occlusion of Case 2

(a) Diffusion-weighted imaging (DWI) and corresponding ADC maps highlighting acute paramedian midbrain infarction. (b) CT angiography showing distal basilar artery cutoff. (c) 3D CT angiography demonstrating occlusion of the distal basilar artery (red arrow).

The patient's occlusion was successfully treated with IV thrombolytics and endovascular thrombectomy. At the neurological examination performed 24 hours after the treatment, the patient was conscious and cooperative, manifesting persistent dysarthric speech, bilateral ptosis, and pupil asymmetry featuring non-reactive light responses. Unlike the initial examination, a reliable assessment of ocular motility was possible at this time, demonstrating intact extraocular movements bilaterally. Muscle strength in all extremities was normal (5/5). On the follow-up imaging, complete recanalization of the basilar artery was seen, and no new infarct areas were detected. Anticoagulation therapy was started, and the patient was discharged with a follow-up appointment one month later.

Discussion

Understanding the anatomy of the oculomotor nerve (cranial nerve III) is essential for distinguishing clinical presentations and localizing lesions within the mesencephalon. The oculomotor nuclei complex consists of several specialized subnuclei (Figure *5* [6]).

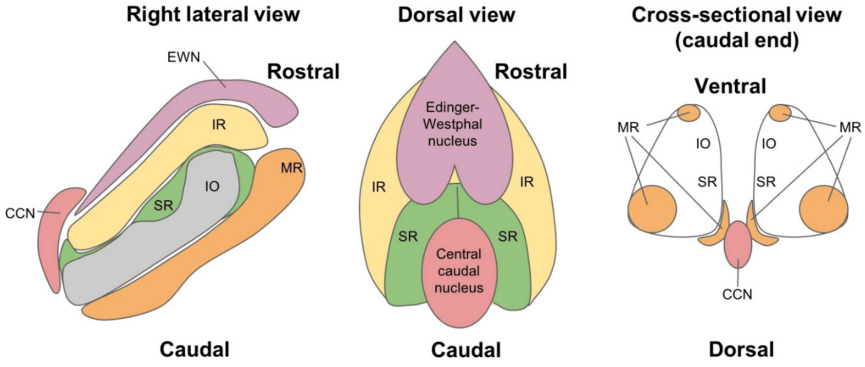

FIGURE 5: Diagram of the oculomotor nuclei complex

Right lateral, dorsal, and cross-sectional views of the oculomotor nuclei complex in the mesencephalon

Adapted with permission from Micieli [6]

One of these is the central caudal nucleus (CCN), which is located at the midline, on the level of the superior colliculus, ventral to the cerebral aqueduct. CCN is a single, unpaired, midline subnucleus. It contributes fibers to both oculomotor nerves and innervates both levator palpebrae superioris (LPS) muscles. Due to its anatomical position and bilateral innervation, CCN lesions cause bilateral ptosis. Bilateral ptosis is a rare finding of mesencephalon infarcts. In literature, it is discussed mainly in case reports, and definitive incidence rates are lacking in the literature [7]. Unilateral ptosis can be seen in isolated fascicular lesions of the CCN. There are reports in the literature of mesencephalic infarctions that support the fact that unilateral ptosis originates from a fascicular lesion rather than a nuclear lesion [8].

The bilateral ptosis observed in our second case is clinically consistent with involvement of the CCN or its associated oculomotor pathways, given the CCN's role in bilateral LPS innervation. Additionally, bilateral mydriasis and absent pupillary light reflexes suggest dysfunction of the parasympathetic oculomotor pathways, potentially involving the Edinger-Westphal nuclear complex (EWN) or its associated fibers. However, the preservation of eye movements suggests relative functional sparing of the oculomotor pathways responsible for extraocular muscle function. Despite the broader midbrain and bilateral thalamic involvement, the presence of bilateral ptosis and mydriasis with preserved extraocular movements suggests a selective pattern of oculomotor dysfunction rather than anatomically confirmed sparing of individual nuclei or fascicles. These findings highlight the importance of integrating clinical examination findings with neuroimaging to guide anatomical localization. Although the observed findings suggest involvement of distinct nuclear or fascicular components of the oculomotor system, selective injury to individual subnuclei or fascicles could not be directly confirmed by MRI.

As noted by Abid et al., ischemia in paramedian midbrain typically results from the occlusion of small perforating branches of the basilar artery [9]. The vascular distribution of the paramedian midbrain may provide a possible anatomical explanation for the preferential involvement of the CCN and EWN or their associated pathways, with relative preservation of ocular motility. However, selective involvement or sparing of individual subnuclei cannot be established from the available neuroimaging.

In our first case, the patient presented with a midbrain infarction associated with ipsilateral ptosis, preserved extraocular movements, and intact pupillary light reflexes. This clinical pattern suggests partial involvement of the oculomotor system rather than a complete third cranial nerve palsy. Given the unilateral predominance of ptosis, selective involvement of oculomotor fascicular fibers supplying the LPS (Figure *6* [10]) represents a plausible anatomical explanation. However, a partial lesion involving the oculomotor nuclear complex or adjacent pathways cannot be definitively excluded. Although the CCN provides bilateral innervation to the LPS, asymmetric involvement of its associated pathways may produce unilateral ptosis. Because conventional imaging cannot reliably distinguish individual oculomotor fascicles or subnuclei, the localization remains clinically inferred rather than radiographically confirmed.

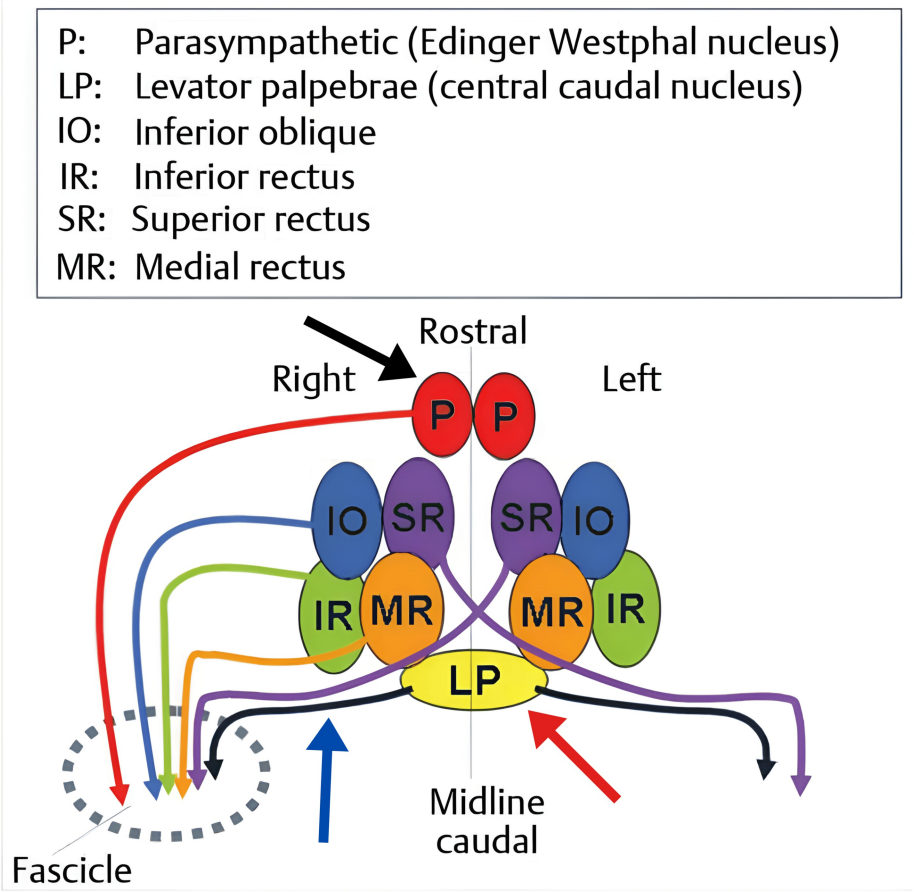

FIGURE 6: Fascicles of the oculomotor nuclei complex

Oculomotor nuclear complex showing the Edinger-Westphal (P) and central caudal (LP) nuclei in the midline. Involvement of these midline structures or their associated pathways may explain the clinical presentation of bilateral mydriasis and bilateral ptosis. The red arrow indicates the central caudal nucleus (CCN), the blue arrow indicates the CCN fascicle, and the black arrow indicates the Edinger-Westphal nucleus (EWN).

Adapted with permission from Biousse et al. [10].

While isolated ptosis due to mesencephalic infarction has been documented in the literature [11-14], our case is distinctive in presenting with a partial Weber syndrome characterized by ipsilateral right-sided ptosis and contralateral left-sided hemiparesis following a posterior circulation stroke. Neuroanatomically, classical Weber syndrome results from a lesion in the ventral midbrain involving both the fascicular third nerve fibers and the cerebral peduncle. In our patient, the infarction of the right cerebral peduncle interrupted the right corticospinal tract, resulting in left hemiparesis. Concurrently, the ipsilateral ptosis with preserved pupillary responses and extraocular movements suggests partial involvement of the oculomotor pathways. Potentially, this may involve fascicular fibers associated with LPS function while relatively sparing other oculomotor components.

Conclusions

This case series presents rare oculomotor manifestations in posterior circulation strokes, including ipsilateral ptosis with contralateral hemiparesis consistent with a partial Weber-like presentation and bilateral ptosis in TBS. These cases underscore the clinical importance of considering nuclear and fascicular involvement within the oculomotor complex when correlating clinical findings with neuroanatomical infarct topography. However, the proposed nuclear and fascicular localizations are based on clinical examination and neuroanatomical correlation rather than direct MRI visualization of individual oculomotor subnuclei or fascicles.

Additional Information

Author Contributions

All authors have reviewed the final version to be published and agreed to be accountable for all aspects of the

work.

Concept and design: Maimona Weisy, Hatice Yelda Yildiz, Enes Gumus, Sevil Yusifli, Yakup Krespi

Acquisition, analysis, or interpretation of data: Maimona Weisy, Enes Gumus, Sevil Yusifli, Yakup Krespi, Yavuz Bekmezci

Drafting of the manuscript: Maimona Weisy, Enes Gumus, Sevil Yusifli

Critical review of the manuscript for important intellectual content: Maimona Weisy, Hatice Yelda Yildiz, Enes Gumus, Sevil Yusifli, Yakup Krespi, Yavuz Bekmezci

Supervision: Yakup Krespi

Disclosures

Human subjects: Informed consent for treatment and open access publication was obtained or waived by all participants in this study. **Conflicts of interest:** In compliance with the ICMJE uniform disclosure form, all authors declare the following: **Payment/services info:** All authors have declared that no financial support was received from any organization for the submitted work. **Financial relationships:** All authors have declared that they have no financial relationships at present or within the previous three years with any organizations that might have an interest in the submitted work. **Other relationships:** All authors have declared that there are no other relationships or activities that could appear to have influenced the submitted work.

Acknowledgements

Enes Gumus and Maimona Weisy contributed equally to this work and should be considered co-first authors. They wrote the main manuscript and prepared Figures 1-6. We would like to acknowledge Dr. Yakup Krespi for his valuable guidance and editing throughout the manuscript writing process. We also thank Dr. Sevil Yusifli for explaining and managing the cases and for assisting in the preparation of Figures 1-4. We further thank Dr. Yavuz Bekmezci and Dr. Hatice Yelda Yildiz for their involvement in the acute management of the patients. All authors reviewed and edited the final manuscript.

References

1. Rai AT, Seldon AE, Boo S, et al.: A population-based incidence of acute large vessel occlusions and thrombectomy eligible patients indicates significant potential for growth of endovascular stroke therapy in the USA. J Neurointerv Surg. 2017, 9:722-6. 10.1136/neurintsurg-2016-012515
2. Caplan LR: "Top of the basilar" syndrome. Neurology. 1980, 30:72-9. 10.1212/wnl.30.1.72
3. Sheikh Hassan M, Osman Sidow N, Adam BA, Adani AA: Superior alternating hemiplegia (Weber's syndrome) - case report. Ann Med Surg (Lond). 2022, 77:103674. 10.1016/j.amsu.2022.103674
4. Lupescu IC, Anghel D, Dulamea AO: Weber syndrome - clinical-imaging correlations . Romanian J Neurol. 2022, 21:247-50. 10.37897/RJN.2022.3.9
5. Hamedani AG, Gold DR: Eyelid dysfunction in neurodegenerative, neurogenetic, and neurometabolic disease. Front Neurol. 2017, 8:329. 10.3389/fneur.2017.00329
6. Micieli J: Case-Based Neuro-Ophthalmology: Multiple Choice Questions and Explanations . Pressbooks, Montreal, Canada; 2019.
7. McDonnell M, Kelly N, Mullaney G, O'Malley T: 235 Eyes wide shut: a case of bilateral ptosis following stroke. Age Ageing. 2022, 51:afac218.205. 10.1093/ageing/afac218.205
8. Khalil M, Malik TG, Farooq K: Weber's syndrome with vertical gaze palsy . J Coll Physicians Surg Pak. 2009, 19:668-9.
9. Abid MB, Soon D, Rathakrishnan R, Zhao P, Tan C, Yeo LL: Pearls & Oy-sters: looking up the anatomy of looking up. Neurology. 2016, 86:e195-8. 10.1212/WNL.0000000000002629
10. Biousse V, Newman NJ: Diplopia. Neuro-Ophthalmology Illustrated. Biousse V, Newman NJ, Micieli JA (ed): Georg Thieme Verlag KG, Stuttgart, Germany; 2020. 10.1055/b-006-163723
11. Cai XF, Shi TM, Wu QB, Guo SY: Isolated ipsilateral ptosis associated with ventral midbrain infarction: a case report and literature review. J Int Med Res. 2024, 52:0. 10.1177/03000605241260366
12. Cheong CY, Aung TH, Pang WY, Ng CJ, Yap P: Isolated complete unilateral ptosis with intact extraocular eye movements. Age Ageing. 2019, 48:596-7. 10.1093/ageing/afz041
13. Kumawat BL, Panchal M, Sagar D: Isolated unilateral ptosis as a presenting feature of midbrain infarction . BMJ Case Rep. 2018, 2018:2017223750. 10.1136/bcr-2017-223750
14. Sugawara E, Nakamura H, Endo M, Tanaka F, Takahashi T: Isolated unilateral ptosis due to paramedian midbrain infarction. J Stroke Cerebrovasc Dis. 2015, 24:e121-3. 10.1016/j.jstrokecerebrovasdis.2015.01.027