Cureus
Part of SPRINGER NATURE

Open Access Case Report

Probable Late-Onset Neurogenic Heterotopic Ossification at the Fourth Metacarpophalangeal Joint in a Patient With Chronic C5 Tetraplegia: A Case Report

Review began 10/11/2026
Review ended 11/19/2026
Published 11/21/2026

© Copyright 2026
Nkhili et al. This is an open access article distributed under the terms of the Creative Commons Attribution License CC-BY 4.0., which permits unrestricted use, distribution, and reproduction in any medium, provided the original author and source are credited.

DOI: 10.7759/cureus.120036

Yassine Nkhili [1], Mohamed Maroc [1, 2], Iman Akhrif [3, 1], Sara Skalli [4], Samia Karkouri [5]

1. Physical Medicine and Rehabilitation, Ibn Sina University Hospital Center, Rabat, MAR 2. Physical Medicine and Rehabilitation, Mohammed VI University Hospital, Oujda, MAR 3. Physical Medicine and Rehabilitation, Faculty of Medicine and Pharmacy of Rabat, Mohammed V University, Rabat, MAR 4. Physical Medicine and Rehabilitation, Faculty of Medicine and Pharmacy of Rabat, Mohammed V University, Ibn Sina University Hospital, Rabat, MAR 5. Physical Medicine and Rehabilitation, Faculty of Medicine and Pharmacy of Rabat, Rabat, MAR

Corresponding author: Yassine Nkhili, yassinnkhili2021@gmail.com

Abstract

Neurogenic heterotopic ossification (NHO) is the formation of mature bone in soft tissues after a central nervous system injury. After spinal cord injury (SCI), it usually appears within the first months and around large joints; involvement of the hand is rare. We report a 20-year-old man with C5 Spinal Injury Association Impairment Scale (AIS) A tetraplegia, admitted for rehabilitation 32 months after a diving injury. His family had noticed a flexion deformity of the right fourth finger about six months earlier. Examination showed generalized upper-limb spasticity, with a Modified Ashworth Scale (MAS) score of 3 in the right finger flexors, a flexion posture of all long fingers without local inflammatory signs, and no grasp function. A radiograph of both hands showed a well-corticated, crescent-shaped para-articular density with an internal trabecular pattern on the ulnar aspect of the right fourth metacarpophalangeal (MCP) joint, with no counterpart on the left. Ultrasound showed a hyperechoic lesion of approximately 9 mm with posterior acoustic shadowing and no peri-lesional Doppler signal. C-reactive protein was mildly elevated (18.7 mg/L) in the presence of a stage 3 ischial pressure ulcer. The lesion was attributed to NHO. Management combined indomethacin with stretching, splinting, and positioning for spasticity. NHO may be considered in the differential diagnosis of para-articular hand densities in chronic SCI, but flexor spasticity should be assessed before a hand deformity is attributed to ossification.

Categories: Radiology, Physical Medicine & Rehabilitation, Neurosurgery
Keywords: hand, metacarpophalangeal joint, neurogenic heterotopic ossification, spinal cord injury, tetraplegia, ultrasound

Introduction

Neurogenic heterotopic ossification (NHO), also called para-osteo-arthropathy (POA), is the formation of true, mature bone within periarticular soft tissues after an injury to the central nervous system, particularly spinal cord injury (SCI) [1]. Unlike dystrophic calcification, which consists of amorphous deposits of calcium salts, NHO is organized bone with a cortex and trabeculae [1]. It usually begins within the first weeks to months after the injury [2], develops below the level of neurological function, and primarily affects the hips, knees, shoulders, and elbows. NHO can cause loss of joint motion, ankylosis, and functional impairment. Its diagnosis relies on clinical suspicion supported by imaging: bone scintigraphy and ultrasound can detect early lesions, plain radiographs become positive only after several weeks, and computed tomography (CT) confirms the location of the ossification [2,3].

Involvement of the hand is rare, with only a few cases reported [4,5]. Soft-tissue radiopaque densities have a broad differential diagnosis [6]. At the small joints of the hand, a para-articular density must be distinguished from sesamoid bones, calcific periarthritis, and old avulsion fractures. Moreover, an abnormal hand posture after a cervical neurological lesion is often neurogenic rather than articular [7], so that spasticity must be considered before a finger deformity is attributed to a joint lesion.

We describe a case of late-onset para-articular ossification at the fourth metacarpophalangeal (MCP) joint in a patient with chronic C5 tetraplegia, attributed to NHO, and discuss the imaging used to support the diagnosis, its differential diagnosis, and the respective contributions of ossification and spasticity to the finger deformity.

Case Presentation

A 20-year-old right-handed man sustained a C5 fracture-dislocation after diving into the sea. He underwent plate fixation and bone grafting the day after the injury and was discharged six days after surgery. He

received home-based physiotherapy for two months and, thereafter, a home program of passive mobilization. No specific trauma to the hands was documented.

About 26 months after the injury, his family noticed a persistent flexion deformity of the right fourth finger. He was admitted to our physical medicine and rehabilitation department 32 months after the injury for comprehensive rehabilitation; his main complaints were dependence in daily activities and neurogenic bladder and bowel dysfunction. The timeline of the case is summarized in Table *1*.

Time from SCI	Event
Day 0 (July 2023)	Diving into the sea; C5 fracture-dislocation with complete tetraplegia
Day 1	Plate fixation and bone grafting
Week 1	Discharge home with a physiotherapy prescription
Months 0-2	Home-based physiotherapy
Month 2 onward	Passive mobilization
About month 26	Persistent flexion deformity of the right fourth finger noticed by the family
Month 32, admission	Clinical assessment: C5 AIS A, finger-flexor spasticity (MAS 3 right, 2 left), stage 3 ischial pressure ulcer, no grasp function
Admission, week 1	Laboratory tests (day 5); radiographs of both hands and abdominal radiograph including both hips
Admission, day 11	Ultrasound with color Doppler of the right fourth MCP joint
During hospitalization	Indomethacin with gastroprotection; stretching, resting hand splints, positioning, pressure ulcer care

TABLE 1: Timeline of the case.

SCI: spinal cord injury; AIS: American Spinal Injury Association Impairment Scale; MAS: Modified Ashworth Scale; MCP: metacarpophalangeal.

On neurological examination, the injury was classified as C5 AIS A, with a C5 sensory level and absent perineal sensation, voluntary anal contraction, and deep anal pressure. Muscle strength (Medical Research Council grade) was 3/5 for the elbow flexors and shoulder abductors, 2/5 for the other shoulder muscles and the forearm pronators and supinators, and 1/5 for the elbow extensors, whereas the wrist flexors and extensors and all finger and thumb muscles were graded 0/5 bilaterally; active finger movement was therefore absent. Deep tendon reflexes were brisk, with exhaustible bilateral ankle clonus (<10 seconds) and a Penn spasm frequency score of 2 [8].

Spasticity was graded with the MAS [9]. In the upper limbs, the finger flexors were graded 3 on the right and 2 on the left; the thumb flexors and flexor carpi ulnaris 2 bilaterally; the pronators 1+; the biceps 1; and the flexor carpi radialis and triceps 0. In the lower limbs, the gastrocnemius was graded 2, the hip adductors and soleus 1+, and the hamstrings and tibialis posterior 1, bilaterally.

Passive range of motion (ROM) was symmetric in the shoulders and elbows. Wrist flexion was 90° bilaterally, and wrist extension was 40° on the right and 20° on the left. Hip flexion was 120° with a 10° extension deficit and abduction of 45°, the knees moved from 0° to 140°, and ankle dorsiflexion was 15° with the knee extended and 25° with the knee flexed, bilaterally. The moderate, symmetric limitations of the shoulders, elbows, and wrists were attributed to spasticity and disuse, and no asymmetric or marked loss of motion suggestive of NHO was found at the hips, knees, shoulders, or elbows.

Both hands showed a flexion posture of all long fingers, involving the interphalangeal joints and consistent with flexor spasticity, with a persistent flexion deformity of the right fourth finger (Figure *1*). Passive finger extension was restricted. There was no swelling, warmth, or erythema of the hand; pain could not be assessed because the hand was insensate. The response of the finger posture to wrist flexion (tenodesis effect) or to a diagnostic nerve block was not tested. No elementary grasp was possible with either hand; the patient was dependent for all activities of daily living, and his Functional Independence Measure score was 34/126 [10].

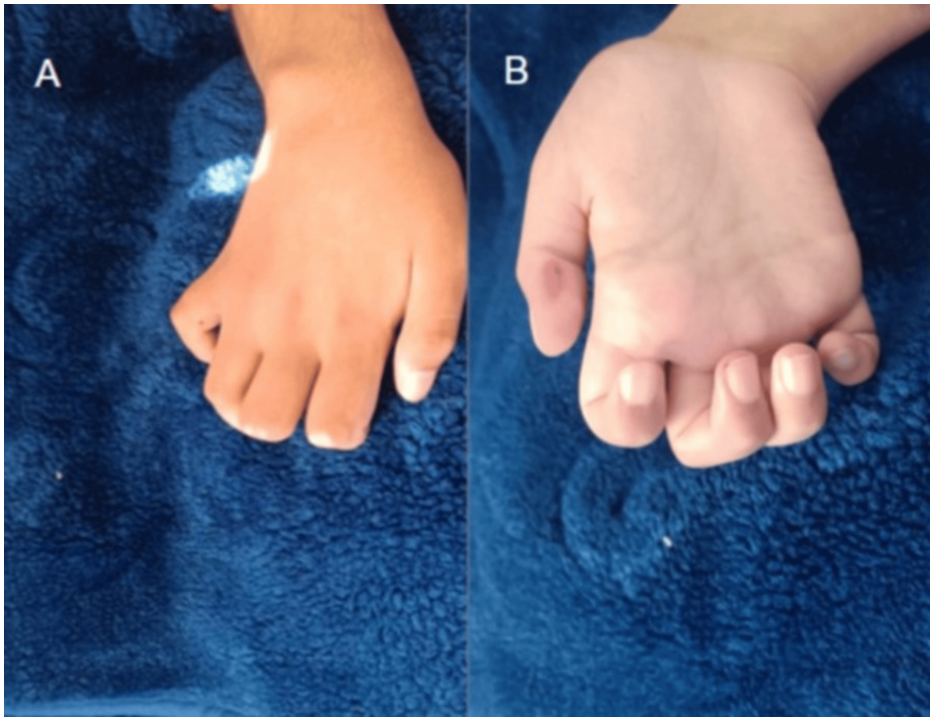

FIGURE 1: Clinical appearance of the right hand.

(A) Dorsal and (B) palmar views showing a flexion posture of all long fingers, involving the interphalangeal joints, with a persistent flexion deformity of the fourth digit. The finger flexors were spastic (Modified Ashworth Scale 3 on the right).

Skin examination revealed a stage 3 left ischial pressure ulcer with clean granulation tissue and no clinical signs of infection.

Laboratory tests obtained on day 5 of admission are reported in Table *2*. Blood count, sodium, potassium, chloride, glucose, urea, total protein, calcium, and liver enzymes were within reference ranges. Serum creatinine was below the reference range (0.56 mg/dL), consistent with reduced muscle mass in tetraplegia. C-reactive protein (CRP) was mildly elevated (18.7 mg/L), which we attributed mainly to the pressure ulcer, as CRP is non-specific; serum bicarbonate was slightly decreased. Alkaline phosphatase (ALP), erythrocyte sedimentation rate (ESR), phosphate, uric acid, 25-hydroxyvitamin D, and creatine kinase (CK) were not available.

Parameter	Result	Unit	Reference range
Hematology			
Red blood cells	5.10	×10⁶/µL	4.20-5.60
Hemoglobin	16.4	g/dL	12.1-16.6
Hematocrit	45.5	%	35.0-49.0
Mean corpuscular volume	89.2	fL	77.0-98.0
Mean corpuscular hemoglobin	32.2	pg	24.0-34.0
Mean corpuscular hemoglobin concentration	36.0	g/dL	31.0-37.0
Red cell distribution width	13.7	%	11.0-14.5
White blood cells	8.9	×10³/µL	4.0-11.0
Neutrophils	6.0 (67.4%)	×10³/µL	1.4-7.7
Lymphocytes	2.2 (25.1%)	×10³/µL	1.0-4.8
Monocytes	0.5 (5.3%)	×10³/µL	0.18-1.00
Eosinophils	0.1 (1.5%)	×10³/µL	0.02-0.63
Basophils	0.1 (0.7%)	×10³/µL	0.00-0.11
Platelets	369	×10³/µL	150-450
Biochemistry			
Sodium	136	mmol/L	136-145
Potassium	4.7	mmol/L	3.5-5.1
Chloride	103	mmol/L	98-107
Bicarbonate (alkaline reserve)	19 (Low)	mmol/L	22-31
Glucose	72	mg/dL	70-105
Urea	22	mg/dL	15-55
Creatinine	0.56 (Low)	mg/dL	0.72-1.25
Total protein	77.2	g/L	64.0-83.0
Calcium	9.21	mg/dL	8.40-10.20
Aspartate aminotransferase	19	U/L	5-34
Alanine aminotransferase	19	U/L	0-55
C-reactive protein	18.7 (High)	mg/L	<5.0

TABLE 2: Laboratory findings on day 5 of admission.

Alkaline phosphatase, erythrocyte sedimentation rate, phosphate, uric acid, 25-hydroxyvitamin D, and creatine kinase were not performed. Reference ranges are those of the hospital laboratory.

A dorsopalmar radiograph of both hands, obtained during the first week of admission, showed a crescent-shaped, well-corticated para-articular density with an internal trabecular pattern on the ulnar aspect of the right fourth MCP joint, adjacent to the metacarpal head and the base of the proximal phalanx (Figures *2A*, *2B*). No similar density was present at the left fourth MCP joint, and no cortical defect of the adjacent metacarpal head or phalangeal base was visible on this single projection. Because soft-tissue radiopaque densities have a broad differential diagnosis and require correlation with clinical findings and advanced imaging [6], we carefully considered the alternative diagnoses (see Discussion). An abdominal radiograph obtained during the same week for the assessment of constipation included both hip joints and showed no peri-articular ossification (Figure *2C*). No dedicated radiographs of the shoulders, elbows, or knees, and no

CT, bone scintigraphy, or earlier hand imaging were available.

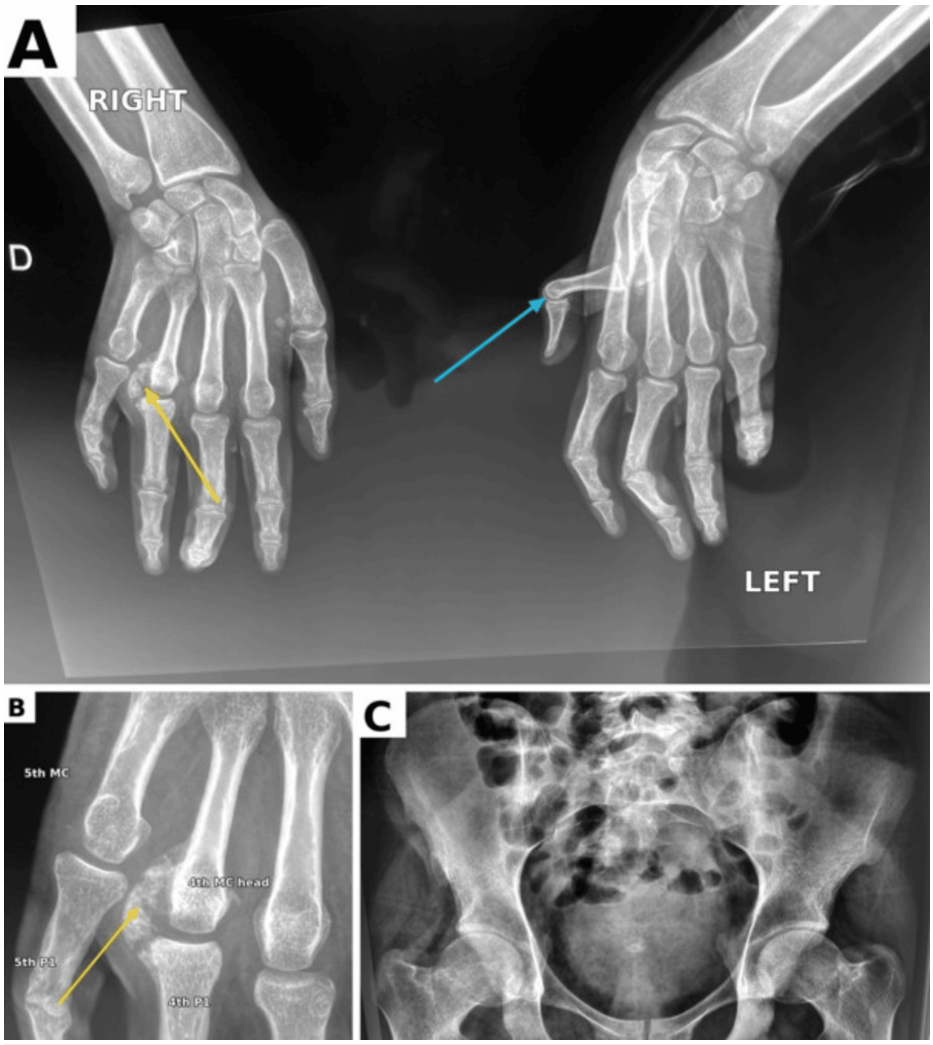

FIGURE 2: Plain radiographs.

(A) Dorsopalmar radiograph of both hands (original side marker "D" = right; grayscale conversion and contrast adjustment applied to the whole image). The yellow arrow indicates a para-articular density on the ulnar aspect of the right fourth metacarpophalangeal (MCP) joint; the blue arrow indicates the MCP dislocation of the left thumb. No similar density is seen at the left fourth MCP joint. (B) Magnified view of the right fourth MCP joint showing a crescent-shaped, well-corticated ossification with an internal trabecular pattern (arrow), adjacent to the ulnar aspect of the fourth metacarpal head and the base of the fourth proximal phalanx. (C) Abdominal radiograph obtained during the same week, including both hip joints, without visible peri-articular ossification. MC: metacarpal; P1: proximal phalanx.

Ultrasound of the right fourth MCP joint was performed on day 11 with a linear 6-18 MHz probe (Figure *3*). It showed a curvilinear hyperechoic lesion of approximately 9 mm, located about 5 mm beneath the skin in the para-articular soft tissue, separate from the cortices of the metacarpal head and proximal phalanx, with posterior acoustic shadowing. There was no joint effusion or synovial proliferation and no tenosynovitis. Color Doppler showed no flow signal in the peri-lesional soft tissue. These sonographic features do not reliably distinguish ossification from calcification; the absence of Doppler signal only indicated a non-hyperemic, probably inactive lesion.

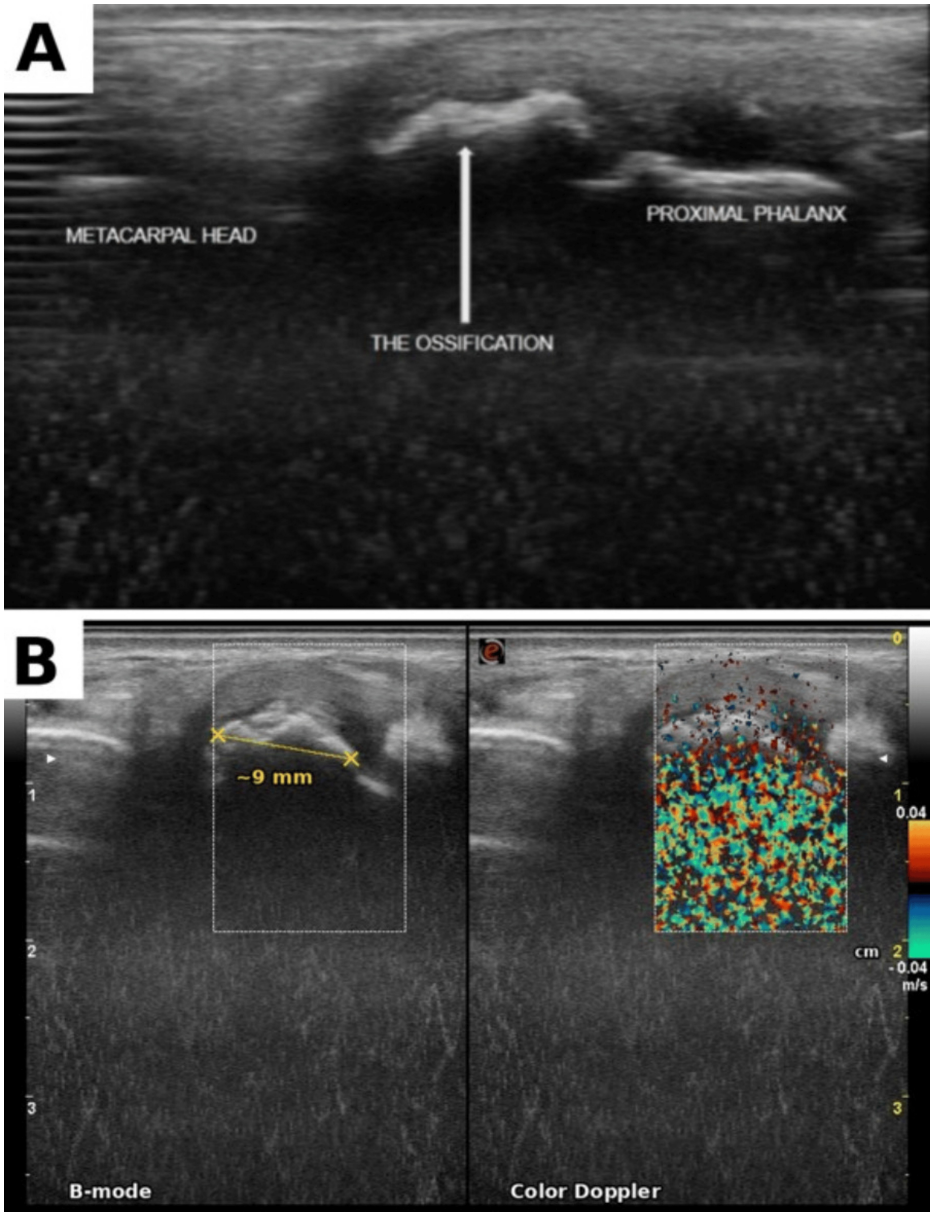

FIGURE 3: Ultrasound of the right fourth metacarpophalangeal joint (linear 6-18 MHz probe).

(A) Longitudinal view, probe placed over the ulnar aspect of the joint, showing a curvilinear hyperechoic structure with posterior acoustic shadowing (arrow) between the metacarpal head and the proximal phalanx, separate from both cortices. (B) Dual-screen B-mode (left) and color Doppler (right; 10 MHz, pulse repetition frequency 950 Hz, velocity scale ±0.04 m/s) images of the lesion, which measures approximately 9 mm (calipers, estimated from the on-screen depth scale in cm) and lies about 5 mm beneath the skin. No organized flow signal is seen in the peri-lesional soft tissue; the mosaic color pixels deep to the lesion lie within the acoustic shadow and correspond to background color noise rather than vascular flow. Ultrasound cannot distinguish ossification from calcification.

Considering the clinical context (complete cervical SCI with spasticity and a pressure ulcer), the radiographic appearance of a corticated lesion with a trabecular pattern, and the absence of a contralateral counterpart, the lesion was attributed to NHO.

The rehabilitation program focused on spasticity and joint preservation: daily stretching of spastic upper- and lower-limb muscles by physiotherapists and occupational therapists, resting splints positioning both wrists and hands, education of the patient and his father on functional positioning and gentle mobilization, a cushion between the thighs against adductor spasticity, tilt-table verticalization, and active-assisted strengthening of the shoulder muscles and elbow flexors. Oral antispasticity drugs and botulinum toxin injections were not part of the documented initial plan. The pressure ulcer was managed with offloading, daily dressings, and a high-protein diet. Indomethacin 75 mg/day was prescribed for three weeks, with omeprazole 20 mg/day for gastroprotection, after baseline renal function was checked, with the limited aim

of preventing further progression of the lesion. No follow-up assessment of joint motion, spasticity, hand function, or imaging was available for this report.

Discussion

NHO is a well-recognized complication of SCI [11]. It classically appears within the first weeks to months after injury [2], and spasticity, prolonged immobilization, and repetitive microtrauma are recognized contributing factors [1]. The timing in our patient was unusual: the deformity was noticed about 26 months after SCI, and the lesion was documented at 32 months. Because no earlier hand imaging was available, we cannot exclude that the ossification formed earlier and was discovered only when the deformity drew attention.

Para-articular ossification of the hand is rare [4]. Table *3* compares our patient with the previously reported case of NHO of the hands after SCI, described in a 47-year-old man with C5 quadriparesis [5]. Our case differs by the long interval between injury and detection (more than two years), by a single para-articular lesion centered on one MCP joint rather than ossifications parallel to the proximal phalanges of several digits in both hands, by flexor rather than extensor-predominant spasticity, and by the absence of local inflammatory signs.

Feature	Bendeddouche et al. 2011 [5]	Present case
Age/sex	47/M	20/M
Neurological condition	SCI, C5 quadriparesis	Traumatic SCI, C5 AIS A (diving)
Spasticity	Severe, extensor-predominant in the upper limbs	Flexor-predominant (finger flexors MAS 3 right, 2 left)
Interval injury-diagnosis	NR	About 26 months (deformity noticed); 32 months (diagnosis)
Clinical presentation	Pudgy appearance of the fingers at the proximal phalanges, both hands	Flexion posture of all long fingers; persistent flexion of the right fourth finger; no inflammatory signs
Location	Parallel to the proximal phalanges (right digits 3-4, left digits 2-3)	Single lesion, ulnar aspect of the right fourth MCP joint
Work-up	Radiograph; ALP elevated	Radiograph of both hands; ultrasound with Doppler; CRP 18.7 mg/L (pressure ulcer); ALP not available
Treatment/outcome	NR	Indomethacin; stretching, splinting/not available

TABLE 3: Comparison with the previously reported case of neurogenic heterotopic ossification of the hands after spinal cord injury.

NR: not reported in the abstract; SCI: spinal cord injury; AIS: American Spinal Injury Association Impairment Scale; MAS: Modified Ashworth Scale; MCP: metacarpophalangeal; ALP: alkaline phosphatase; CRP: C-reactive protein.

As noted above, soft-tissue radiopaque densities have a broad differential diagnosis [6]. At the MCP joints, the main alternatives to NHO are sesamoid bones, calcific periarthritis, old avulsion fractures, and dystrophic calcification. A sesamoid bone is uncommon at the ring-finger MCP joint and is typically small, round or oval, and located on the palmar aspect of the metacarpal head; the larger, crescent-shaped lesion of our patient, on the ulnar aspect of the joint and without a counterpart in the other hand, does not fit this pattern well, although a single projection cannot fully exclude it. Calcific periarthritis usually presents as an acute, painful, inflamed monoarticular process with amorphous, non-trabeculated deposits that regress within weeks; pain could not be assessed in our insensate patient, but the absence of local inflammatory signs, the chronic course, and the corticated, trabeculated appearance argue against it. No hand trauma was documented, and no cortical defect of the adjacent bones was visible, which makes an old avulsion fragment less likely. Dystrophic calcification, unlike NHO, lacks a cortex and trabeculae [1].

Ultrasound was useful to locate the lesion in the para-articular soft tissue and to look for effusion, synovitis, or tenosynovitis. Sonography can identify heterotopic bone formation early, through a characteristic zonal pattern, before radiographic changes appear [3]; in an established lesion, however, a hyperechoic focus with acoustic shadowing may be seen with both calcification and ossification, and a negative Doppler signal only indicates the absence of hyperemia, consistent with an inactive or mature lesion. The diagnosis of NHO

relies on a combination of clinical assessment and imaging studies [2]. Lesions seen on initial imaging may mimic other pathologies, and cross-sectional imaging is needed to confirm the diagnosis [12]; CT would have been the appropriate examination to confirm mature heterotopic bone in our patient. The diagnosis therefore remains presumptive.

A key question is whether the lesion explains the finger deformity. An abnormal hand posture after a cervical neurological lesion is often neurogenic; spasticity must therefore be assessed before a deformity is attributed to ossification [7]. In our patient, all long fingers showed a flexion posture involving the interphalangeal joints, and the right finger flexors had an MAS score of 3, whereas a small para-articular lesion at the MCP joint cannot explain flexion at the interphalangeal joints or in other digits. We therefore consider that the deformity mainly reflects finger-flexor spasticity and secondary soft-tissue shortening, with the ossification as a possible local mechanical contributor at the fourth MCP joint. Spasticity and ossification may also be linked: repetitive microtrauma, spasticity, prolonged immobilization, and vigorous physiotherapy may provoke interstitial hemorrhages and local osteogenic stimuli [1].

Management of NHO after SCI remains challenging, with limited high-quality evidence to guide therapy [11,13]. Potential interventions include nonsteroidal anti-inflammatory drugs (NSAIDs), bisphosphonates, radiotherapy, and surgical excision [11,14]. NSAIDs show their greatest efficacy in preventing NHO when given early after SCI [11], and indomethacin is the reference prophylactic agent after hip surgery [14]; warfarin has been suggested by a retrospective study [15], without robust evidence supporting its routine use. Bisphosphonates have the strongest supportive evidence once NHO has developed [11], but etidronate inhibits the mineralization of bone matrix rather than its production [15]. However, these drugs mainly limit further ossification and are not expected to remove mature bone, which is likely in our patient given the interval since injury, the corticated appearance, and the absence of Doppler signal. Indomethacin was prescribed empirically because the lesion's age and metabolic activity could not be determined without scintigraphy or earlier imaging, with the limited aim of preventing further progression. Surgical excision was not indicated given the lesion's small size and uncertain contribution to the deformity.

Conclusions

This case describes a small, well-corticated para-articular density at the ulnar aspect of the fourth MCP joint in a patient with chronic C5 AIS A tetraplegia, detected about two and a half years after injury and attributed to NHO. Confirmation of the diagnosis would require CT; the flexion deformity probably reflects mainly finger-flexor spasticity. NHO may be considered in the differential diagnosis of para-articular hand densities even late after SCI, but spasticity should be systematically assessed before a hand deformity is attributed to ossification.

Additional Information

Author Contributions

All authors have reviewed the final version to be published and agreed to be accountable for all aspects of the work.

Concept and design: Yassine Nkhili, Mohamed Maroc, Iman Akhrif

Acquisition, analysis, or interpretation of data: Yassine Nkhili, Mohamed Maroc, Sara Skalli, Samia Karkouri, Iman Akhrif

Drafting of the manuscript: Yassine Nkhili, Mohamed Maroc, Sara Skalli, Samia Karkouri, Iman Akhrif

Critical review of the manuscript for important intellectual content: Yassine Nkhili, Sara Skalli, Samia Karkouri, Iman Akhrif

Supervision: Sara Skalli, Samia Karkouri, Iman Akhrif

Disclosures

Human subjects: Informed consent for treatment and open access publication was obtained or waived by all participants in this study. **Conflicts of interest:** In compliance with the ICMJE uniform disclosure form, all authors declare the following: **Payment/services info:** All authors have declared that no financial support was received from any organization for the submitted work. **Financial relationships:** All authors have declared that they have no financial relationships at present or within the previous three years with any organizations that might have an interest in the submitted work. **Other relationships:** All authors have declared that there are no other relationships or activities that could appear to have influenced the submitted work.

References

1. Rossier AB, Bussat P, Infante F, et al.: Current facts of para-osteo-arthropathy (POA). Paraplegia. 1973, 11:38-78. 10.1038/sc.1973.5
2. Orzel JA, Rudd TG: Heterotopic bone formation: clinical, laboratory, and imaging correlation . J Nucl Med. 1985, 26:125-32.
3. Thomas EA, Cassar-Pullicino VN, McCall IW: The role of ultrasound in the early diagnosis and management of heterotopic bone formation. Clin Radiol. 1991, 43:190-6. 10.1016/S0009-9260(05)80478-7
4. Henderson HP, Reid DA: Para-articular ossification in the hand . Hand. 1981, 13:239-45. 10.1016/S0072-968X(81)80003-4
5. Bendeddouche I, Aissaoui N, Hajjaj-Hassouni N: Neurogenic heterotopic ossification of the hands in a patient with spinal cord injury: a case report. Spinal Cord. 2011, 49:1079-81. 10.1038/sc.2010.191
6. Chu EC, Chen AT, Chiang R, Trager R: Unusual worm-like radiopacities in the radiographs of patients with cervical spondylosis. J Med Life. 2022, 15:1449-54. 10.25122/jml-2022-0080
7. Chu EC, Ng L: Dystonic tremor as an atypical presentation of cervical radiculopathy . Cureus. 2024, 16:e51441. 10.7759/cureus.51441
8. Penn RD, Savoy SM, Corcos D, Latash M, Gottlieb G, Parke B, Kroin JS: Intrathecal baclofen for severe spinal spasticity. N Engl J Med. 1989, 320:1517-21. 10.1056/NEJM198906083202303
9. Bohannon RW, Smith MB: Interrater reliability of a modified Ashworth scale of muscle spasticity . Phys Ther. 1987, 67:206-7. 10.1093/ptj/67.2.206
10. Keith RA, Granger CV, Hamilton BB, Sherwin FS: The functional independence measure: a new tool for rehabilitation. Adv Clin Rehabil. 1987, 1:6-18.
11. Teasell RW, Mehta S, Aubut JL, Ashe MC, Sequeira K, Macaluso S, Tu L: A systematic review of the therapeutic interventions for heterotopic ossification after spinal cord injury. Spinal Cord. 2010, 48:512-21. 10.1038/sc.2009.175
12. Chu EC, Lin A, Huang KH, Cheung G, Lee WT: A severe disc herniation mimics spinal tumor . Cureus. 2023, 15:e36545. 10.7759/cureus.36545
13. Eng JJ, Teasell R, Miller WC, et al.: Spinal cord injury rehabilitation evidence: methods of the SCIRE systematic review. Top Spinal Cord Inj Rehabil. 2007, 13:1-10. 10.1310/sci1301-1
14. Macfarlane RJ, Ng BH, Gamie Z, El Masry MA, Velonis S, Schizas C, Tsiridis E: Pharmacological treatment of heterotopic ossification following hip and acetabular surgery. Expert Opin Pharmacother. 2008, 9:767-86. 10.1517/14656566.9.5.767
15. Buschbacher R, McKinley W, Buschbacher L, Devaney CW, Coplin B: Warfarin in prevention of heterotopic ossification. Am J Phys Med Rehabil. 1992, 71:86-91. 10.1097/00002060-199204000-00005