Cureus
Part of SPRINGER NATURE

Open Access Case Report

From Embolic Stroke of Undetermined Source (ESUS) to Patent Foramen Ovale-Associated Stroke: Diagnosis and Reclassification

David Martinez Juarez [1], Omar Gomez-Monterrosas [2], Marco Antonio Ortiz-Chávez [3]

1. Cardiovascular Imaging, Christus Muguerza, Puebla, MEX 2. Cardiology, Angeles Hospital Puebla, Puebla, MEX 3. Radiology, Hospital de Especialidades 5 de Mayo, Puebla, MEX

Corresponding author: David Martinez Juarez, www_david_@msn.com

Review began 08/11/2026
Review ended 11/06/2026
Published 11/10/2026

© **Copyright** 2026
Martinez Juarez et al. This is an open access article distributed under the terms of the Creative Commons Attribution License CC-BY 4.0., which permits unrestricted use, distribution, and reproduction in any medium, provided the original author and source are credited.

DOI: 10.7759/cureus.119417

Abstract

Embolic stroke of undetermined source (ESUS) represents a heterogeneous clinical entity encompassing multiple potential embolic mechanisms that may remain unidentified after a standard diagnostic evaluation. This heterogeneity poses significant challenges for therapeutic decision-making, particularly regarding anticoagulation strategies and targeted interventions. In recent years, structured phenotyping systems such as the Ischemic Stroke Phenotyping System 2025 (ISPS25), together with probabilistic tools including the Risk of Paradoxical Embolism (RoPE) score and the PFO-associated Stroke Causal Likelihood (PASCAL) classification, have been proposed to refine etiological attribution in patients with ESUS.

We report the case of a 40-year-old woman who presented with sudden-onset vertigo, nausea, and vomiting. Brain magnetic resonance imaging (MRI) demonstrated an ischemic stroke with an embolic pattern. Initial vascular, cardiac, and laboratory evaluations failed to identify a definitive cause, fulfilling the diagnostic criteria for ESUS. A comprehensive diagnostic approach, including transthoracic echocardiography (TTE) and cardiac magnetic resonance (CMR), revealed a patent foramen ovale (PFO) with high-risk anatomical features, specifically an atrial septal aneurysm (ASA), in the absence of other identifiable cardioembolic sources. Application of the ISPS25 enabled a structured etiological reassessment, while integration of the RoPE score and the PASCAL classification supported a high likelihood of a PFO-related ischemic stroke.

Structured etiological phenotyping, complemented by probabilistic tools such as ISPS25, RoPE, and PASCAL, may enhance diagnostic precision in ESUS and guide individualized therapeutic decision-making. In this case, such an approach provided a coherent diagnostic pathway that supported percutaneous PFO closure as a targeted strategy for secondary stroke prevention.

Categories: Neurology, Radiology, Cardiology
Keywords: atrial septal aneurysm, cryptogenic stroke, esus, isps25, patent foramen ovale, rope, stroke

Introduction

Embolic stroke of undetermined source (ESUS) is used to describe patients with non-lacunar cerebral infarction in whom no clear embolic source is identified after an appropriate diagnostic evaluation. Although this classification has been useful for standardizing the initial diagnostic approach, it also has important limitations, as it groups distinct embolic mechanisms under a single diagnostic label, which may hinder the selection of the most appropriate therapeutic strategy [1].

More recently, the approach proposed by the Ischemic Stroke Phenotyping System 2025 (ISPS25) represents an evolution of the ESUS concept by shifting from an exclusion-based diagnosis toward a probability-based etiological assessment. This framework acknowledges that, even when a single definitive cause cannot be established, the integration of clinical data and imaging findings allows estimation of the most likely embolic mechanism in each patient, with direct implications for therapeutic decision-making [2].

In this context, patent foramen ovale (PFO) is a common anatomical finding in the general population; however, not all PFOs confer the same embolic risk. High-risk anatomical features, including a large right-to-left shunt and atrial septal aneurysm (ASA), may increase the likelihood of paradoxical embolism [3]. The Risk of Paradoxical Embolism (RoPE) score estimates the likelihood that a PFO is causally related to ischemic stroke based on clinical and neuroimaging characteristics, whereas the PFO-Associated Stroke Causal Likelihood (PASCAL) classification combines the RoPE score with high-risk PFO anatomical features to refine causal attribution [4,5]. These complementary tools support the probability-based etiological assessment proposed by ISPS25, in contrast to the exclusion-based classification of ESUS.

We present the case of a young woman with an embolic stroke initially classified as ESUS, in whom a structured diagnostic approach enabled progression toward a probability-based etiological interpretation. This case illustrates how the application of contemporary stratification models may influence the

How to cite this article
Martinez Juarez D, Gomez-Monterrosas O, Ortiz-Chávez M (November 10, 2026) From Embolic Stroke of Undetermined Source (ESUS) to Patent Foramen Ovale-Associated Stroke: Diagnosis and Reclassification. Cureus 18(11): e119417. DOI 10.7759/cureus.119417

interpretation of PFO findings and subsequent therapeutic decision-making.

Case Presentation

A 40-year-old nulliparous woman presented to the emergency department with sudden-onset vertigo accompanied by nausea and vomiting. Symptoms began one day prior to admission and included three episodes of vomiting food contents with intolerance to oral intake. At presentation, vertigo remained the predominant symptom, associated with persistent nausea.

Her medical history was unremarkable except for an allergy to metoclopramide. She denied prior surgeries, venous thromboembolism, tobacco, drug, or alcohol use, and hormonal therapy. Vital signs were as follows: blood pressure of 110/70 mmHg, heart rate of 92 bpm, respiratory rate of 19 breaths/min, temperature of 36 °C, and oxygen saturation of 97% on room air. On physical examination, she showed signs of mild dehydration. Cardiovascular examination revealed a regular heart rhythm without murmurs. Neurological examination demonstrated a positive Romberg sign, without motor, sensory, or language deficits. The National Institutes of Health Stroke Scale (NIHSS) score at admission was 0. The patient presented approximately 24 hours after symptom onset and was therefore outside the conventional time window for intravenous thrombolysis; consequently, thrombolytic therapy was not administered.

Given the acute vestibular presentation, brain MRI was performed, revealing multiple subacute cortical-subcortical infarcts in the left posterior inferior cerebellar artery (PICA) territory. Magnetic resonance angiography (MRA) of the intracranial and supra-aortic vessels showed no significant arterial stenosis, occlusion, or evidence of dissection involving the supra-aortic arteries, vertebral arteries, or intracranial circulation (Figure *1*). Carotid and vertebral Doppler ultrasonography demonstrated no evidence of atherosclerotic plaques or hemodynamically significant stenosis (Figure *2*). Lower-extremity venous Doppler ultrasonography was not performed because the patient had no clinical signs or symptoms suggestive of deep vein thrombosis.

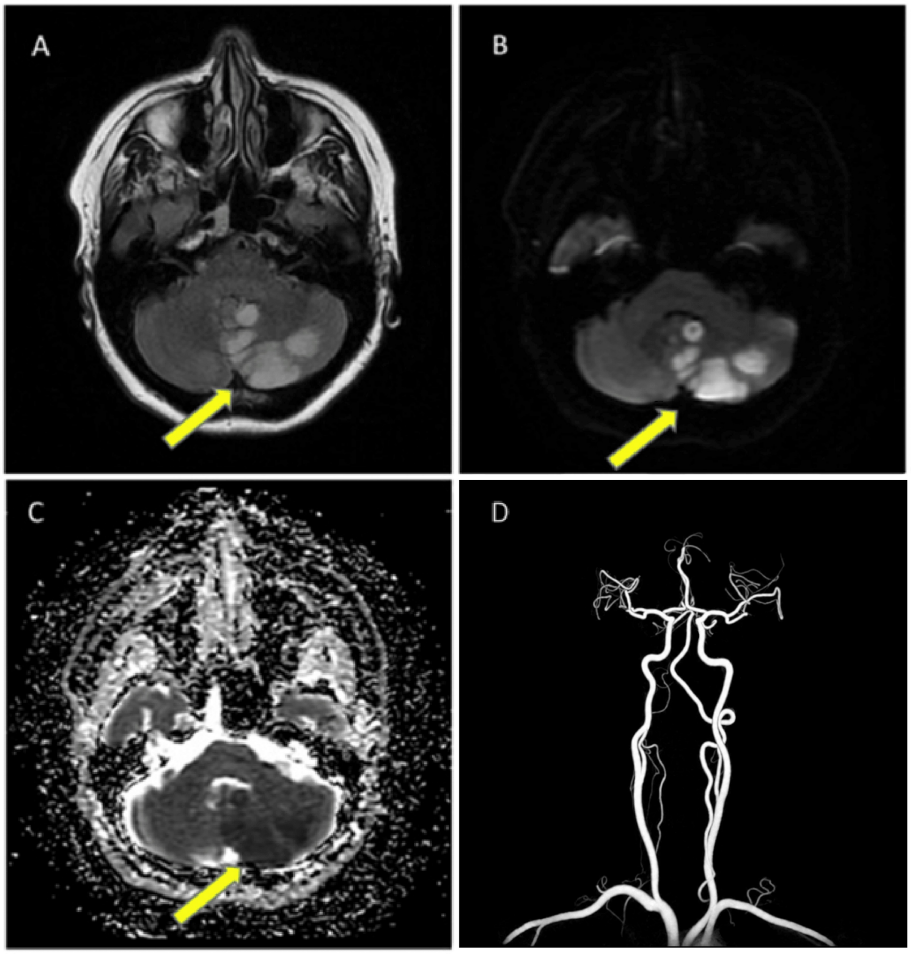

FIGURE 1: Brain MRA demonstrating acute ischemic infarction in the left cerebellar hemisphere.

(A) Axial fluid-attenuated inversion recovery (FLAIR) image demonstrating cortical-subcortical hyperintense lesions in the left cerebellar hemisphere (yellow arrow). (B) Diffusion-weighted imaging (DWI) showing corresponding hyperintensity, with (C) decreased signal intensity on the apparent diffusion coefficient (ADC) map, confirming restricted diffusion consistent with ischemic infarction. (D) Three-dimensional maximum intensity projection (3D MIP) reconstruction of magnetic resonance angiography (MRA) of the supra-aortic and intracranial arteries, without evidence of major arterial occlusion or hemodynamically significant stenosis. The non-lacunar cortical-subcortical distribution favors an embolic mechanism.

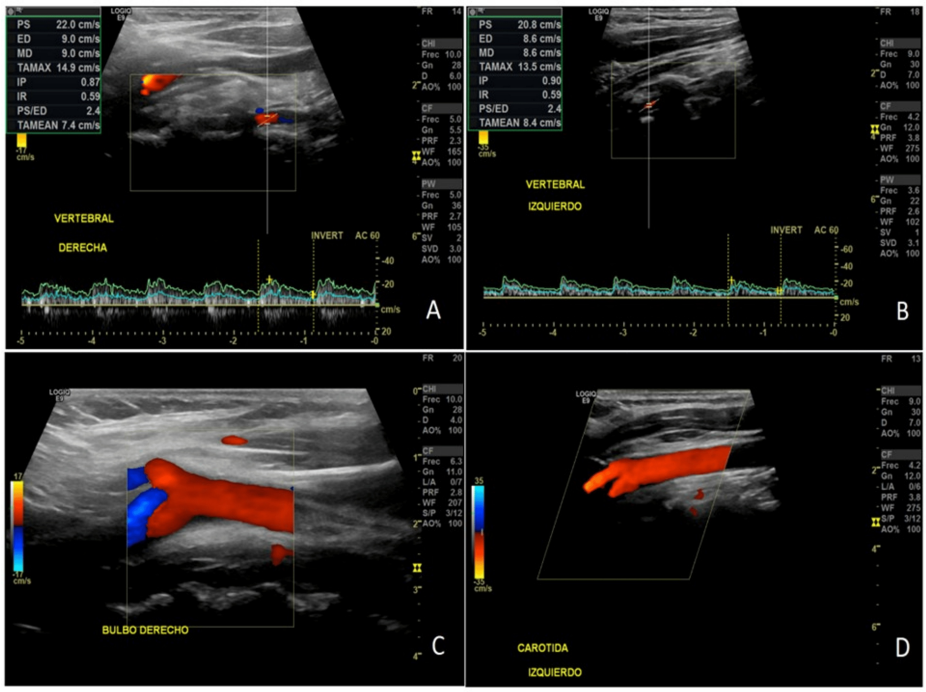

FIGURE 2: Carotid and vertebral Doppler ultrasound showing no evidence of atherosclerotic disease.

(A) and (B) Spectral Doppler interrogation of the bilateral vertebral arteries demonstrating normal antegrade flow without evidence of hemodynamically significant disease. (C) and (D) Color Doppler evaluation of the bilateral carotid arteries and bifurcations demonstrating no atherosclerotic plaque formation or significant luminal stenosis.

Initial laboratory evaluation (Table *1*) revealed an acute systemic inflammatory response. C-reactive protein was elevated (1.7 mg/dL; normal <1.0 mg/dL), erythrocyte sedimentation rate was mildly increased (22 mm/hour; normal 0-20 mm/hour in females), and leukocyte count was elevated (12.12 K/µL; normal 4.5-11 K/µL) with neutrophil predominance (80%; normal 40%-60%), normal fasting plasma glucose (98 mg/dL; normal 70-99 mg/dL), and preserved renal function with normal serum creatinine (0.75 mg/dL; normal 0.6-1.1 mg/dL). Additional findings included mild hyperuricemia (8.2 mg/dL; normal 2.6-6.0 mg/dL) and hypophosphatemia (1.6 mg/dL; normal 2.5-4.5 mg/dL).

Laboratory test	Admission	Discharge	Reference range/interpretation
Initial laboratory evaluation			
C-reactive protein	1.7 mg/dL	0.5 mg/dL	<1.0 mg/dL
Erythrocyte sedimentation rate	22 mm/hour	10 mm/hour	0-20 mm/hour
Hemoglobin	13.6 g/dL	13.1 g/dL	12.0-15.5 g/dL
Hematocrit	40.5%	39%	36.1%-44.3%
Platelet count	287 × 10^3/µL	254 × 10^3/µL	150-450 × 10^3/µL
Leukocyte count	12.12 × 10^3/µL	6.3 × 10^3/µL	4.5-11.0 × 10^3/µL
Neutrophils	80%	50%	40%-60%
Glucose	98 mg/dL	95 mg/dL	70-99 mg/dL
Creatinine	0.75 mg/dL	0.73 mg/dL	0.6-1.1 mg/dL
Uric acid	8.2 mg/dL	8.0 mg/dL	2.6-6.0 mg/dL
Phosphorus	1.6 mg/dL	3.6 mg/dL	2.5-4.5 mg/dL
Total cholesterol	228 mg/dL	-	<200 mg/dL

LDL cholesterol	112 mg/dL	-	<130 mg/dL
Total protein	7.2 g/dL	-	6.0-8.3 g/dL
Alkaline phosphatase	88 U/L	-	44-147 U/L
Lactate dehydrogenase	179 U/L	-	140-280 U/L
D-dimer	0.47 µg/mL	-	<0.5 µg/mL
Prothrombin time	12 s	-	11-13.5 s
Activated partial thromboplastin time	27 s	-	25-35 s
Fibrinogen	342 mg/dL	-	200-400 mg/dL
HIV screening	Negative	-	Negative
VDRL	Non-reactive	-	Non-reactive
Hemoglobin A1c	4.5%	-	<5.7%
Drug screening			
Cocaine metabolites	Negative	-	Negative
Methamphetamines	Negative	-	Negative
Cannabinoids (THC)	Negative	-	Negative
Antiphospholipid syndrome evaluation (second-pass testing)			
Anticardiolipin IgG antibodies	8 GPL U/mL	-	Negative (<20 GPL U/mL)
Anticardiolipin IgM antibodies	6 MPL U/mL	-	Negative (<20 MPL U/mL)
Anti-β2-glycoprotein I IgG antibodies	7 U/mL	-	Negative (<20 U/mL)
Anti-β2-glycoprotein I IgM antibodies	7 U/mL	-	Negative (<20 U/mL)
Lupus anticoagulant	Negative	-	Negative
Additional autoimmune testing			
Antinuclear antibodies (ANA)	Negative	-	Negative
Anti-double-stranded DNA antibodies (anti-dsDNA)	20 IU/mL	-	Negative (<30 IU/mL)
Anti-Smith antibodies (anti-Sm)	30 AAU/mL	-	Negative (<150 AAU/mL)
Anti-ribonucleoprotein antibodies (anti-RNP)	47 AAU/mL	-	Negative (<150 AAU/mL)
Anti-SSA/Ro antibodies	20 AAU/mL	-	Negative (<150 AAU/mL)
Anti-SSB/La antibodies	34 AAU/mL	-	Negative (<150 AAU/mL)
Myeloperoxidase ANCA (MPO-ANCA)	3 UR/mL	-	Negative (<20 UR/mL)
Proteinase 3 ANCA (PR3-ANCA)	<2 UR/mL	-	Negative (<20 UR/mL)
Complement C3	124 mg/dL	-	83-193 mg/dL
Complement C4	32 mg/dL	-	18-51 mg/dL

TABLE 1: Laboratory findings at admission, discharge, and extended etiologic work-up.

Laboratory evaluation showed transient inflammatory abnormalities at admission, with normalization of C-reactive protein, erythrocyte sedimentation rate, leukocyte count, and neutrophil percentage at discharge. Specific testing for antiphospholipid syndrome and additional autoimmune serologic evaluation yielded negative results.

AAU, arbitrary antibody units; ANA, antinuclear antibodies; ANCA, antineutrophil cytoplasmic antibodies; HIV, human immunodeficiency virus; LDL, low-density lipoprotein; MPO, myeloperoxidase; PR3, proteinase 3; VDRL, Venereal Disease Research Laboratory

Coagulation parameters were within normal ranges (Table *1*), including prothrombin time (12 seconds; normal 11-13.5 seconds), activated partial thromboplastin time (27 seconds; normal 25-35 seconds),

fibrinogen (342 mg/dL; normal 200-400 mg/dL), and D-dimer (0.47 μg/mL; normal <0.5 μg/mL). The lipid profile showed mild hypercholesterolemia, with total cholesterol of 228 mg/dL (normal <200 mg/dL). Glycated hemoglobin (HbA1c) was within the normal range (4.5%; normal <5.7%). Infectious disease screening was negative for human immunodeficiency virus (HIV), and the Venereal Disease Research Laboratory (VDRL) test was non-reactive. Toxicological screening was negative for cocaine metabolites, methamphetamines, and cannabinoids (THC).

The baseline electrocardiogram demonstrated normal sinus rhythm, normal PR (126 ms), QRS (76 ms), and QTc (410 ms) intervals, as well as minor nonspecific repolarization changes (Figure *3*). The patient underwent continuous inpatient cardiac telemetry for at least 24 hours, with no atrial fibrillation detected. Subsequent 24-hour Holter monitoring also showed sinus rhythm without episodes of atrial fibrillation.

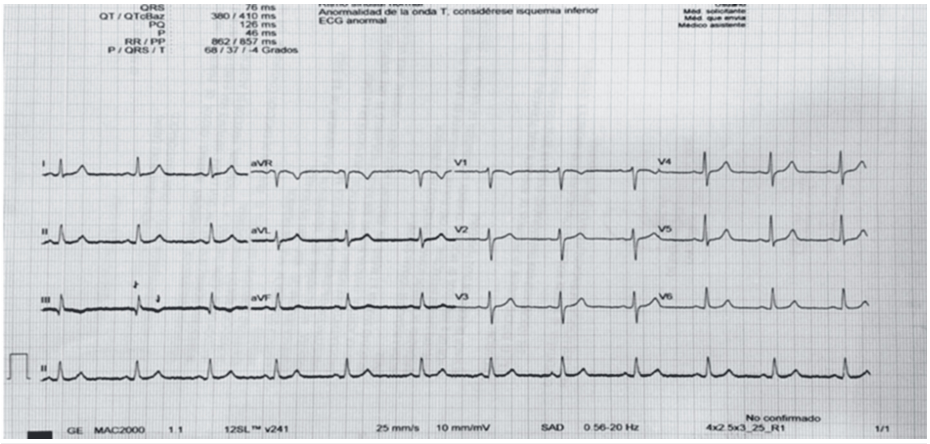

FIGURE 3: Admission electrocardiogram.

Admission electrocardiogram demonstrated normal sinus rhythm with normal PR, QRS, and QTc intervals; minor nonspecific inferior T-wave changes, without evidence of atrial fibrillation or other clinically significant arrhythmias.

Based on these findings, the event was initially classified as ESUS, and a structured etiological evaluation was initiated.

Following the initial diagnostic evaluation, the etiological workup was expanded to include an antiphospholipid syndrome (APS) panel comprising anticardiolipin antibodies, lupus anticoagulant, and anti-β2-glycoprotein I antibodies, as well as an autoimmune laboratory panel, including antinuclear antibodies (ANA), anti-SSA/Ro, anti-SSB/La, and antineutrophil cytoplasmic antibodies (ANCA). All tests yielded negative results (Table *1*).

Considering the patient's age and embolic infarct pattern, additional cardiac evaluation was performed. Transthoracic echocardiography (TTE) demonstrated a PFO associated with an ASA on two-dimensional four-chamber imaging, with color Doppler demonstrating flow across the interatrial septum. Cardiac magnetic resonance (CMR) subsequently provided complementary anatomical and dynamic characterization of the interatrial septum using four-chamber cine imaging throughout the cardiac cycle, demonstrating an approximately 2-mm PFO and confirming the associated ASA, which measured 17 mm in length and showed a maximal excursion of 10 mm toward the right atrium (Figure *4*). The maximal septal excursion met the established morphological criterion for ASA (≥10 mm from the plane of the interatrial septum), constituting the documented high-risk PFO-associated anatomical feature in this patient. Because an agitated-saline contrast study with Valsalva maneuver was not performed, the magnitude of the functional right-to-left shunt could not be quantified; therefore, a large shunt was not considered a documented high-risk feature. Accordingly, the ASA, rather than shunt magnitude, was the high-risk anatomical feature integrated with the RoPE score for PASCAL classification (Table *2*).

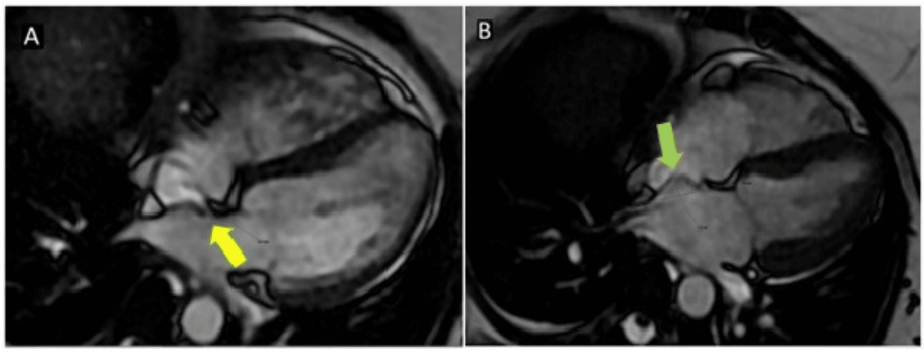

FIGURE 4: Cardiac magnetic resonance (CMR) demonstrating high-risk interatrial septal anatomy.

The left ventricle showed normal morphology and no wall motion abnormalities, with an ejection fraction (EF) of 60%. CMR revealed anatomical findings compatible with a patent foramen ovale (PFO) associated with an atrial septal aneurysm (ASA).

(A) Four-chamber cine sequence showing a PFO (yellow arrow). (B) Four-chamber systolic cine sequence demonstrating an ASA, indicated by the green arrow.

RoPE score/Appearance of large shunt (LS)/Atrial septal aneurysm (ASA)	Related
RoPE <7 no LS/ASA	Unlikely
RoPE <7 + LS/ASA present	Possible
RoPE ≥7 no LS/ASA	Possible
RoPE ≥7 + LS/ASA present	Probable

TABLE 2: Application of the PASCAL classification system in a patient with ESUS and PFO.

The patent foramen ovale (PFO)-Associated Stroke Causal Likelihood (PASCAL) classification system [5] was applied using the Risk of Paradoxical Embolism (RoPE) score and high risk anatomical features detected by echocardiography and corroborated by cardiac magnetic resonance imaging. The patient was categorized as “Probable” for PFO-associated stroke due to a high RoPE score and the presence of high-risk interatrial septal features. Patient result: RoPE score = 8; ASA present.

Based on the integration of clinical and imaging findings, the stroke was reclassified under ISPS25 as a probable cardioembolic stroke associated with PFO. The patient had a RoPE score of 8 and an ASA as the documented high-risk PFO-associated anatomical feature. The combination of a high RoPE score (≥7) and high-risk PFO anatomy supported classification as a probable PFO-associated stroke according to the PASCAL classification system.

Initial medical management included atorvastatin 40 mg daily, aspirin with a 300-mg loading dose followed by 100 mg daily, and clopidogrel with a 300-mg loading dose followed by 75 mg daily. Initial dual antiplatelet therapy was administered as an early secondary stroke prevention strategy during the etiological workup.

Following etiological assessment and classification as a probable PFO-associated stroke, percutaneous PFO closure was successfully performed using a 25-mm Amplatzer PFO Occluder (Abbott, Abbott Park, IL). Appropriate device positioning was confirmed by echocardiography, with no residual interatrial shunt detected by color Doppler immediately after device implantation and no immediate procedure-related complications. After PFO closure, dual antiplatelet therapy with aspirin 100 mg daily and clopidogrel 75 mg daily was continued for one month, followed by aspirin 100 mg daily as single antiplatelet therapy throughout the 12-month follow-up. During this period, the patient remained clinically stable, with no recurrent ischemic stroke, transient ischemic attack, or other systemic embolic events.

The complete diagnostic workup is summarized in Figure *5*.

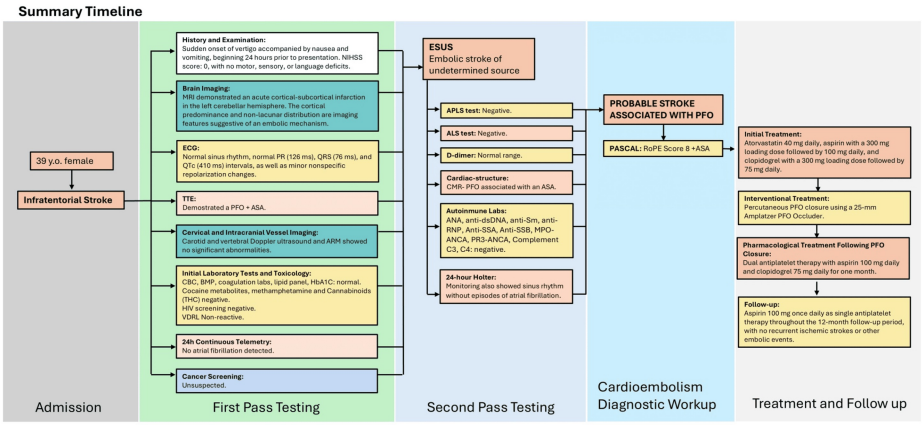

FIGURE 5: Diagnostic workup, etiological assessment, treatment, and follow-up of a patient with embolic stroke of undetermined source.

Flowchart summarizing the clinical presentation, first- and second-pass diagnostic investigations, evaluation of potential embolic sources, assessment of PFO-associated stroke using the RoPE score and PASCAL classification system, percutaneous PFO closure, antiplatelet therapy, and 12-month clinical follow-up. Image created by authors using ibisPaint X (ibis inc., Tokyo, Japan).

ESUS, embolic stroke of undetermined source; PFO, patent foramen ovale; ASA, atrial septal aneurysm; RoPE, Risk of Paradoxical Embolism; PASCAL, PFO-Associated Stroke Causal Likelihood; MRI, magnetic resonance imaging; MRA, magnetic resonance angiography; TTE, transthoracic echocardiography; CMR, cardiovascular magnetic resonance

Discussion

ESUS represents a heterogeneous clinical entity encompassing multiple potential embolic mechanisms that may remain unidentified after a standard diagnostic evaluation. Although the ESUS concept was initially proposed to guide secondary prevention strategies, subsequent randomized clinical trials failed to demonstrate a benefit of routine anticoagulation over antiplatelet therapy, highlighting the limitations of considering ESUS as a uniform pathological category [1,6]. These findings underscored the need to refine etiological classification beyond the ESUS label to identify specific mechanisms that may allow for targeted interventions [7].

In this context, the recently proposed ISPS25 provides a structured framework for reclassifying ischemic stroke based on the probability of underlying mechanisms following a comprehensive diagnostic evaluation [2]. Unlike previous systems, ISPS25 emphasizes a graded causal attribution defined as unlikely, possible, or probable, allowing clinicians to move beyond a residual ESUS diagnosis when sufficient clinical or anatomical evidence is present [5].

In our patient, the etiological workup focused on identifying potential alternative mechanisms of ischemic stroke and assessing the clinical relevance of the diagnostic findings. The initial laboratory evaluation revealed mild elevations in inflammatory markers, including C-reactive protein and erythrocyte sedimentation rate. These abnormalities resolved during hospitalization. Additional autoimmune testing, including ANA, anti-dsDNA, anti-Sm, anti-RNP, anti-SSA/Ro, anti-SSB/La, MPO-ANCA, and PR3-ANCA, was negative, with normal complement C3 and C4 levels. HIV testing was negative, and VDRL was non-reactive. Within the etiological evaluation, these transient inflammatory abnormalities were considered compatible with an acute inflammatory response associated with the ischemic event.

A limitation of this case is that lower-extremity venous Doppler ultrasonography was not performed because the patient had no clinical signs or symptoms suggestive of deep vein thrombosis. Consequently, venous thrombosis could not be excluded. Furthermore, although the extended etiological workup included negative testing for antiphospholipid syndrome and other autoimmune conditions, a comprehensive inherited thrombophilia panel was not performed. Such testing is not routinely indicated in all patients with ESUS and should be guided by individual clinical characteristics and thrombotic history [2].

In our patient, the RoPE score provided additional evidence supporting a causal role of the PFO (Table *3*). A RoPE score of 8 is associated with a high probability that the ischemic stroke is attributable to the PFO [4]. Importantly, the RoPE score does not constitute an indication for PFO closure by itself, but rather should be interpreted in conjunction with defect anatomy and the exclusion of alternative embolic mechanisms [5]. In this case, the convergence of a high RoPE score, high-risk anatomical features, an embolic infarct pattern in the posterior circulation, and the absence of competing mechanisms strengthened the rationale for

definitive intervention.

Variable	Patient status	Score
Hypertension	Absent	1 point
Diabetes	Absent	1 point
Prior stroke or transient ischemic attack	Absent	1 point
Smoking	Non-smoker	1 point
Cortical infarct	Cortical cerebellar infarct	1 point
40-49 years old	Age 40 years	3 points
Total Risk of Paradoxical Embolism (RoPE) score		8 points

TABLE 3: RoPE score calculation in the present case.

The RoPE score was used to estimate the likelihood that the patient's ischemic stroke was attributable to the PFO rather than an incidental finding. The patient obtained a total score of 8 points, corresponding to a high probability of PFO-associated stroke and supporting a causal relationship between the PFO and the embolic event [5].

PFO, patent foramen ovale

Although TTE initially identified findings suggestive of a PFO and ASA, cardiac magnetic resonance imaging (CMR) provided complementary anatomical information regarding the interatrial septum and its high-risk structural features. However, CMR does not replace functional assessment of right-to-left shunting using transesophageal echocardiography with agitated saline contrast or contrast-enhanced transcranial Doppler [5], neither of which was performed in the present case. Consequently, although multimodality imaging allowed further anatomical characterization of the interatrial septal abnormalities, the magnitude of the right-to-left shunt could not be determined. This limitation should be considered when interpreting the probable causal association between the PFO and the ischemic stroke [2].

PFO is a common anatomical finding in the general population; however, not all PFO confer the same embolic risk. Previous studies have demonstrated that specific anatomical characteristics such as a large right-to-left shunt, the presence of an ASA, and marked septal excursion are associated with an increased RoPE score [3]. The PASCAL classification (Table *2*) integrates these high-risk anatomical features with the clinical context to estimate the probability of a causal relationship between PFO and ischemic stroke [5]. In this patient, CMR demonstrated high-risk interatrial septal anatomical features compatible with PFO-associated stroke.

In this context, brain MRI plays a fundamental role not only in confirming the diagnosis of ischemic stroke but also in characterizing the anatomical distribution of infarcts, providing relevant information for etiological assessment [2,7]. The identification of cortical infarcts, lesions involving multiple vascular territories, or infarcts of different ages may suggest an embolic mechanism, although these patterns are not specific to a cardioembolic source or paradoxical embolism. Small, deep lacunar infarcts are more commonly associated with small vessel disease [8-10].

In the present case, the infarct pattern identified on MRI, together with the absence of significant stenosis in the arteries supplying the affected territory and the lack of an alternative established cause after diagnostic evaluation, was consistent with an embolic mechanism. These findings initially supported the classification of the event as ESUS. Subsequently, the identification of a PFO associated with an ASA, combined with assessment using the RoPE score and the PASCAL classification system, supported a probable causal association between the PFO and the ischemic stroke (Figure *6*).

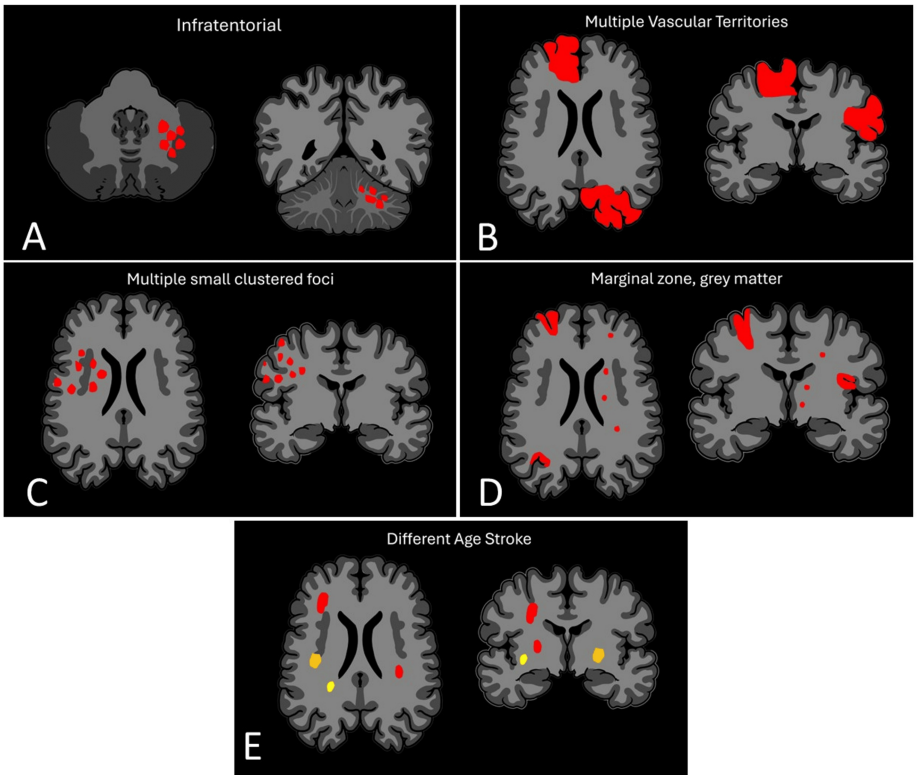

FIGURE 6: Neuroimaging patterns and topographic distribution of ischemic infarcts suggestive of different embolic mechanisms.

Schematic illustration summarizing neuroimaging patterns that may be observed in patients with embolic stroke of undetermined source (ESUS). (A) Infratentorial infarcts, representing the distribution observed in the present case; this pattern is not specific to patent foramen ovale (PFO)-associated stroke. (B) Infarcts involving multiple vascular territories, suggesting a possible embolic mechanism, including cardioembolism. (C) Multiple infarcts clustered within a single vascular territory, potentially suggesting an artery-to-artery embolic mechanism. (D) Multiple cortical and subcortical lesions involving watershed regions, which may reflect embolic or hemodynamic mechanisms. (E) Infarcts of different ages, suggesting recurrent ischemic events and potentially an embolic mechanism [2,7,8].

Image created by authors using ibisPaint X (ibis inc., Tokyo, Japan).

Percutaneous PFO closure has been shown to reduce the recurrence of ischemic cerebrovascular events in randomized clinical trials conducted in carefully selected patients with embolic stroke and high-risk anatomical features [11-13]. The decision to perform PFO closure in this patient was supported by contemporary evidence favoring intervention in individuals with ischemic stroke probably related to PFO, as defined by anatomical criteria and clinical risk stratification [4,5,14], although definitive causality cannot be established in the context of a single case.

This case illustrates several clinically relevant lessons. First, ESUS should be regarded as a provisional diagnosis rather than a final etiological category. Second, structured phenotyping systems such as ISPS25 allow meaningful reclassification when applied systematically [2]. Third, integration of anatomical and clinical stratification tools, such as PASCAL and RoPE, enables a more precise assessment of paradoxical embolism risk [4,5]. Fourth, infarct characterization by brain MRI provides valuable insights into the likely stroke mechanism [8].

Conclusions

This case illustrates the diagnostic complexity of ESUS and highlights the importance of multimodality neuroimaging and cardiovascular imaging in identifying potential embolic substrates. The presence of a PFO associated with high-risk anatomical features, including an ASA, together with the neuroimaging distribution pattern and elevated RoPE score, supported a probable causal relationship between the PFO and the ischemic event. Cardiac magnetic resonance contributed to the characterization of high-risk interatrial septal anatomy and strengthened the etiological characterization of the stroke.

A comprehensive etiological evaluation guided by ISPS25, together with validated risk stratification tools such as RoPE and PASCAL, may allow reclassification of selected ESUS cases and support more

individualized secondary prevention strategies.

This integrative approach may contribute to a more accurate etiological assessment and facilitate the identification of patients who may benefit from percutaneous PFO closure, based on the available evidence from randomized clinical trials. However, the present case only illustrates the clinical application of these diagnostic tools.

Additional Information

Author Contributions

All authors have reviewed the final version to be published and agreed to be accountable for all aspects of the work.

Concept and design: David Martinez Juarez, Omar Gomez-Monterrosas, Marco Antonio Ortiz-Chávez

Acquisition, analysis, or interpretation of data: David Martinez Juarez, Omar Gomez-Monterrosas, Marco Antonio Ortiz-Chávez

Drafting of the manuscript: David Martinez Juarez, Omar Gomez-Monterrosas, Marco Antonio Ortiz-Chávez

Critical review of the manuscript for important intellectual content: David Martinez Juarez, Omar Gomez-Monterrosas, Marco Antonio Ortiz-Chávez

Supervision: David Martinez Juarez, Omar Gomez-Monterrosas, Marco Antonio Ortiz-Chávez

Disclosures

Human subjects: Informed consent for treatment and open access publication was obtained or waived by all participants in this study. **Conflicts of interest:** In compliance with the ICMJE uniform disclosure form, all authors declare the following: **Payment/services info:** All authors have declared that no financial support was received from any organization for the submitted work. **Financial relationships:** All authors have declared that they have no financial relationships at present or within the previous three years with any organizations that might have an interest in the submitted work. **Other relationships:** All authors have declared that there are no other relationships or activities that could appear to have influenced the submitted work.

References

1. Hart RG, Diener HC, Coutts SB, et al.: Embolic strokes of undetermined source: the case for a new clinical construct. Lancet Neurol. 2014, 13:429-38. 10.1016/S1474-4422(13)70310-7
2. Yaghi S, Johansen MC, Ghannam M, et al.: Proposal for the ischemic stroke phenotyping system 2025: ISPS25. Stroke. 2025, 56:3552-62. 10.1161/STROKEAHA.125.051169
3. Mas JL, Arquizan C, Lamy C, Zuber M, Cabanes L, Derumeaux G, Coste J: Recurrent cerebrovascular events associated with patent foramen ovale, atrial septal aneurysm, or both. N Engl J Med. 2001, 345:1740-6. 10.1056/NEJMoa011503
4. Kent DM, Saver JL, Ruthazer R, et al.: Risk of paradoxical embolism (RoPE)-estimated attributable fraction correlates with the benefit of patent foramen ovale closure: an analysis of 3 trials. Stroke. 2020, 51:3119-23. 10.1161/STROKEAHA.120.029350
5. Kent DM, Wang AY: Patent foramen ovale and stroke: a review. JAMA. 2025, 334:1463-73. 10.1001/jama.2025.10946
6. Hart RG, Sharma M, Mundl H, et al.: Rivaroxaban for stroke prevention after embolic stroke of undetermined source. N Engl J Med. 2018, 378:2191-201. 10.1056/NEJMoa1802686
7. Hart RG, Catanese L, Perera KS, Ntaios G, Connolly SJ: Embolic stroke of undetermined source: a systematic review and clinical update. Stroke. 2017, 48:867-72. 10.1161/STROKEAHA.116.016414
8. Duering M, Biessels GJ, Brodtmann A, et al.: Neuroimaging standards for research into small vessel disease—advances since 2013. Lancet Neurol. 2023, 22:602-18. 10.1016/S1474-4422(23)00131-X
9. Strambo D, Sirimarco G, Nannoni S, Perlepe K, Ntaios G, Vemmos K, Michel P: Embolic stroke of undetermined source and patent foramen ovale: risk of paradoxical embolism score validation and atrial fibrillation prediction. Stroke. 2021, 52:1643-52. 10.1161/STROKEAHA.120.032453
10. Saver JL: Cryptogenic stroke. N Engl J Med. 2016, 374:2065-74. 10.1056/NEJMcp1503946
11. Saver JL, Carroll JD, Thaler DE, Smalling RW, MacDonald LA, Marks DS, Tirschwell DL: Long-term outcomes of patent foramen ovale closure or medical therapy after stroke. N Engl J Med. 2017, 377:1022-32. 10.1056/NEJMoa1610057
12. Søndergaard L, Kasner SE, Rhodes JF, et al.: Patent foramen ovale closure or antiplatelet therapy for cryptogenic stroke. N Engl J Med. 2017, 377:1033-42. 10.1056/NEJMoa1707404
13. Mas JL, Derumeaux G, Guillon B, et al.: Patent foramen ovale closure or anticoagulation vs. antiplatelets after stroke. N Engl J Med. 2017, 377:1011-21. 10.1056/NEJMoa1705915
14. Lee PH, Song JK, Kim JS, et al.: Cryptogenic stroke and high-risk patent foramen ovale: the DEFENSE-PFO trial. J Am Coll Cardiol. 2018, 71:2335-42. 10.1016/j.jacc.2018.02.046