Cureus
Part of SPRINGER NATURE

Open Access Case Report

Pediatric Scurvy: A Rare but Reversible Diagnosis

Hamda Almehairi [1], Fatma Alzarooni [2], Athari Aldosari [2]

1. Pediatrics, Al Jalila Children's Hospital, Dubai, ARE 2. General Pediatrics, Al Jalila Children's Hospital, Dubai, ARE

Corresponding author: Hamda Almehairi, hamjalmheiri@dubaihealth.ae

Review began 02/08/2026
Review ended 11/16/2026
Published 11/21/2026

© **Copyright** 2026
Almehairi et al. This is an open access article distributed under the terms of the Creative Commons Attribution License CC-BY 4.0., which permits unrestricted use, distribution, and reproduction in any medium, provided the original author and source are credited.

DOI: 10.7759/cureus.120068

Abstract

Scurvy, a vitamin C deficiency disease that was historically common, is now rare but still occurs in children with a selective diet that almost completely avoids vitamin C-rich foods. In this case report of a seven-year-old boy suffering from paediatric scurvy, we describe a child who presented to the Emergency Department (ED) with a two-week history of difficulty walking, a one-week history of gum bleeding, and a one-month history of bilateral knee swelling and pain following a minor fall. Before this visit, he had been evaluated in a paediatric dental clinic, where he was prescribed oral amoxicillin-clavulanate for gum symptoms. Knee ultrasound showed anechoic joint fluid, initially interpreted as a resolving haematoma. He was then referred to rheumatology with a working impression of reactive arthritis and was managed conservatively. On admission to our service, a detailed dietary history revealed a long-standing self-selected diet of bread, rice, and some yogurt, with no fruits, vegetables, or citrus, raising strong suspicion for scurvy. Vitamin C supplementation was started as both a diagnostic and therapeutic trial. The serum vitamin C level was severely low (<0.1 mg/dL), gum hypertrophy improved within five days, and his clinical symptoms, anaemia, and vitamin C level improved by two months, demonstrating the reversibility of scurvy with appropriate doses of vitamin C. This case highlights the importance of considering nutritional deficiencies, including scurvy, in children with musculoskeletal complaints and bleeding symptoms, particularly when the dietary history suggests a lack of vitamin C-containing foods.

Categories: Nutrition, Rheumatology, Pediatrics
Keywords: case report, paediatric, scurvy, selective diet, vitamin c deficiency

Introduction

Scurvy is a nutritional deficiency disorder resulting from prolonged insufficiency of vitamin C (ascorbic acid), an essential cofactor for collagen synthesis, iron absorption, and antioxidant defence mechanisms. Although historically associated with sailors and famine, scurvy continues to be reported in modern, high-income settings, particularly among vulnerable groups such as children with selective eating habits, neurodevelopmental disorders, or chronic illnesses. Recent case series and hospital-based studies indicate a rising trend in paediatric scurvy recognition, likely due to improved clinical awareness and more frequent use of imaging modalities for evaluation [1-3]. In these children, the deficiency usually arises not from a prescribed restrictive diet but from a long-standing pattern of eating that excludes citrus fruits, other fresh fruits, and vegetables.

The clinical presentation of scurvy is often subtle and nonspecific in early stages, manifesting initially with fatigue, malaise, irritability, and anorexia, before progressing to more distinctive features such as gingival hypertrophy and bleeding, petechiae, ecchymoses, musculoskeletal pain, and pseudoparalysis [4,5]. These manifestations can mimic serious conditions including haematological malignancy, juvenile idiopathic arthritis, osteomyelitis, or even non-accidental injury, frequently leading to diagnostic delays and unnecessary investigations.

We present the case of a seven-year-old boy with a prolonged selective diet lacking vitamin C-rich foods who developed progressive musculoskeletal symptoms and bleeding manifestations, highlighting the importance of careful dietary history, recognition of typical imaging findings, and the rapid clinical response to vitamin C supplementation [6,7]. This case underscores that, despite being preventable and easily treatable, scurvy remains a diagnostic challenge in paediatrics when clinical suspicion is low.

Case Presentation

A seven-year-old boy presented to the Emergency Department (ED) with a two-week history of difficulty walking and a one-month history of knee swelling and pain. He also reported gum bleeding and swelling for the past week. Prior to the ED visit, he had consulted a paediatric dentist for the gum bleeding, who attributed it to new teething and prescribed oral amoxicillin-clavulanate. One month earlier, the child had fallen on his right knee, followed by a second fall about a week later. He visited a private clinic where a knee X-ray was performed, showing no fractures. He used a knee binder for a few days but removed it when his leg began to swell. Since then, he has continued to experience knee pain and difficulty walking.

The main joint involvement is bilateral in the knees, with the right knee more affected than the left. The

child can take a few steps when supported but experiences intense pain when bearing weight. He has been using a stroller for mobility. According to his mother, he performs physiotherapy at home using a cycling machine, which slightly alleviates the pain. She also reported that he had weakness in both hands prior to the trauma, but he can still open a water bottle and brush his hair. Before last month, he was able to run and play football at school.

Dietary history

He has had poor feeding since a young age, as reported by his mother; a dietitian was involved during admission to support his feeding. His usual food intake since early childhood has consisted only of bread, rice, and small amounts of yogurt, with no fruits, vegetables, citrus, or protein sources. This was a self-selected eating pattern, not a prescribed diet, and it meant almost complete avoidance of vitamin C-rich foods for a long period. Over the past year, he has lost additional weight, and his growth chart shows a severe decline, with his weight dropping below the 1st percentile. He saw a dietitian one year ago, who recommended multivitamins, but he is not taking them at home.

Regarding his past medical and surgical history, the patient has strabismus and is under regular follow-up with ophthalmology. He underwent a left-sided herniotomy on August 28, 2017. He was born at 32 weeks via C-section and was admitted to the NICU for three weeks but did not require any oxygen support, according to his mother. He was born to non-consanguineous parents and has three older, healthy siblings, with no chronic diseases in the family. The siblings eat a normal, varied diet. The patient has had food selectivity since a young age; his development has been normal, and no feeding disorder was formally assessed.

In the ED, laboratory tests showed negative inflammatory markers, with a mildly elevated erythrocyte sedimentation rate (ESR) of 33 mm/h, a normal coagulation profile, and normal creatine phosphokinase (CPK). An ultrasound (USS) of the hip and knee was performed. The hip ultrasound was reassuring. The right knee ultrasound findings were discussed with the radiologist and evaluated for signs of infection or inflammation. There was no synovial thickening and no increased vascularity, only minimal anechoic fluid in both suprapatellar pouches (about 0.5 cm in thickness) (Figure *1*). The radiologist advised that the anechoic fluid could be a resolving haematoma. The child was referred to the rheumatology clinic with a suspicion of reactive arthritis and was discharged with symptomatic treatment.

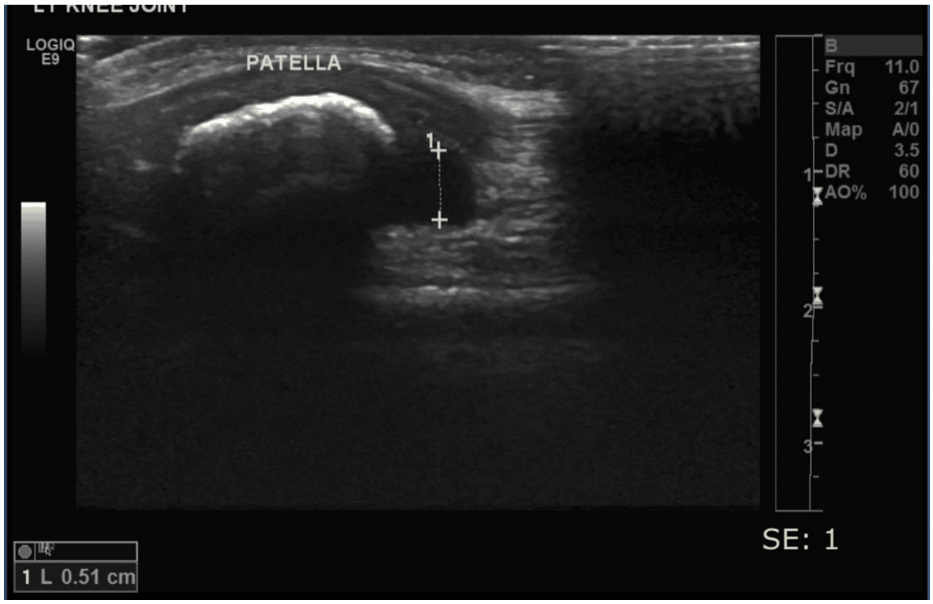

FIGURE 1: Ultrasound of the knees. Minimal anechoic fluid is seen in both suprapatellar pouches, about 0.5 cm thick, with no focal synovial thickening, no increased vascularity, and normal skin and soft tissues. These findings argue against septic or inflammatory arthritis.

Seen in the rheumatology clinic, the child was sitting in a stroller during the examination. He appeared thin and had prominence of the knee bones and a small petechial rash on both lower limbs (Figure *2*). He had gum hypertrophy, dusky grayish-blue in color, with no active bleeding (Figure *3*). He cried throughout the examination and exhibited tenderness around the knee joint and over the long bones. He refused to bear weight on his own while walking with assistance.



FIGURE 2: Prominence of knee bones and small petechial rash seen in both lower limbs.



FIGURE 3: Gum hypertrophy with a dusky grayish-blue color prior to vitamin C treatment.

Because of his limp and difficulty walking and the need to rule out other causes such as osteomyelitis, he was admitted to the ward for further work-up. During his hospital stay, ascorbic acid 100 mg three times daily was started for one week on clinical suspicion, before the vitamin C result was available. He also received vitamin D 25,000 IU weekly because his measured vitamin D level was low. Magnetic resonance imaging (MRI) with contrast of both lower limbs was performed, which revealed a broad area of T1 hypointensity and T2 hyperintensity involving the metaphysis of the bilateral femurs, tibias, and fibulas (Figure *4*). The affected areas showed no evidence of restricted diffusion, with only minimal contrast enhancement identified. No abnormal soft tissue signal or enhancement was observed. There was also no evidence of any intra-articular abnormalities in both lower limbs. The heights of the bilateral capital femoral epiphyses were well preserved. The bone marrow signal in the rest of the visualised skeleton was within normal limits, except for the areas mentioned above. The differential diagnosis for the imaging findings included red marrow conversion, leukaemia, and scurvy, as described in previous reports of musculoskeletal scurvy.

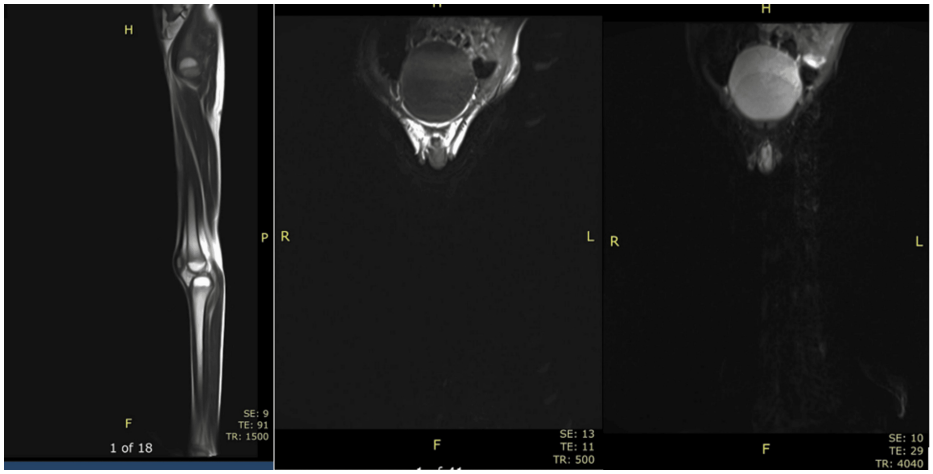

FIGURE 4: Magnetic resonance imaging (MRI) with contrast of both lower limbs of a seven-year-old boy suffering from paediatric scurvy. Symmetric metaphyseal T1 hypointensity and T2 hyperintensity of the femurs, tibias, and fibulas, with minimal enhancement and no soft tissue or intra-articular abnormality, are the features to look for.

The patient was reviewed by a dietitian and started on 400 mL/day of Pediasure, a synthetic, nutritionally complete paediatric formula containing protein, fat, carbohydrate, vitamins including vitamin C, and minerals, until his eating habits improve. The gastroenterology team was consulted for failure to thrive (FTT); investigations for coeliac disease and FTT were unremarkable. The vitamin C level was severely low at <0.1 mg/dL. The haematology/oncology team was consulted regarding bicytopenia, and the anaemia was attributed to scurvy (Table *1*). The mother was reassured that his haemoglobin level would increase as his vitamin C level improved. Gum hypertrophy improved after five days of vitamin C treatment (Figure *5*). His other clinical symptoms also improved after vitamin C was started. The boy was discharged on vitamin C tablets 100 mg daily for two months. A repeat vitamin C level after two months showed improvement to 0.7 mg/dL. At the two-month follow-up, his clinical symptoms had improved significantly, in step with the rise in vitamin C level and haemoglobin.

Parameter	Reference range	At presentation	Interpretation	Follow-up (two months)	Interpretation
Hemoglobin (g/dL)	11.5-15.5 g/dL	10.1	Decreased	11.8	Improving/normal
WBC (×10³/µL)	5.0-13.0 10^3/uL	4.0	Decreased	4.9	Improving
Platelets (×10³/µL)	170-450 10^3/uL	341	Normal	260	Normal
Hematocrit (%)	35.0-45.0%	31.8	Decreased	35	Improving/normal
MCV (fL)	77.0-95.0 fL	82.3	Normal	85.4	Normal
ESR (mm/h)	<20	33	Mildly increased	—	—
CRP (mg/L)	<5	Normal	Normal	—	—
CPK (U/L)	68-293 U/L	48	Low/normal	—	—
Vitamin C (mg/dL)	0.4-2.0	<0.1	Severely decreased	0.7	Improved, low–normal

TABLE 1: Biochemical parameters of a seven-year-old boy suffering from paediatric scurvy.



FIGURE 5: Improvement of paediatric scurvy in a seven-year-old boy after five days of vitamin C treatment: the gum hypertrophy has reduced and the dusky grayish-blue color has faded.

Discussion

Diagnostic reasoning

In this case report of a seven-year-old boy suffering from paediatric scurvy, the symptoms initially pointed to other potential diagnoses, such as leukaemia, failure to thrive, and reactive arthritis, which are common differentials in children presenting with musculoskeletal pain and systemic symptoms [1,4]. Suspicion of scurvy arose from the dietary history, which showed almost complete avoidance of fruits and vegetables, together with gum hypertrophy, petechiae, bone tenderness, and refusal to bear weight. These findings were not explained by the initial work-up: CRP and coagulation were normal, and ultrasound showed no synovitis. Our team had not previously encountered a case of scurvy, as it is very rare. The diagnosis was supported by the severely low vitamin C level, the metaphyseal MRI changes, and the clinical response to vitamin C. The patient displayed multiple classic signs of scurvy, and once the diagnosis was considered, it allowed early treatment and rapid clinical improvement (Figure *5*). The patient's symptoms were consistent with typical scurvy manifestations, including joint pain, difficulty walking, refusal to bear weight, petechial rash, and gum swelling and bleeding [1-3,5].

In this case report of a seven-year-old boy suffering from paediatric scurvy, whose clinical signs included gum hypertrophy, petechiae, bone tenderness, and refusal to bear weight, these signs are linked to the underlying pathology of scurvy, where defective collagen production weakens blood vessels and connective tissues, predisposing to bleeding and musculoskeletal symptoms [6,7]. Vitamin C serves as an essential cofactor for prolyl and lysyl hydroxylase enzymes, which are critical for stabilising collagen triple helix formation. Without adequate vitamin C, defective collagen synthesis affects multiple organ systems, particularly those with high collagen turnover such as blood vessels, bone, and gingival tissues [7].

Similar to our case report of a seven-year-old boy, Regehr et al. (2021) reported a modern case of scurvy in a patient with dietary restrictions who presented with lower extremity pain and ecchymoses, demonstrating the persistence of this condition in contemporary settings [1]. Ben Ahmed et al. (2021) described a paediatric case with comparable clinical features, including refusal to walk, gingival bleeding, and cutaneous haemorrhages, further supporting the characteristic presentation pattern observed in our patient [2]. The delayed diagnosis in many reported cases underscores the low clinical suspicion for scurvy in high-income countries, despite its continued occurrence [3,4].

The musculoskeletal manifestations observed in our patient, including lower limb pain, pseudoparalysis, and refusal to bear weight, are consistent with findings reported by Ferrari et al. (2015), who described the rheumatic manifestations of scurvy and emphasised that these symptoms frequently lead to misdiagnosis as

inflammatory arthritis or malignancy [5]. Gaieski (2024) highlighted that scurvy often masquerades as more serious conditions, resulting in extensive diagnostic work-ups and delayed treatment [4]. This diagnostic challenge is particularly relevant in paediatric populations, where non-specific symptoms such as irritability, fatigue, and musculoskeletal pain may be attributed to more common childhood conditions.

This case emphasises the need to consider scurvy in children whose diet avoids vitamin C-rich foods, including those with neurodevelopmental or behavioural conditions that limit food variety, as described in other modern reports [1-3]. The patient's long-standing near-total avoidance of fruits, vegetables, and citrus likely played a central role in the development of his deficiency. Children with autism spectrum disorder, selective eating disorder, and other neurodevelopmental conditions are at particularly high risk due to food aversions and limited dietary variety, a pattern increasingly recognised in recent literature.

Reversibility of scurvy

The rapid response to vitamin C supplementation in our case mirrors findings reported across multiple case series, where clinical improvement typically begins within days of treatment initiation [1,2,6]. A key feature of this case is the reversibility of scurvy. Vitamin C is a cofactor for collagen synthesis, so once adequate doses were given (100 mg three times daily for one week, then 100 mg daily for two months), the gingival and haematological abnormalities improved, the vitamin C level rose from <0.1 to 0.7 mg/dL, and his clinical symptoms improved significantly. This confirms that deficiency-related damage is reversible when the condition is identified and treated early. Pollard (2013) emphasised the critical role of vitamin C in wound healing and tissue repair, mechanisms that explain the swift resolution of haemorrhagic and musculoskeletal symptoms following supplementation [6]. This therapeutic response serves as both a diagnostic confirmation and a reminder of the reversibility of nutritional deficiencies, especially vitamin C deficiency, when identified early. In our patient, reversibility was shown on several levels. Clinically, the gum hypertrophy improved within five days (Figure *5*), and his other clinical symptoms improved significantly over about two months. Biochemically, the vitamin C level rose from <0.1 to 0.7 mg/dL after two months. Haematologically, haemoglobin rose from 10.1 to 11.8 g/dL, haematocrit from 31.8% to 35%, and the white cell count from 4.0 to 4.9 $\times 10^3/\mu L$, supporting the attribution of the anaemia to scurvy. Once vitamin C is replaced, collagen synthesis resumes and capillary fragility and bleeding settle, which explains why these changes recovered with 100 mg three times daily for one week, then 100 mg daily for two months, together with an improved diet. The MRI was not repeated.

Scurvy can often present with vague, non-specific symptoms, making early diagnosis challenging [3,4]. This case report highlights several important lessons for clinicians: maintaining vigilance for scurvy even in developed countries; considering it in children with diets lacking vitamin C-rich foods or developmental disorders; recognising that its clinical presentation can mimic haematological, rheumatological, or orthopaedic diseases [4,5]; performing thorough dietary assessments in children with unexplained musculoskeletal or dermatological symptoms; and initiating vitamin C supplementation promptly when scurvy is suspected, as this both confirms the diagnosis and leads to rapid clinical improvement [1,2,6,7]. In addition, imaging findings such as the "Pelkan spurs" and metaphyseal changes seen on radiography can support the diagnosis (in our patient, the metaphyseal changes are shown on MRI in Figure *4*), though these are not pathognomonic and may be absent in early stages.

Furthermore, this case underscores the importance of nutritional screening in paediatric practice, particularly for children with behavioural feeding difficulties or chronic medical conditions that may affect dietary intake. Early identification of at-risk populations and preventive supplementation could reduce the incidence of this entirely preventable condition.

Conclusions

In this case report of a seven-year-old boy with paediatric scurvy, a long-standing selective diet limited to bread, rice, and some yogurt, with almost complete avoidance of vitamin C-rich foods (citrus fruits, other fresh fruits, and vegetables), led to progressive knee pain, refusal to bear weight, gum hypertrophy, petechiae, and anaemia. The diagnosis was suspected from a detailed dietary history and the characteristic clinical findings, and it was supported by a severely low serum vitamin C level (<0.1 mg/dL) and metaphyseal changes on MRI, after other causes such as leukaemia, reactive arthritis, and coeliac disease were considered. Vitamin C supplementation served as both a diagnostic and therapeutic trial. Gum hypertrophy improved within five days, and after two months of treatment the vitamin C level rose to 0.7 mg/dL, haemoglobin normalised (10.1 to 11.8 g/dL), and his clinical symptoms improved significantly. This recovery demonstrates the reversibility of scurvy with appropriate doses of vitamin C. Although easily treatable and cost-effective, scurvy can become life-threatening if not identified and addressed promptly. Clinicians should therefore take a careful dietary history and consider scurvy in the differential diagnosis of children with musculoskeletal pain or bleeding who have limited intake of fruits and vegetables.

Additional Information

Author Contributions

All authors have reviewed the final version to be published and agreed to be accountable for all aspects of the

work.

Concept and design: Hamda Almehairi, Fatma Alzarooni, Athari Aldosari

Acquisition, analysis, or interpretation of data: Hamda Almehairi, Fatma Alzarooni, Athari Aldosari

Drafting of the manuscript: Hamda Almehairi, Fatma Alzarooni, Athari Aldosari

Critical review of the manuscript for important intellectual content: Hamda Almehairi, Fatma Alzarooni, Athari Aldosari

Supervision: Hamda Almehairi, Fatma Alzarooni, Athari Aldosari

Disclosures

Human subjects: Informed consent for treatment and open access publication was obtained or waived by all participants in this study. **Conflicts of interest:** In compliance with the ICMJE uniform disclosure form, all authors declare the following: **Payment/services info:** All authors have declared that no financial support was received from any organization for the submitted work. **Financial relationships:** All authors have declared that they have no financial relationships at present or within the previous three years with any organizations that might have an interest in the submitted work. **Other relationships:** All authors have declared that there are no other relationships or activities that could appear to have influenced the submitted work.

References

1. Regehr J, Kriwiel M, Roth E, Ofei-Dodoo S: A case report of a modern-day scurvy . Kans J Med. 2021, 14:51-2. 10.17161/kjm.vol1414609
2. Ben Ahmed S, Mezghani F, Rhayem S, Fedhila F, Hadded S: Scurvy still exists in children: a case report . Tunis Med. 2021, 99:1093-6.
3. Lu RL, Guo JW, Sun BD, Chen YL, Liu DZ: Scurvy in a young man: a rare case report . Front Nutr. 2023, 10:1265334. 10.3389/fnut.2023.1265334
4. Gaieski DF: Scurvy: a rare disease or a rare diagnosis? . J Emerg Trauma Shock. 2024, 17:53-7. 10.4103/jets.jets_108_23
5. Ferrari C, Possemato N, Pipitone N, Manger B, Salvarani C: Rheumatic manifestations of scurvy . Curr Rheumatol Rep. 2015, 17:26. 10.1007/s11926-015-0503-6
6. Pollard C: Nutrition 411: revisiting vitamin C and wound healing . Wounds. 2013, 25:15-9.
7. Traber MG, Stevens JF: Vitamins C and E: beneficial effects from a mechanistic perspective . Free Radic Biol Med. 2011, 51:1000-13. 10.1016/j.freeradbiomed.2011.05.017