Cureus
Part of SPRINGER NATURE

Open Access Case Report

Pseudoepitheliomatous Hyperplasia of the Medial Thigh with Dystrophic Calcification and Metaplastic Ossification: A Case Report

Linda M. Oster [1, 2], Michael C. Zornes [2], Patricia Palanca [2], Adelso Tejada Jackson [2], Dmitriy Kim [2]

1. Department of Surgery, Ross University School of Medicine, Miramar, USA 2. Department of Surgery, St. John's Episcopal Hospital, Far Rockaway, USA

Corresponding author: Linda M. Oster, osterlinda4@gmail.com

Review began 11/05/2025
Review ended 05/09/2026
Published 05/11/2026

© **Copyright** 2026
Oster et al. This is an open access article distributed under the terms of the Creative Commons Attribution License CC-BY 4.0., which permits unrestricted use, distribution, and reproduction in any medium, provided the original author and source are credited.

DOI: 10.7759/cureus.108631

Abstract

Pseudoepitheliomatous hyperplasia (PEH) is a benign, reactive epidermal proliferation that may histologically mimic squamous cell carcinoma (SCC) due to its pseudo-infiltrative growth pattern. While typically associated with chronic inflammation, trauma, or infection, it is considered to be benign and does not warrant oncological management. Here, we present the case of a 71-year-old African American female with morbid obesity among other comorbidities who presented with a painful, ulcerated right medial thigh mass of 10 years' duration. The patient, a nursing home resident, reported significant localized pain upon presentation. Imaging revealed a large soft-tissue mass with calcification. Biopsy revealed ulcerated skin and extensively fibrosed subcutaneous tissue exhibiting dystrophic calcification, ossification, and granulation tissue, without features of malignancy. Final pathology confirmed PEH. Following the biopsy and confirmation of the benign nature of the lesion, the patient's management focused on conservative wound care and pain control, successfully avoiding the morbidity of radical surgical resection. This case underscores the diagnostic challenge in differentiating PEH from SCC and highlights the importance of making a clear diagnosis to provide great patient care and avoid unnecessary treatments that carry risk.

Categories: General Surgery, Pathology, Dermatology
Keywords: cutaneous lesion, epidermal proliferation, non-neoplastic skin lesion, pseudoepitheliomatous hyperplasia, squamous cell carcinoma of the skin

Introduction

Pseudoepitheliomatous hyperplasia (PEH) is defined as a benign reactive proliferation of the epidermis characterized by the downward projection of squamous epithelium into the dermis. Histologically, its pseudo-infiltrative growth pattern can closely resemble squamous cell carcinoma (SCC) [1-4]. PEH may arise in association with chronic inflammation, infection, trauma, or neoplasia, and is even seen adjacent to or in conjunction with SCC [2-6]. Additionally, while PEH has been documented in many anatomical locations (most notably the oral mucosa, the vulva, and increasingly in cutaneous reactions to red ink tattoos), its presentation in the lower extremities is unusual and potentially under-recognized. More specifically, the clinical and pathological similarities that exist between PEH and SCC make thorough evaluation paramount to avoid misdiagnosis and potential overtreatment [3,4,7-11]. To demonstrate the novelty of this case and provide a comparison with previously reported instances of PEH in the literature, we have summarized a brief literature search performed using PubMed. In total, 45 case reports published between 2006 and 2026 were included in the review, excluding all non-human case reports and articles written in a language other than English.

Case Presentation

A 71-year-old African American female with a past medical history of morbid obesity, hyperlipidemia, hypothyroidism, hypertension, uterine cancer s/p hysterectomy, and depression presented to the emergency department at a community hospital in Far Rockaway, New York, in October 2024. The patient presented to the hospital for a mass on her right medial thigh, which had been present for 10 years and had recently become painful and ulcerated over a three-week period despite routine wound care. The patient reported that the mass had not grown in size during this time. On assessment, the patient was hemodynamically stable, afebrile, and alert. On initial examination, the area of ulceration of the right medial thigh measured 4 × 4 cm, was non-foul-smelling, had no discharge, and was tender to palpation.

Laboratory findings on admission were significant for hyperlipidemia (Table *1*). Notably, metabolic markers, including calcium (9.3 mg/dL) and phosphate (3.6 mg/dL), were normal. CT imaging (Figure *1*) showed a large soft-tissue mass with coarse, calcific deposits overlying skin thickening and ulceration associated with a mass in the right proximal thigh measuring 17 × 8.8 cm. The CT topogram (Figure *1a*) provided a definitive gross view of the mass's location and scale, while the axial and coronal views (Figures *1b*, *1c*) delineated the extensive internal mineralization.

How to cite this article
Oster L M, Zornes M C, Palanca P, et al. (May 11, 2026) Pseudoepitheliomatous Hyperplasia of the Medial Thigh with Dystrophic Calcification and Metaplastic Ossification: A Case Report . Cureus 18(5): e108631. DOI 10.7759/cureus.108631

Category	Test	Result	Reference range	Interpretation
Inflammation and infection	WBC count	4.9 × 10^3/L	5.2–12.4 × 10^3/L	Low
Metabolic Panel	Albumin	3.3 g/dL	3.5–5.0 g/dL	Low
	Calcium	9.3 mg/dL	8.4–10.2 mg/dL	WNL
	Phosphate	3.6 mg/dL	2.5–4.5 mg/dL	WNL
	Sodium	139 mmol/L	137-145 mmol/L	WNL
	Potassium	4.2 mmol/L	3.5–5.1 mmol/L	WNL
	Chloride	111 mmol/L	98–107 mmol/L	High
Iron studies	Hemoglobin	13.4 g/dL	12.0–16.0 g/dL (F)	Low
	Hematocrit	35.5	37–37	Low
Lipids	Total cholesterol	211 mg/dL	<200 mg/dL	Borderline High
	LDL cholesterol	150 mg/dL	<100 mg/dL	High
	VLDL cholesterol	21.4 mg/dL	5–40 mg/dL	WNL
	HDL (direct)	30 mg/dL	≥60 mg/dL	Low
	Cholesterol/HDL ratio	7	<4	Elevated cardiovascular risk

TABLE 1: Laboratory findings.

WBC = white blood cell; LDL = low-density lipoprotein; VLDL = very-low-density lipoprotein; HDL = high-density lipoprotein; WNL = within normal limit

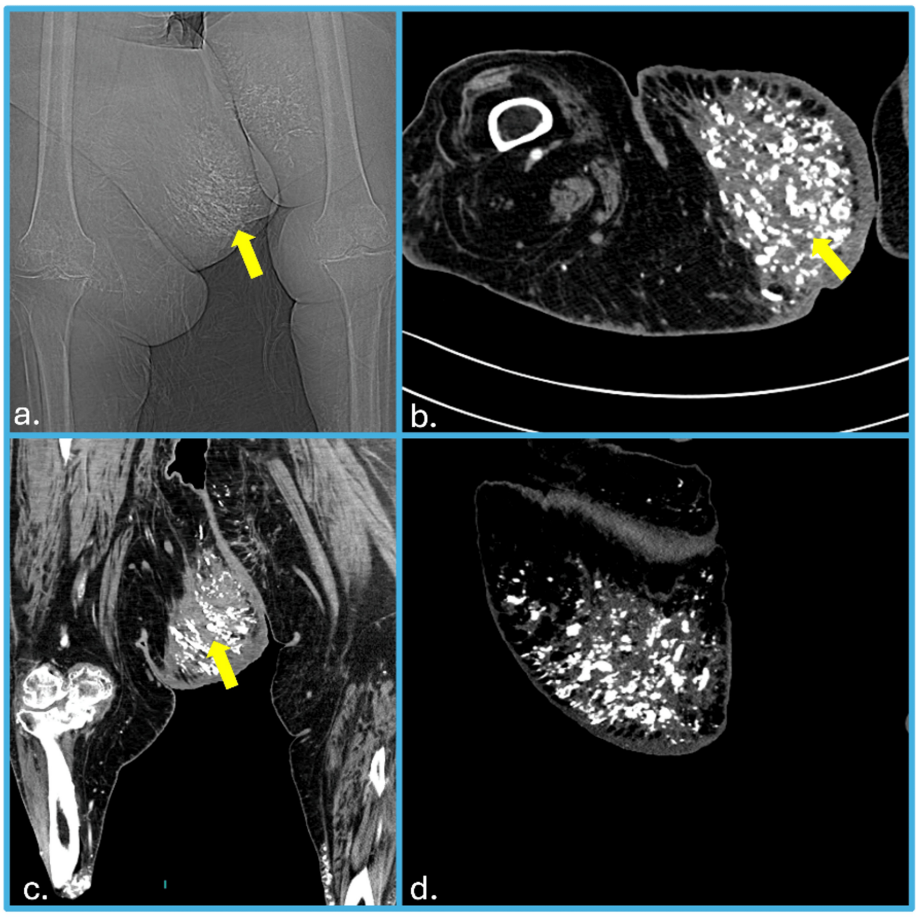

FIGURE 1: CT imaging of the right lower extremity.

(a) Topogram of the lesion with the yellow arrow pointing to the mass grossly seen on the right medial thigh. (b) Axial soft-tissue view of the right lower extremity with the yellow arrow pointing to the mass. (c) Coronal soft-tissue view of the right lower extremity with the yellow arrow pointing to the mass. (d) A sagittal soft-tissue view of the right lower extremity mass.

Intraoperatively, a full-thickness biopsy was obtained. Specimens were fixed in formalin and appeared as an aggregate of soft-to-hard tissue fragments measuring 2.0 × 1.5 × 0.5 cm. Hematoxylin and eosin staining was performed.

Ultimately, due to the high burden of comorbidities and benign nature of the lesion, the patient underwent conservative management with both inpatient wound care and pain management and was referred for regular outpatient wound care follow-up.

Pathology findings

On examination, pathological analysis revealed ulcerated skin along with extensively fibrosed subcutaneous tissue, calcification, and ossification with acute and chronic inflammation and granulation tissue (Figure *2*). The aforementioned findings were largely non-neoplastic in nature. Final pathology revealed PEH, ulceration, fibrinopurulent exudate, granulation tissue reaction, fat necrosis, and dystrophic calcification.

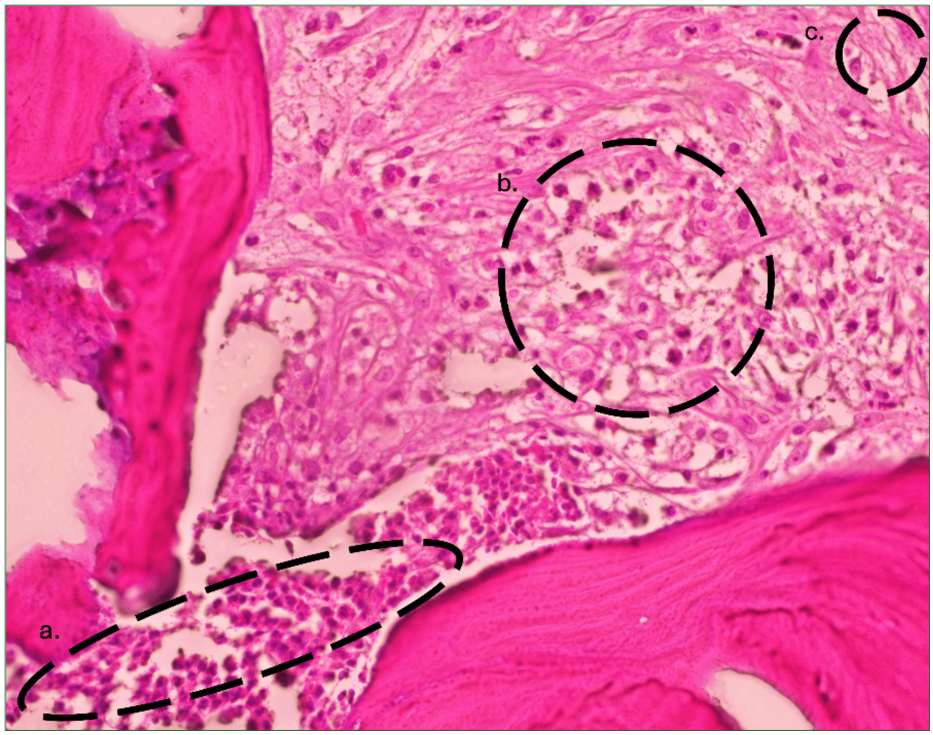

FIGURE 2: Histologic section of ulcerated subcutaneous tissue demonstrating some key reactive changes seen in pseudoepitheliomatous hyperplasia.

Hematoxylin and eosin stain, original magnification ×200. (a) Mature lamellar bone formation with surrounding inflammatory infiltrate (circled), consistent with reactive bone formation. (b) Central area of granulation tissue, characterized by a dense mixed inflammatory infiltrate, including neutrophil, lymphocytes, and vascular proliferation. (c) Upper right portion shows dense fibrosis, with eosinophilic collagen bundles indicating a chronic reparative response.

Discussion

PEH is a reactive epithelial proliferation often associated with chronic inflammation, infection, trauma, or cancer [1-4]. In this patient, the likely precipitating factor for the development of PEH was a 10-year course of mechanical friction due to high adiposity in the lower extremities secondary to morbid obesity and limited mobility. For a patient who presented with such a long-standing lesion, differentiation between PEH and SCC was vital to provide appropriate care.

Interestingly, the occurrence of PEH in the lower extremity, particularly in association with the combination of ulceration and dystrophic calcification, is rare and may be underreported (Table *2*). Calcification itself is often seen in the setting of chronic wounds or inflammation [6,7], and in this case may also be a manifestation of prolonged tissue damage. Furthermore, histologic analysis of the specimen not only demonstrated calcification but also revealed the presence of ossification. The possibility of metaplastic ossification as a downstream consequence of chronic inflammation not only complicates interpretation for the clinical team but is even more rarely documented in the context of PEH [4,8].

	Study	Location	Precipitating factor/trigger	Primary histopathological findings
	Zhang et al. [12]	Auricle	Chronic inflammation (unspecified)	Reactive epidermal hyperplasia requiring complex surgical reconstruction; mimics invasive squamous cell carcinoma (SCC)
	Nayak et al.; Thorat et al.; Xiang et al. [3,13,14]	Gingival/Oral	Periodontal disease; lung neoplasia; or general review	Thorat et al. (2011) noted primary gingival PEH with periodontal findings; Xiang et al. (2012) described a “giant” presentation associated with lung SCC; Nayak et al. (2015) reported a clinical review of diagnostic criteria in oral lesions

Head and neck	Raposo et al. [15]	Larynx	Chronic inflammation (unspecified)	Extreme reactive hyperplasia requiring aggressive intervention, including total laryngectomy
	Val-Bernal et al. [16]	Lingual	Subgemmal neurogenous plaques	Incidental pseudomalignant epidermal growth and reactive changes associated with neurogenous plaques
	Everett et al. [17]	Mandible	Prior oncologic therapy (post-SCC treatment)	Reactive epidermal hyperplasia arising in the mandible following prior treatment for malignancy
	Nonomura et al. [18]	Nasal	Extranodal NK/T-cell lymphoma	Reactive epidermal hyperplasia presenting a diagnostic pitfall for SCC adjacent to lymphoma
Ocular	Joshi et al. [19]	Ocular/Orbital: canalicular	Chronic inflammation	Novel description of isolated canalicular reactive epidermal hyperplasia in the ocular adnexa
	Fatima et al. [20]; Mohebbi et al. [21]	Ocular/Orbital: ocular surface/limbal	Cultivated limbal epithelium transplantation; episcleritis	Reactive hyperplasia mimicking ocular surface squamous neoplasia (OSSN) following surgical transplantation or inflammatory episcleritis
	Doctor et al. [22]	Ocular/Orbital: orbital	Probable IgG4-related orbital disease	Exuberant ocular surface reactive changes masking underlying systemic/orbital inflammatory disease
	Bothra and Ali [23]	Ocular/Orbital: punctal	Chronic inflammation	Reactive epidermal hyperplasia mimicking a mass lesion of the lacrimal punctum
Cutaneous	Amsbaugh et al.; Fischer et al.); Kamalapirat et al.; Quintella et al. [24-27]	Skin: infectious/inflammatory	Chronic infection (leprosy, sporotrichosis, leishmaniasis, bacillary angiomatosis)	Pathogen-induced epidermal hyperplasia; features include transepidermal elimination (leprosy) or lymphocutaneous spread (sporotrichosis)
	Meani et al.; Parsons & Ryder; Pusiol et al.; Speziali et al. [28-31]	Skin: inflammatory conditions	Lichen planus; allergic contact dermatitis; HIV/AIDS	Reactive epidermal proliferation secondary to chronic inflammatory dermatoses or immunocompromised states
	Ansari et al.; Biswas et al.; Ling et al.; Rossi et al.; Shafi et al.; Vucić et al.; Wang et al. [32-38]	Skin: neoplasia and lymphoma	Malignancy (melanoma, cutaneous lymphoma, mycosis fungoides, trichoepithelioma)	Reactive proliferation adjacent to or overlying neoplastic lesions; a frequent diagnostic pitfall for invasive SCC due to pseudo-infiltrative growth
	Badavanis et al.; Breza et al.; Conejero et al.; Conti et al.; Cui et al.; de Roeck et al.; Kiss et al.; Tammaro et al. [39-46]	Skin: red ink tattoo	Red ink/tattoo pigment	Exuberant reactive changes and late-onset epidermal hyperplasia secondary to exogenous tattoo pigment
	Blum & D'Souza [8]	Skin: trauma/foreign body	Displaced metallic orthopedic implant	Reactive epidermal hyperplasia secondary to chronic irritation and trauma from metallic foreign bodies
Other	Desimone et al. [47]	Breast	Granular cell tumor	Exuberant reactive epidermal proliferation adjacent to benign neoplasia of the breast
	Han et al. [48]	Esophagus	Lye-induced chemical trauma	Reactive changes mimicking esophageal SCC secondary to chronic stricture and chemical injury
	Eandi et al. [49]	Urinary bladder	Granular cell	Visceral reactive hyperplasia co-localizing with

			tumor	adenocarcinoma or benign neoplasia
	Frimer et al.; Lee et al.; Tangjitgamol et al. [4,50,51]	Vulvar/Genital	HIV/AIDS; lichen sclerosus; Herpes simplex virus-II	Reactive changes in the genital tract mimicking vulvar cancer; associated with chronic dermatoses or viral infections in immunocompromised patients

TABLE 2: Comparative analysis of reported pseudoepitheliomatous hyperplasia (PEH) cases.

A brief summary of PEH cases published on PubMed between 2006 and 2026, excluding reports not published in the English language and those reporting on PEH in animals.

Histologically, PEH is characterized by irregular acanthosis, elongation of rete ridges, and a pseudo-infiltrative growth pattern that may mimic SCC. However, unlike SCC, PEH lacks cytologic atypia, abnormal mitoses, and actual invasion of surrounding tissues [3]. As illustrated by Chakrabarti et al. [5], these nuanced but crucial differences often require multiple, deep biopsies, tissue culture, immunohistochemistry, and/or immunofluorescence [3], and it is important that clinicians do not overlook the distinction between the two conditions. PEH is considered to be benign, and the standard of care does not include wide excision or lymph node evaluation unless a confirmed malignancy is present. However, despite its benign nature, overtreatment is a well-documented risk due to its close resemblance to SCC, and this makes multidisciplinary collaboration between dermatology, pathology, surgery, and radiology essential in ambiguous cases. Additionally, while surgical excision with clear margins is indicated to avoid recurrence, the clinician must balance this with a holistic approach for each patient. When considering surgical management for either oncologic management of SCC or management of recurrence in PEH, possible morbidity, particularly in elderly or comorbid patients, where radical surgeries may not be well-tolerated, must be considered.

In summary, this case highlights an unusual presentation of PEH resembling ulcerated SCC on physical examination. Uniquely, this case of PEH revealed dystrophic calcification and ossification on histological evaluation, which has not been documented in the recent body of published work. This case not only adds to a growing body of literature on this potentially painful and socially devastating condition but also emphasizes the importance of differentiating PEH from malignancies such as SCC to deliver appropriate and timely care to patients.

Conclusions

PEH remains a diagnostic challenge due to its histologic resemblance to SCC, particularly in chronic, ulcerated lesions with reactive tissue changes. This case highlights an uncommon presentation of PEH involving the thigh with significant dystrophic calcification and ossification, features that are rarely documented together. Recognition of these benign reactive processes is critical to prevent unnecessary aggressive surgical intervention or oncologic management. Clinicians should maintain a high index of suspicion and pursue thorough histopathologic correlation when evaluating chronic cutaneous lesions with atypical features. Ultimately, multidisciplinary collaboration between dermatology, pathology, radiology, and surgery ensures accurate diagnosis and optimal patient outcomes in such diagnostically complex cases.

Additional Information

Author Contributions

All authors have reviewed the final version to be published and agreed to be accountable for all aspects of the work.

Concept and design: Linda M. Oster, Michael C. Zornes, Adelso Tejada Jackson, Patricia Palanca, Dmitriy Kim

Drafting of the manuscript: Linda M. Oster

Critical review of the manuscript for important intellectual content: Michael C. Zornes, Adelso Tejada Jackson, Patricia Palanca, Dmitriy Kim

Supervision: Dmitriy Kim

Disclosures

Human subjects: Informed consent for treatment and open access publication was obtained or waived by all participants in this study. **Conflicts of interest:** In compliance with the ICMJE uniform disclosure form, all authors declare the following: **Payment/services info:** All authors have declared that no financial support

was received from any organization for the submitted work. **Financial relationships:** All authors have declared that they have no financial relationships at present or within the previous three years with any organizations that might have an interest in the submitted work. **Other relationships:** All authors have declared that there are no other relationships or activities that could appear to have influenced the submitted work.

References

1. Zayour M, Lazova R: Pseudoepitheliomatous hyperplasia: a review. Am J Dermatopathol. 2011, 33:112-22. 10.1097/DAD.0b013e3181fcfb47
2. Alslaim F, Al Farajat F, Alslaim HS, Drevets P, Jenkins B: Etiology and management of peristomal pseudoepitheliomatous hyperplasia. Cureus. 2021, 13:e20196. 10.7759/cureus.20196
3. Nayak VN, Uma K, Girish HC, Murgod S, Shyamala K, Naik RB: Pseudoepitheliomatous hyperplasia in oral lesions: a review. J Int Oral Health. 2015, 7:148-52.
4. Lee ES, Allen D, Scurry J: Pseudoepitheliomatous hyperplasia in lichen sclerosus of the vulva . Int J Gynecol Pathol. 2003, 22:57-62. 10.1097/00004347-200301000-00012
5. Chakrabarti S, Chakrabarti PR, Agrawal D, Somanath S: Pseudoepitheliomatous hyperplasia: a clinical entity mistaken for squamous cell carcinoma. J Cutan Aesthet Surg. 2014, 7:232-4. 10.4103/0974-2077.150787
6. Kyoung J, Caudill J, Workman L, Simman R: Dystrophic calcinosis cutis leading to a nonhealing wound in a patient with chronic venous insufficiency. Plast Reconstr Surg Glob Open. 2024, 12:e5641. 10.1097/GOX.0000000000005641
7. Wollina U, Hasenöhrl K, Köstler E, Schönlebe J, Heinig B, Haroske G, Kittner T: Dystrophic calcification in chronic leg ulcers--a clinicopathologic study. Dermatol Surg. 2009, 35:457-61. 10.1111/j.1524-4725.2009.01064.x
8. Blum FR, D'Souza LS: Cutaneous pseudoepitheliomatous hyperplasia from a displaced metallic orthopedic implant. Case Rep Dermatol Med. 2022, 2022:9139213. 10.1155/2022/9139213
9. Arulselvan M, Muthurathinam TV: Three cases of pseudoepitheliomatous hyperplasia mimicking squamous cell carcinoma of the foot: a case series. J Curr Res Sci Med. 2024, 10:124-6. 10.4103/jcrsm.jcrsm_134_23
10. Johnson DM, White LJ, Cruciani B, Gordon SV: Pseudoepitheliomatous hyperplasia: a word of caution . JSM Clin Case Rep. 2018, 6:1156.
11. Elder DE, Massi D, Scolyer RA, Willemze R: WHO Classification of Skin Tumours. IARC Press, Lyon; 2022.
12. Zhang X, Yang L, Chen Y: Pseudoepitheliomatous hyperplasia of the auricle: two case reports and experiences of reconstruction. Eur Arch Otorhinolaryngol. 2022, 279:4207-11. 10.1007/s00405-022-07453-0
13. Thorat M, Pradeep AR, Pallavi B: Primary gingival pseudoepitheliomatous hyperplasia with periodontal findings: a rare case report. J Periodontol. 2011, 82:652-5. 10.1902/jop.2010.100494
14. Xiang G, Long X, Han Q, Tian L: Giant gingival pseudoepitheliomatous hyperplasia in lung squamous cell carcinoma. J Craniofac Surg. 2012, 23:e307-8. 10.1097/SCS.0b013e3182543179
15. Raposo A, García-Purriños F, Albaladejo C, García-Solano ME, Lajara J: Pseudoepitheliomatous hyperplasia of the larynx requiring total laryngectomy. Am J Case Rep. 2018, 19:634-7. 10.12659/AJCR.909201
16. Val-Bernal JF, Rivadulla I, Garijo MF: Lingual subgemmal neurogenous plaques with pseudoepitheliomatous hyperplasia: incidental pseudomalignant condition. Pathol Int. 2006, 56:462-5. 10.1111/j.1440-1827.2006.01990.x
17. Everett JB, Falck VG, Dort JC, Matthews TW: Mandibular pseudoepitheliomatous hyperplasia following treatment for oral squamous cell carcinoma. J Otolaryngol Head Neck Surg. 2011, 40:1-4.
18. Nonomura Y, Otsuka A, Endo Y, et al.: Extranodal NK/T-cell lymphoma, nasal type, presenting pseudoepitheliomatous hyperplasia mimicking squamous cell carcinoma. Eur J Dermatol. 2012, 22:688-9. 10.1684/ejd.2012.1815
19. Joshi AA, Maddi L, Bothra N, Ali MJ: Isolated canalicular pseudoepitheliomatous hyperplasia: new disease description, Clinical Spectrum, Proposed Management, and Outcomes. Ophthalmic Plast Reconstr Surg. 2025, 41:682-7. 10.1097/IOP.0000000000002948
20. Fatima A, Matalia HP, Vemuganti GK, Honavar SG, Sangwan VS: Pseudoepitheliomatous hyperplasia mimicking ocular surface squamous neoplasia following cultivated limbal epithelium transplantation. Clin Exp Ophthalmol. 2006, 34:889-91. 10.1111/j.1442-9071.2006.01372.x
21. Mohebbi M, Ameli K, Mafi M, Bashiri A, Mahbod M: Pseudoepitheliomatous hyperplasia as a limbal mass mimicking nodular episcleritis. Korean J Ophthalmol. 2016, 30:148-9. 10.3341/kjo.2016.30.2.148
22. Doctor S, Vempuluru VS, Mishra DK, Kaliki S: Probable IgG4-related orbital disease masked by exuberant ocular surface pseudoepitheliomatous hyperplasia. Ophthalmic Plast Reconstr Surg. 2025, 41:e22-5. 10.1097/IOP.0000000000002796
23. Bothra N, Ali MJ: Punctal pseudoepitheliomatous hyperplasia mimicking a mass lesion . Orbit. 2021, 40:73-4. 10.1080/01676830.2020.1737145
24. Amsbaugh S, Huiras E, Wang NS, Wever A, Warren S: Bacillary angiomatosis associated with pseudoepitheliomatous hyperplasia. Am J Dermatopathol. 2006, 28:32-5. 10.1097/01.dad.0000154396.14971.aa
25. Fischer MK, Myer KA, Que SK, Harris JA, Martiniuk FT, Meehan SA, Levis WR: Pseudoepitheliomatous hyperplasia and transepidermal elimination in lepromatous leprosy: does T-cell plasticity play a role?. J Drugs Dermatol. 2012, 11:1232-5.
26. Kamalapirat T, Apichonbancha S, Tonaree W: Lymphocutaneous sporotrichosis complicated by pseudoepitheliomatous hyperplasia: A case report. Diagn Microbiol Infect Dis. 2025, 112:116791. 10.1016/j.diagmicrobio.2025.116791
27. Quintella LP, Cuzzi T, de Fátima Madeira M, et al.: Cutaneous leishmaniasis with pseudoepitheliomatous hyperplasia simulating squamous cell carcinoma. Am J Dermatopathol. 2011, 33:642-4. 10.1097/DAD.0b013e31820977d1
28. Meani RE, Nixon RL, O'Keefe R, Chong AH: Pseudoepitheliomatous hyperplasia secondary to allergic contact dermatitis to Grevillea Robyn Gordon. Australas J Dermatol. 2017, 58:e8-e10. 10.1111/ajd.12358

29. Parsons BF, Ryder N: Pseudoepitheliomatous hyperplasia causing a painful plaque in a HIV-infected female . Int J STD AIDS. 2017, 28:723-5. 10.1177/0956462416676020
30. Pusiol T, Zorzi MG, Morichetti D, Speziali L: Pseudoepitheliomatous hyperplasia arising from hypertrophic lichen planus mimicking squamous cell carcinoma: limited value of immunohistochemistry. Acta Dermatovenerol Croat. 2012, 20:112-4.
31. Speziali L, Pusiol T, Zorzi MG, Morichetti D, Zumiani G: Pseudoepitheliomatous hyperplasia arising from hypertrophic lichen planus mimicking squamous cell carcinoma. G Ital Dermatol Venereol. 2011, 146:310-1.
32. Ansari M, Azmoodeh Ardalan F, Najafi M, Goodarzi A, Ghanadan A: Primary cutaneous lymphoma-associated pseudoepitheliomatous hyperplasia masquerading as squamous cell carcinoma in a young adult. Acta Med Iran. 2015, 53:785-8.
33. Biswas A, Gey van Pittius D, Stephens M, Smith AG: Recurrent primary cutaneous lymphoma with florid pseudoepitheliomatous hyperplasia masquerading as squamous cell carcinoma. Histopathology. 2008, 52:755-8. 10.1111/j.1365-2559.2008.03013.x
34. Ling YH, Zhu CM, Wen SH, et al.: Pseudoepitheliomatous hyperplasia mimicking invasive squamous cell carcinoma in extranodal natural killer/T-cell lymphoma: a report of 34 cases. Histopathology. 2015, 67:404-9. 10.1111/his.12656
35. Rossi AM, Busam KJ, Mehrara B, Nehal KS: Desmoplastic trichoepithelioma with overlying pseudoepitheliomatous hyperplasia mimicking squamous cell carcinoma in a pediatric patient. Dermatol Surg. 2014, 40:477-9. 10.1111/dsu.12429
36. Shafi S, Carr DR, Chung CG: Folliculotropic mycosis fungoides with syringoid squamous metaplasia and pseudoepitheliomatous hyperplasia mimicking carcinoma: a diagnostic pitfall exacerbated by en face sectioning. Dermatol Surg. 2024, 50:971-3. 10.1097/DSS.0000000000004255
37. Vucić M, Cupić H, Tomić K, Kruslin B: An unusual pattern of pseudoepitheliomatous hyperplasia associated with cutaneous primary melanoma: report of two cases with analysis of p53 and bcl-2 immunoreactivity. Acta Dermatovenerol Croat. 2007, 15:72-5.
38. Wang T, Guo CL, Xu CC, Zhou XP, Liu YH, Zheng HY: Regional lymphomatoid papulosis in association with pseudoepitheliomatous hyperplasia: 13 years follow-up. J Eur Acad Dermatol Venereol. 2015, 29:1853-4. 10.1111/jdv.12542
39. Badavanis G, Constantinou P, Pasmatzi E, Monastirli A, Tsambaos D: Late-onset pseudoepitheliomatous hyperplasia developing within a red ink tattoo. Dermatol Online J. 2019, 25:13030.
40. Breza TS Jr, O'Brien AK, Glavin FL: Pseudoepitheliomatous hyperplasia: an unusual tattoo reaction. JAMA Dermatol. 2013, 149:630-1. 10.1001/jamadermatol.2013.2661
41. Conejero R, Conejero C, Alcalde V, García-Latasa de Araníbar J: Pseudoepitheliomatous hyperplasia: an uncommon reaction in tattoos. Actas Dermosifiliogr (Engl Ed). 2020, 111:896-7. 10.1016/j.ad.2019.03.019
42. Conti R, Bassi A, Bruscino N, Campolmi P, Cannarozzo G, Maio V, Moretti S: Pseudoepitheliomatous hyperplasia in a tattoo. G Ital Dermatol Venereol. 2017, 152:71-2. 10.23736/S0392-0488.16.04952-X
43. Cui W, McGregor DH, Stark SP, Ulusarac O, Mathur SC: Pseudoepitheliomatous hyperplasia - an unusual reaction following tattoo: report of a case and review of the literature. Int J Dermatol. 2007, 46:743-5. 10.1111/j.1365-4632.2007.03150.x
44. de Roeck A, Joujoux JM, Fournier F, Dandurand M, Meunier L, Stoebner PE: Florid pseudoepitheliomatous hyperplasia related to tattoo: a case report. Int Wound J. 2013, 10:539-41. 10.1111/j.1742-481X.2012.01013.x
45. Kiss F, May K, Piguet V: Image gallery: pseudoepitheliomatous hyperplasia, a rare tattoo reaction . Br J Dermatol. 2016, 175:e112. 10.1111/bjd.14853
46. Tammaro A, Abruzzese C, Narcisi A, et al.: Localised pseudoepitheliomatous hyperplasia: unusual cutaneous reaction pattern to tattoo. Int Wound J. 2016, 13:294-5. 10.1111/iwj.12256
47. Desimone RA, Ginter PS, Chen YT: Granular cell tumor of the breast eliciting exuberant pseudoepitheliomatous hyperplasia. Int J Surg Pathol. 2014, 22:156-7. 10.1177/1066896914525234
48. Han JS, Lee SW, Suh KH, et al.: Pseudoepitheliomatous hyperplasia mimicking esophageal squamous cell carcinoma in a patient with lye-induced esophageal stricture. Korean J Gastroenterol. 2014, 63:366-8. 10.4166/kjg.2014.63.6.366
49. Eandi JA, Asuncion A, Vandewalker KN, Javidan J: Granular cell tumor of the urinary bladder with pseudoepitheliomatous hyperplasia and colocalization with adenocarcinoma. Int J Urol. 2007, 14:862-4. 10.1111/j.1442-2042.2007.01827.x
50. Frimer M, Chudnoff S, Hebert T, Shahabi S: Pseudoepitheliomatous hyperplasia mimicking vulvar cancer in a patient with AIDS. J Low Genit Tract Dis. 2011, 15:66-8. 10.1097/LGT.0b013e3181f0b8f5
51. Tangjitgamol S, Loharamtaweethong K, Thawaramara T, Chanpanitkitchot S: Vulvar pseudoepitheliomatous hyperplasia associated with herpes simplex virus type II mimicking cancer in an immunocompromised patient. J Obstet Gynaecol Res. 2014, 40:255-8. 10.1111/jog.12129