Cureus
Part of SPRINGER NATURE

Open Access Case Report

A Rare Etiology of Peripheral Facial Paralysis in the Emergency Department: A Case Report

Esmeralda Hoxhaj [1], Antoine Baudrez [2], Céline Couvreur [3]

1. Internal Medicine, Centre Hospitalier Universitaire (CHU) Université Catholique de Louvain (UCLouvain) Namur, Godinne, BEL 2. Radiology, Centre Hospitalier Universitaire (CHU) Université Catholique de Louvain (UCLouvain) Namur, Godinne, BEL 3. Emergency Medicine, Centre Hospitalier Universitaire (CHU) Université Catholique de Louvain (UCLouvain) Namur, Godinne, BEL

Corresponding author: Esmeralda Hoxhaj , esmeralda.hoxhaj@student.uclouvain.be

Review began 07/19/2025
Review ended 08/12/2025
Published 08/14/2025

© Copyright 2025
Hoxhaj et al. This is an open access article distributed under the terms of the Creative Commons Attribution License CC-BY 4.0., which permits unrestricted use, distribution, and reproduction in any medium, provided the original author and source are credited.

DOI: 10.7759/cureus.90089

Abstract

Peripheral facial paralysis is a common reason for emergency department visits. It is distinguished from central facial paralysis by the involvement of the entire musculature of the affected hemiface. In most cases, it is benign and caused by an infection. In the emergency department, it is typically triaged as a minor emergency. However, in rare cases, it may be part of Millard-Gubler syndrome (MGS), resulting from a vascular lesion, most notably a stroke, affecting the pons. The following case describes a patient who presented with peripheral facial paralysis, later diagnosed as a pontine ischemic stroke. It aims to raise awareness among emergency physicians about the risk of prematurely dismissing peripheral facial paralysis as benign.

Categories: Neurology, Radiology, Emergency Medicine
Keywords: case report, facial nerve palsy, hemiparesis, millard-gubler syndrome, pontine infarct

Introduction

Peripheral facial paralysis is defined as a lesion of the facial nerve after its exit from the brainstem. It presents clinically as muscle weakness of the hemiface on the same side as the lesion. There are no other associated neurological deficits, and the etiology is most often benign, with a generally favorable outcome [1].

Millard-Gubler syndrome (MGS) is a crossed brainstem syndrome resulting from a lesion of the ventral part of the pons. It is characterized by ipsilateral peripheral facial paralysis (due to involvement of the facial nerve nucleus) and contralateral hemiparesis (due to involvement of the pyramidal tract crossing the pons). In most cases, it is secondary to an ischemic or hemorrhagic stroke [2].

We present here the case of a patient admitted to the emergency department for peripheral facial paralysis, in whom a central cause was revealed by imaging. This case emphasizes the critical need to recognize peripheral facial paralysis as a potentially serious symptom and to systematically assess for additional neurological deficits in the triage process.

Case Presentation

We report the case of a 59-year-old woman admitted to the emergency department for facial paralysis since awakening. Her medical history includes pulmonary embolism, dyslipidemia, obesity, depression, and former tobacco use. Her chronic medications include rosuvastatin/ezetimibe and escitalopram. Upon arrival at the emergency department, her blood pressure was 162/80 mmHg, heart rate was 83 beats per minute, oxygen saturation was 97% on room air, and blood glucose was 6.22 mmol/L. The patient was afebrile. On admission, the triage nurse noted a right peripheral facial paralysis with both the upper and lower parts of the face involved. She was triaged as a minor emergency, and blood tests, including viral serologies, were performed. However, during a more thorough neurological examination, the patient was found to have a subtle left-sided hemiparesis, with muscle strength graded as four out of five on the Medical Research Council (MRC) scale. Given this atypical clinical presentation, a brain CT scan was performed, which showed no lesion explaining the symptoms. Brain MRI, however, revealed an ischemic stroke in the inferolateral part of the pons, as seen in Figures *1*-*2*.

How to cite this article
Hoxhaj E, Baudrez A, Couvreur C (August 14, 2025) A Rare Etiology of Peripheral Facial Paralysis in the Emergency Department: A Case Report. Cureus 17(8): e90089. DOI 10.7759/cureus.90089

FIGURE 1: Brain MRI of the patient

White arrow: Hyperintense lesion on FLAIR sequence in the right inferolateral pons; FLAIR: Fluid-attenuated inversion recovery; AX: Axial; WO: Without

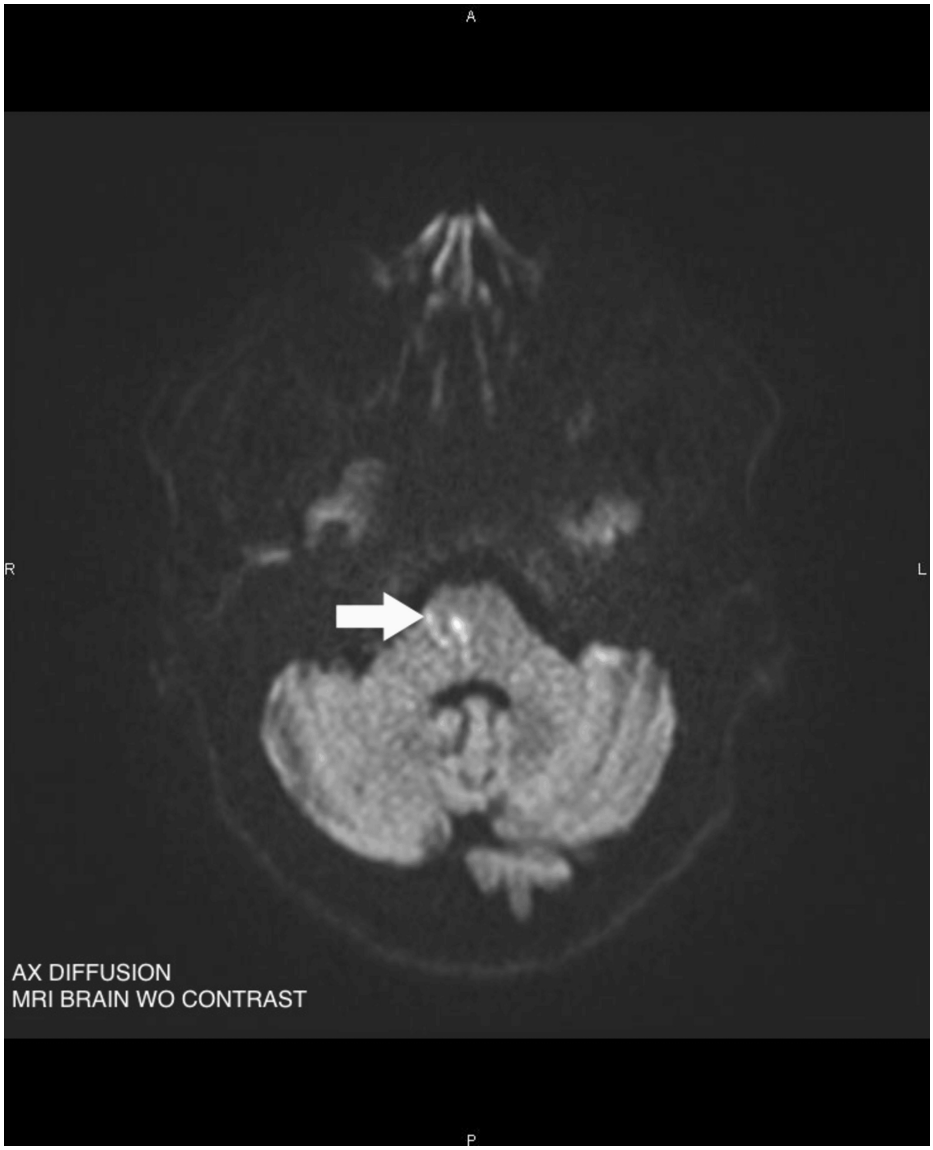

FIGURE 2: Brain MRI

White arrow: Hyperintense lesion on diffusion sequence in the right inferolateral pons; AX: Axial; WO: Without

Due to a low National Institutes of Health Stroke Scale (NIHSS) score of three, the patient was not eligible for thrombolysis. Treatment with 250 mg of intravenous aspirin and 300 mg of oral clopidogrel was initiated, and the patient was admitted to the stroke unit for management. She was able to return home a few days later while continuing rehabilitation physiotherapy sessions for persistent weakness of the left side of the body.

Discussion

When managing a facial paralysis in the emergency department, the first step is to distinguish between a central facial paralysis and a peripheral facial paralysis. Peripheral facial paralysis is due to a lower motor neuron lesion and presents as a motor deficit of all ipsilateral facial muscles on the side of the facial nerve lesion. Central facial paralysis is due to an upper motor neuron lesion and causes a motor deficit of the lower facial muscles (visible at the mouth) contralateral to the lesion in the cortex or, if the brainstem is affected, above the pons [3]. This distinction can be easily made by assessing the patient's ability to smile and to close both eyes [1]. Our patient showed involvement of both the upper and lower facial muscles, confirming peripheral facial paralysis.

The severity of peripheral facial paralysis is graded using the House-Brackmann scale [4]. The etiologies of peripheral facial paralysis are diverse, with infection being the leading cause (viral infections, including herpes, acute otitis media, and Lyme disease). Less common causes include sarcoidosis or neoplasia [1]. Treatment of peripheral facial paralysis is based on oral corticosteroids, initiated preferably within the first

three days after symptom onset. Corticosteroids improve the rate and the rapidity of motor recovery if started within 72 hours of symptom onset [5,6]. In severe cases of peripheral facial paralysis, the addition of valacyclovir to corticosteroids has demonstrated a higher rate of complete recovery [7]. However, only about 70% of patients fully regain mobility after treatment [8].

Millard-Gubler syndrome was first described in 1858 by Auguste Louis Jules Millard and Adolphe-Marie Gubler. It results from a unilateral lesion of the basal portion of the ventral pons. Clinically, it presents as an ipsilateral facial nerve (cranial nerve VII) palsy combined with involvement of the corticospinal tract in the pons above the medullary pyramidal decussation. Diagnosis is thus based on the association of peripheral facial paralysis and contralateral hemiparesis affecting both the upper and lower limbs. Foville syndrome is almost similar to MGS but also includes ipsilateral abducens nerve (cranial nerve VI) palsy as part of the core clinical picture. Given the proximity of numerous tracts to the facial nerve nucleus, MGS is often associated with additional neurological deficits such as contralateral cerebellar ataxia or contralateral hemibody paresthesias [2].

The etiology of this syndrome varies with age [2]. In younger patients, causes may include infectious conditions such as viral rhombencephalitis, tuberculosis, or neurocysticercosis [9-11]; neoplasms; demyelinating disorders like multiple sclerosis; and autoimmune conditions such as Behçet's disease. In these cases, the onset of symptoms is generally more gradual [2,12].

In older patients, cerebrovascular accidents involving the posterior circulation are the most frequent cause. These events may be hemorrhagic, such as a prepontine subarachnoid hematoma or hemorrhage secondary to a cavernous vascular malformation of the brainstem compressing pontine arterial structures [13], or ischemic, resulting from occlusion of a short circumferential branch of the basilar artery [14].

Ischemic strokes account for 85% of all strokes. Those affecting the brain stem are uncommon, accounting for approximately 7% of ischemic strokes. The incidence of other etiologies is not well documented and is primarily known from case reports [15].

A thorough history, adapted to the patient's age, is essential to guide the diagnostic approach by focusing on cardiovascular risk factors, immunodeficiency, and associated symptoms. Our patient indeed presented multiple cardiovascular risk factors, including tobacco use, obesity, and dyslipidemia. Neuroimaging remains pivotal in identifying the underlying etiology.

In the case of ischemic causes, even a delay of a few hours in diagnosis and treatment can have serious consequences for the patient's functional prognosis. To exclude or promptly treat a cerebrovascular event, any presentation suggestive of MGS warrants urgent brain imaging. In our case, while brain CT was the most accessible initial modality, it was non-diagnostic. When a brain MRI is not immediately available, a brain CT remains the first-line examination to exclude intracranial hemorrhage (a formal contraindication to thrombolysis). Brain MRI is the imaging modality of choice for diagnosis and characterization of pontine lesions [16].

In our patient's case, an NIHSS score < 4 without a significant neurological deficit did not meet the criteria for thrombolysis. Nevertheless, she received standard treatment for minor ischemic strokes not treated with thrombolysis, namely dual antiplatelet therapy [17].

Conclusions

This case underscores the importance of performing a thorough neurological and clinical examination in patients presenting with seemingly benign peripheral facial paralysis. When associated with contralateral motor deficits, the condition is consistent with MGS, typically caused by a pontine lesion, most frequently ischemic in older individuals. It mandates urgent medical evaluation and management.

Additional Information

Author Contributions

All authors have reviewed the final version to be published and agreed to be accountable for all aspects of the work.

Concept and design: Esmeralda Hoxhaj , Céline Couvreur

Acquisition, analysis, or interpretation of data: Esmeralda Hoxhaj , Antoine Baudrez

Drafting of the manuscript: Esmeralda Hoxhaj , Antoine Baudrez

Critical review of the manuscript for important intellectual content: Céline Couvreur

Supervision: Céline Couvreur

Disclosures

Human subjects: Informed consent for treatment and open access publication was obtained or waived by all participants in this study. **Conflicts of interest:** In compliance with the ICMJE uniform disclosure form, all authors declare the following: **Payment/services info:** All authors have declared that no financial support was received from any organization for the submitted work. **Financial relationships:** All authors have declared that they have no financial relationships at present or within the previous three years with any organizations that might have an interest in the submitted work. **Other relationships:** All authors have declared that there are no other relationships or activities that could appear to have influenced the submitted work.

References

1. Garro A, Nigrovic LE: Managing peripheral facial palsy . Ann Emerg Med. 2018, 71:618-624. 10.1016/j.annemergmed.2017.08.039
2. Sakuru R, Elnahry AG, Lui F, Bollu PC: Millard-Gubler Syndrome. StatPearls Publishing, Treasure Island; 2024.
3. Murthy JM, Saxena AB: Bell's palsy: treatment guidelines. Ann Indian Acad Neurol. 2011, 14:S70-S72. 10.4103/0972-2327.83092
4. House JW, Brackmann DE: Facial nerve grading system. Otolaryngol Head Neck Surg. 1985, 93:146-147. 10.1177/019459988509300202
5. Engström M, Berg T, Stjernquist-Desatnik A, et al.: Prednisolone and valaciclovir in Bell's palsy: a randomised, double-blind, placebo-controlled, multicentre trial. Lancet Neurol. 2008, 7:993-1000. 10.1016/S1474-4422(08)70221-7
6. Sullivan FM, Swan IR, Donnan PT, et al.: Early treatment with prednisolone or acyclovir in Bell's palsy . N Engl J Med. 2007, 357:1598-1607. 10.1056/NEJMoa072006
7. Hato N, Murakami S, Gyo K: Steroid and antiviral treatment for Bell's palsy. Lancet. 2008, 31:1818-1820. 10.1016/S0140-673660776-X
8. Peitersen E: Bell's palsy: the spontaneous course of 2,500 peripheral facial nerve palsies of different etiologies. Acta Otolaryngol Suppl. 2002, 4-30.
9. Prasad R, Kapoor K, Srivastava A, Mishra O: Neurocysticercosis presenting as Millard Gubler syndrome. J Neurosci Rural Pract. 2012, 3:375-377. 10.4103/0976-3147.102634
10. Talamás O, Del Brutto OH, García-Ramos G: Brain-stem tuberculoma. An analysis of 11 patients . Arch Neurol. 1989, 46:529-535. 10.1001/archneur.1989.00520410063025
11. Chakraborty U, Santra A, Pandit A, Dubey S, Chandra A: Space occupying lesion presenting as Millard-Gubler syndrome. BMJ Case Rep. 2022, 15: 10.1136/bcr-2021-248590
12. Tosunoğlu B, Çokal BG, Güneş HN, Yoldaş TK: Millard-Gubler syndrome due to parenchymal neuro-Behcet’s syndrome lesion: a rare case report. Acta Neurol Taiwan. 2024, 30:19-22.
13. Kesikburun S, Safaz I, Alaca R: Pontine cavernoma hemorrhage leading to Millard-Gubler syndrome . Am J Phys Med Rehabil. 2011, 90:263. 10.1097/PHM.0b013e3181e29e8e
14. Patel S, Bhakta A, Wortsman J, Aryal BB, Shrestha DB, Joshi T: Pontine infarct resulting in Millard-Gubler syndrome: a case report. Cureus. 2023, 15:e34869. 10.7759/cureus.34869
15. Huang J, Qiu Z, Zhou P, et al.: Topographic location of unisolated pontine infarction . BMC Neurol. 2019, 19:186. 10.1186/s12883-019-1411-6
16. Abdelrasoul AA, Elsebaie NA, Gamaleldin OA, Khalifa MH, Razek AA: Imaging of brain infarctions: beyond the usual territories. J Comput Assist Tomogr. 2019, 43:443-451. 10.1097/RCT.0000000000000865
17. Berge E, Whiteley W, Audebert H, et al.: European Stroke Organisation (ESO) guidelines on intravenous thrombolysis for acute ischaemic stroke. Eur Stroke J. 2021, 6:I-LXII. 10.1177/2396987321989865