

# A Case of Distal Nail Embedding Successfully Treated With a Slit-Tape Strap Taping Method

Takashi Seo<sup>1</sup>, Chihiro Shiya<sup>1</sup>, Hideyuki Kosumi<sup>1</sup>, Ken Muramatsu<sup>1</sup>, Hideyuki Ujiie<sup>1</sup>

<sup>1</sup>. Dermatology, Hokkaido University Hospital, Sapporo, JPN

**Corresponding author:** Chihiro Shiya, seki.to.chihiro@gmail.com

Review began 01/26/2025

Review ended 02/12/2025

Published 02/14/2025

© Copyright 2025

Seo et al. This is an open access article distributed under the terms of the Creative Commons Attribution License CC-BY 4.0., which permits unrestricted use, distribution, and reproduction in any medium, provided the original author and source are credited.

DOI: 10.7759/cureus.79018

---

---

## Abstract

Ingrown nails are a common condition, typically affecting the great toe, and are classified into lateral ingrown nails, retronychia, and distal nail embedding (DNE). DNE occurs when the nail plate's distal edge embeds into the nail fold, often following onycholysis or nail avulsion, with hypertrophy of the hyponychium obstructing nail growth. This condition causes nail discoloration, thickening, and pain, requiring treatment to restore proper nail growth. While surgical and conservative treatments are available, conservative approaches such as taping are more accessible but can be hindered by sweat or exudate. The slit-tape strap taping method, originally designed for pincer and lateral ingrown nails, provides superior adherence and longitudinal tension. We report a successful case of this method applied to a 22-year-old woman with DNE, resulting in full resolution of the condition and improvement in nail thickening after 17 months. This case highlights the slit-tape strap taping method as an easy-to-apply, noninvasive, and effective treatment for DNE.

---

**Categories:** Family/General Practice, Dermatology, Podiatry

**Keywords:** distal nail embedding, ingrown nail, onychogryphosis, slit-tape strap, taping

## Introduction

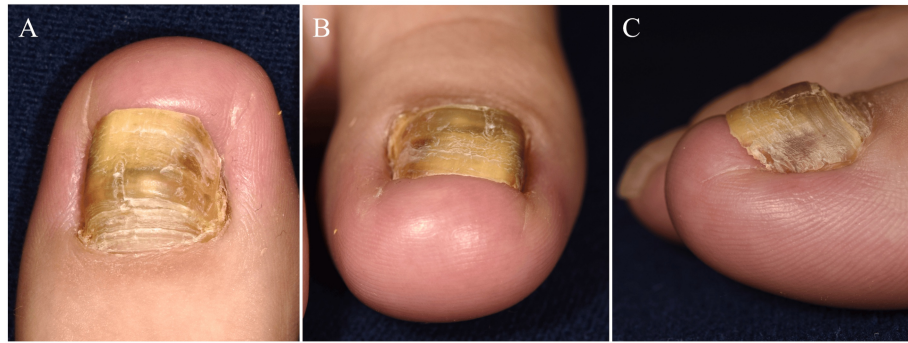
Ingrown nails are a common condition, typically affecting the great toe. They are classified into three main types: lateral ingrown nails, retronychia, and distal nail embedding (DNE). DNE occurs when the distal edge of the nail plate becomes embedded in the distal nail fold, often following onycholysis or nail avulsion, where the elevated distal nail fold obstructs nail growth. The condition is believed to be caused by hypertrophy of the hyponychium, which blocks nail elongation, leading to nail discoloration, onycholysis, and nail thickening [1,2]. Consequently, as the nail plate invaginates into the distal nail fold, pain can occur. Surgical or conservative treatments are required to release the obstruction to nail growth caused by the hyponychium [1-4]. However, surgical treatments are extremely painful, and their cure rates remain unknown. Taping is a simple, cost-effective conservative treatment; however, tapes can easily come off due to sweat or exudate from the granulation tissue, and there are no reports of improved outcomes for DNE with this method. The slit-tape strap method, which adheres the tape to the skin around the entire circumference of the nail, has been shown to remain intact even in the presence of sweat or exudate [5]. This was originally designed for pincer nails and lateral ingrown nails. Given that the tension is applied longitudinally, it is also thought to be applicable to DNE, though no reports exist. Here, we report a case of DNE successfully treated with the slit-tape strap taping method.

## Case Presentation

A 22-year-old woman visited our department complaining of pain in her right toe. One year earlier, she had developed a subungual hematoma in her right great toenail after a long walk in heeled shoes. She had been experiencing pain for two months prior to her visit but had not received any treatment. This was followed by onycholysis and nail thickening, which caused the distal edge of the nail to become painfully embedded in the tip of the great toe (Figure 1A-1C).

### How to cite this article

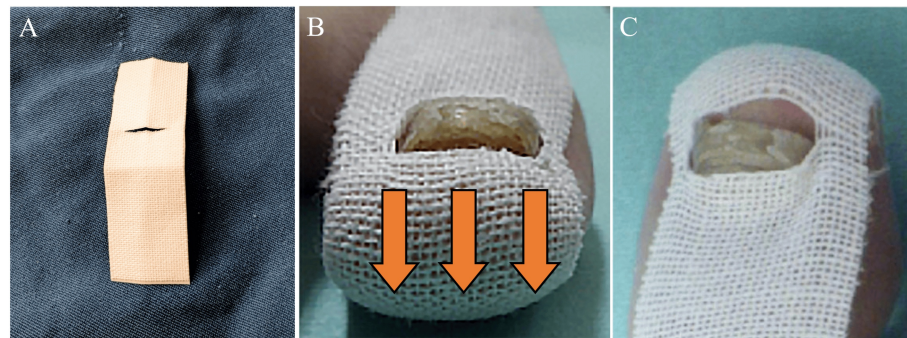
Seo T, Shiya C, Kosumi H, et al. (February 14, 2025) A Case of Distal Nail Embedding Successfully Treated With a Slit-Tape Strap Taping Method. Cureus 17(2): e79018. DOI 10.7759/cureus.79018



**FIGURE 1: Clinical presentation.**

Distal nail embedding in the right great toe. Onychogryphosis is also seen.

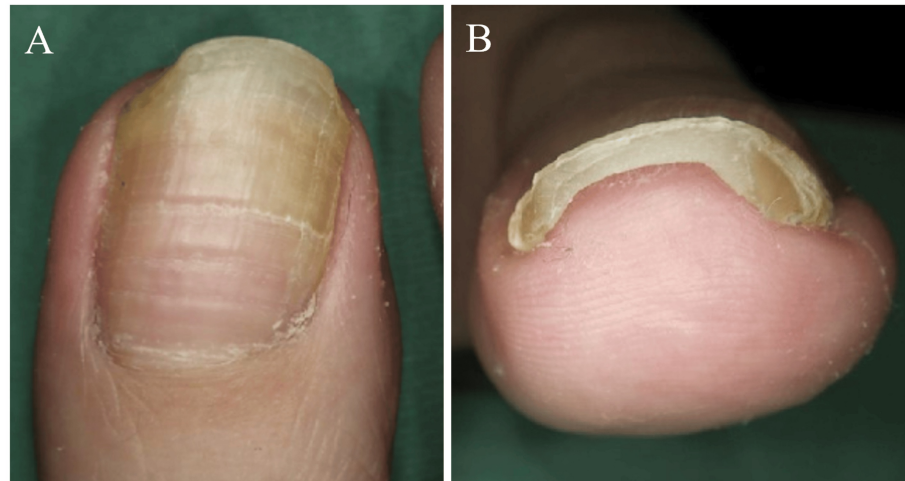
She had no sports background, was a pharmacy student, and often wore heeled shoes. Findings of direct fungal examination and fungal culture of the nail clippings were negative. She was diagnosed with DNE, with coexisting onychogryphosis. We trimmed the distal nail plate at the point of invagination into the distal nail fold and began the slit-tape strap taping (Figure 2A-2C).



**FIGURE 2: How to apply the slit-tape strap taping procedure.**

(A) First, an 8-cm-long strip of 2.5-cm-wide elastic tape, Elastic Adhesive Bandage “Silkytex” type 3 (Cat# 11892, Alcare, Japan), is cut and folded in half longitudinally. At one-third the length of the tape strap from the short edge, a slit is cut to the width of the nail. (B, C) After gently trimming her distal nail, the nail tip is set in the center of the slit with one side of the elastic tape oriented toward the dorsal side of the toe. One side of the tape is attached to the dorsal side of the toe, while the other side of the tape strap is attached to the plantar side of the toe, generating tension to draw the nail fold skin toward the plantar side (orange arrows).

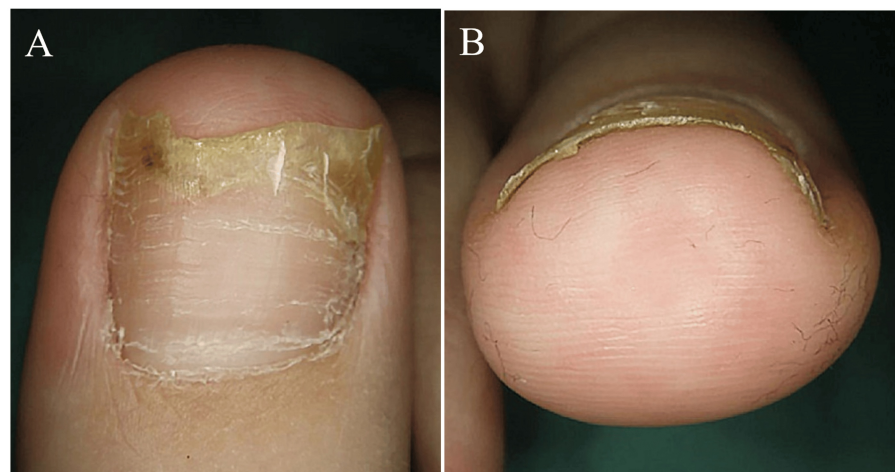
After visiting our clinic, she avoided wearing heeled shoes as much as possible and returned one month later to confirm the proper slit-tape strap taping technique. Thereafter, follow-up visits were scheduled every 2-3 months. By 10 months, the nail plate had elongated past the distal nail fold, and the DNE had fully resolved, although the nail thickening persisted (Figure 3A-3B).



**FIGURE 3: At 10 months of strip-tape strap taping.**

The distal nail embedding has improved, but nail thickening persisted.

After 17 months, the nail thickening had improved (Figure 4A-4B).



**FIGURE 4: At 17 months of treatment.**

The onycholysis and nail thickening have resolved.

## Discussion

Various methods for treating DNE have been reported [1,2,6]. However, there is no standardized approach, and different methods have been used either alone or in various combinations [1-4]. Surgical procedures can reduce the elevated distal nail fold but are highly invasive [2,3]. Moreover, even these methods do not guarantee complete restoration. As a result, less invasive treatments with more consistent success rates are highly sought after [2,6]. Conservative treatments, such as the gutter method and cotton packing, are available [2,3], but they are difficult for patients to manage independently. In contrast, taping methods are more accessible for patients to apply and manage effectively by themselves at home. Among these, the slit-tape strap taping technique is easier to apply, more stable, and less prone to peeling than other conventional taping methods [5]. It is worth noting that not only did the slit-tape strap taping method successfully treat the embedded nail, but it also improved onycholysis and nail thickening, effectively resolving the patient's onychogryphosis.

## Conclusions

We presented a case of DNE successfully treated with the slit-tape strap taping method. Overall, the results suggest that the slit-tape strap taping method may be an easy-to-apply, noninvasive, and highly effective

conservative treatment option for DNE.

## Additional Information

### Author Contributions

All authors have reviewed the final version to be published and agreed to be accountable for all aspects of the work.

**Concept and design:** Chihiro Shiiya, Takashi Seo, Hideyuki Kosumi

**Acquisition, analysis, or interpretation of data:** Chihiro Shiiya, Hideyuki Kosumi, Ken Muramatsu, Hideyuki Ujiiie

**Drafting of the manuscript:** Chihiro Shiiya, Takashi Seo, Hideyuki Kosumi

**Critical review of the manuscript for important intellectual content:** Chihiro Shiiya, Hideyuki Kosumi, Ken Muramatsu, Hideyuki Ujiiie

**Supervision:** Chihiro Shiiya, Ken Muramatsu, Hideyuki Ujiiie

### Disclosures

**Human subjects:** Consent for treatment and open access publication was obtained or waived by all participants in this study. **Conflicts of interest:** In compliance with the ICMJE uniform disclosure form, all authors declare the following: **Payment/services info:** All authors have declared that no financial support was received from any organization for the submitted work. **Financial relationships:** All authors have declared that they have no financial relationships at present or within the previous three years with any organizations that might have an interest in the submitted work. **Other relationships:** All authors have declared that there are no other relationships or activities that could appear to have influenced the submitted work.

## References

1. Haneke E: Controversies in the treatment of ingrown nails. *Dermatol Res Pract.* 2012, 2012:783924. [10.1155/2012/783924](https://doi.org/10.1155/2012/783924)
2. Dąbrowski M, Litowińska A, Cieślak J: Efficacy of a tip of the big toe remodeling in the distal nail embedding with bone overgrowth of the distal phalanx. *Ann Med Surg (Lond).* 2020, 58:160-6. [10.1016/j.amsu.2020.08.025](https://doi.org/10.1016/j.amsu.2020.08.025)
3. Kashiyama K, Nakano M, Higashi A, Ashizuka S, Moriuchi Y, Iwao A, Tanaka K: Distal nail embedding treatment using autogenous nails. *Dermatol Ther.* 2021, 34:e15163. [10.1111/dth.15163](https://doi.org/10.1111/dth.15163)
4. Gutiérrez-Mendoza D, De Anda Juárez M, Ávalos VF, Martínez GR, Domínguez-Cherit J: "Cotton nail cast": a simple solution for mild and painful lateral and distal nail embedding. *Dermatol Surg.* 2015, 41:411-4. [10.1097/DSS.000000000000294](https://doi.org/10.1097/DSS.000000000000294)
5. Watabe A, Yamasaki K, Hashimoto A, Aiba S: Retrospective evaluation of conservative treatment for 140 ingrown toenails with a novel taping procedure. *Acta Derm Venereol.* 2015, 95:822-5. [10.2340/00015555-2065](https://doi.org/10.2340/00015555-2065)
6. Thakur V, Vinay K, Haneke E: Onychocryptosis - decrypting the controversies. *Int J Dermatol.* 2020, 59:656-69. [10.1111/ijd.14769](https://doi.org/10.1111/ijd.14769)