Cureus
Part of SPRINGER NATURE

Open Access Case Report

From Prescription to Predicament: A Case of Semaglutide-Induced Discoid Lupus Erythematosus in an Adult Male Patient

Kristina Nazzicone [1], Michael Sidiropoulos [2, 3], Ashley O'Toole [4, 5, 6]

1. School of Medicine, Queen's University, Kingston, CAN 2. Department of Dermatology, University of Toronto, Toronto, CAN 3. Department of Dermatology and Pathology, Odette Cancer Centre, Sunnybrook Hospital, Toronto, CAN 4. Department of Dermatology, SKiN Centre for Dermatology, Peterborough, CAN 5. Division of Dermatology, Queen's University, Kingston, CAN 6. Department of Dermatology, Probity Medical Research, Waterloo, CAN

Corresponding author: Kristina Nazzicone, k.nazzicone@queensu.ca

Review began 01/30/2025
Review ended 03/31/2025
Published 04/03/2025

© Copyright 2025
Nazzicone et al. This is an open access article distributed under the terms of the Creative Commons Attribution License CC-BY 4.0., which permits unrestricted use, distribution, and reproduction in any medium, provided the original author and source are credited.

DOI: 10.7759/cureus.81663

Abstract

We report the case of a 30-year-old male patient who presented with a pruritic, irregular, 4x3 cm scaly purple-red plaque with surrounding papules on his lateral face, scalp, and chin after the introduction of semaglutide (Ozempic). Discoid lupus erythematosus (DLE) was suspected. A punch biopsy of a scalp lesion showed interface changes with loss of pilosebaceous units and follicular plugging, findings consistent with DLE. A complete blood count, antinuclear antibody (ANA), anti-double stranded DNA (dsDNA), and extractable nuclear antigen (ENA) panel was quantified along with erythrocyte sedimentation rate (ESR), C-reactive protein (CRP), complement levels, creatinine, and glomerular filtration rate, ruling out systemic lupus erythematosus (SLE). The patient's condition improved with drug discontinuation as well as topical treatment, including tacrolimus 0.1% ointment and clobetasol lotion. Hydroxychloroquine 200 mg daily was trialed but discontinued due to the patient's concerns about ocular side effects. Follow-up after four months showed improvement, with less scale and erythema. Although semaglutide has been widely used for glycemic control and weight loss, cutaneous adverse effects are seldom reported. This case highlights the potential for drug-induced cutaneous lupus erythematosus (DICLE) associated with immune-modulating medications such as semaglutide, a glucagon-like peptide-1 receptor agonist (GLP-1 RA).

Categories: Dermatology
Keywords: case report, cutaneous lupus erythematosus, discoid lupus erythematosus (dle), glp-1 receptor agonist, semaglutide

Introduction

Discoid lupus erythematosus (DLE) is the most common form of chronic cutaneous lupus erythematosus (CCLE), typically affecting women of childbearing age [1,2]. Discoid lupus erythematosus usually presents in sun-exposed areas such as the face, ears, and scalp and poses a high risk of morbidity due to its potential for skin atrophy and scarring [1,3]. The pathophysiology of drug-induced lupus erythematosus (DILE) is incompletely understood yet thought to involve a preexposing genetic or epigenetic susceptibility, instigated as a result of drug biotransformation [4]. Discoid lupus erythematosus is often associated with systemic lupus erythematosus (SLE), as up to 20% of patients with DLE may develop systemic involvement over time. Certain medications, including proton pump inhibitors, hydralazine, and procainamide, have been reported to trigger cutaneous and systemic lupus erythematosus, although no reports of semaglutide-induced DLE have been reported to date [5]. Glucagon-like peptide-1 receptor agonists (GLP-1 RAs), such as semaglutide, are increasingly used for the treatment of type 2 diabetes and obesity, providing metabolic and cardiovascular benefits [6]. The immunomodulating properties of these compounds have also been investigated for their potential to treat or potentiate autoimmune disease [7,8]. Here, we present a case of possible DLE following the initiation of semaglutide (Ozempic) in an adult male patient.

Case Presentation

A 30-year-old male patient presented to primary care regarding an irregular 4×3 cm scaly and erythematous plaque with surrounding papules on the chin and associated pruritus (Figure *1*). The patient first noticed the eruption a few months prior, approximately one week after the initiation of semaglutide (Ozempic) for weight loss. After its initial onset, the lesion grew in size and severity for approximately three weeks before reaching its final presentation. Mupirocin ointment and metronidazole were trialed by the family physician prior to referral, with metronidazole showing moderate success in reducing erythema. The referral stated that fungal scraping was negative, and no other cutaneous or systemic signs or symptoms were reported. Apart from obesity, the patient's medical history was unremarkable; however, both parents had a history of inflammatory bowel disease. The patient discontinued the semaglutide.

How to cite this article
Nazzicone K, Sidiropoulos M, O'Toole A (April 03, 2025) From Prescription to Predicament: A Case of Semaglutide-Induced Discoid Lupus Erythematosus in an Adult Male Patient. Cureus 17(4): e81663. DOI 10.7759/cureus.81663

FIGURE 1: Initial presentation of an irregular, 4x3 cm, scaly, thin, purple-red plaque with surrounding papules on the right chin and upper neck.

When seen by dermatology, examination revealed erythematous, scaly papules and plaques on the chin, peri-auricular area, and scalp, raising suspicion for localized DLE. The lack of response to mupirocin and metronidazole made infectious causes less likely, prompting further evaluation for autoimmune or drug-induced etiologies. A punch biopsy of the left scalp lesion was performed, and a complete blood count was requested along with antibody titers of double-stranded DNA (dsDNA), antinuclear antibodies (ANA), and an extractable nuclear antigen (ENA) panel. Erythrocyte sedimentation rate (ESR), C-reactive protein (CRP), complement levels, alanine transaminase (ALT), alkaline phosphatase (ALP), creatinine, and glomerular filtration rate were also quantified to assess for systemic disease (Table *1*). The patient was prescribed topical tacrolimus 0.1% twice daily to the face and topical clobetasol lotion to the scalp and ears while awaiting results.

Parameters	Patient values	Reference range
White blood cells (WBC)	6.5 × 10^9/L	4.0 – 11.0 × 10^9/L
Red blood cells (RBC)	5.24 × 10^{12}/L	4.50 – 6.00 × 10^{12}/L
Hemoglobin (HGB)	159 g/L	135 – 175 g/L
Hematocrit (HCT)	0.459 L/L	0.400 – 0.500 L/L
Mean corpuscular volume (MCV)	88 fL	80 – 100 fL
Mean corpuscular hemoglobin (MCH)	30.3 pg	27.5 – 33.0 pg
Mean corpuscular hemoglobin concentration (MCHC)	346 g/L	305 – 360 g/L
Red cell distribution width (RDW)	12.3 %	11.5 – 14.5 %
Platelet count	302 × 10^9/L	150 – 400 × 10^9/L
Neutrophils	3.3 × 10^9/L	2.0 – 7.5 × 10^9/L
Lymphocytes	2.4 × 10^9/L	1.0 – 3.5 × 10^9/L
Monocytes	0.6 × 10^9/L	0.2 – 1.0 × 10^9/L
Eosinophils	0.2 × 10^9/L	0.0 – 0.5 × 10^9/L
Basophils	0.0 × 10^9/L	0.0 – 0.2 × 10^9/L
Immature granulocytes	0.0 × 10^9/L	0.0 – 0.1 × 10^9/L
Nucleated red blood cells (NRBC)	0/100 WBC	0/100 WBC
Double-stranded DNA (dsDNA)	<1 IU/mL	<5 IU/mL
Antinuclear antibody (ANA)	Negative	Negative at 1:80 titre
Extractable nuclear antigen (ENA) panel	Negative	Positive at any quantity
Erythrocyte sedimentation rate (ESR)	2 mm/hr	2-30 mm/hr
C-reactive protein (CRP)	3.3 mg/L	<5.0 mg/L
Complement C3	1.77 g/L	0.9-1.8 g/L
Complement C4	0.3 g/L	0.15-0.53 g/L
Creatinine	82 umol/L	67-117 umol/L
Estimated glomerular filtration rate (eGFR)	110 mL/min/1.73m2	>90 mL/min/1.73m2
Alkaline phosphatase (ALP)	103 U/L	40-129 U/L
Alanine transaminase (ALT)	**99 U/L**	<50 U/L

TABLE 1: An overview of the patient's laboratory investigation findings.

Abnormal value is indicated in bold. The extractable nuclear antigen (ENA) panel includes anti-SS-A, anti-SS-B, anti-RNP, anti-Sm, anti-Scl-70, anti-Jo-1.

Pathology demonstrated an interface process with a superficial lymphoid infiltrate and basal cell layer vacuolar degeneration with necrotic keratinocytes. A periadnexal and perivascular infiltrate with significant loss of pilo-sebaceous units and follicular plugging was also noted (Figures *2A*, *2B*). A colloidal iron stain showed dermal mucin (Figure *2C*). Basement membrane thickening was demonstrated by periodic acid-Schiff (PAS) and PAS-diastase (PAS-D) stains. All the above-stated bloodwork was within normal limits apart from slightly elevated ALT at 99 U/L. The remainder of the investigations were negative, ruling out comorbid SLE. Hydroxychloroquine (Plaquenil) 200mg was initiated along with the continuation of topical medications. At the four-month follow-up, hydroxychloroquine was discontinued due to patient concerns about ocular side effects, and clobetasol was mildly successful at relieving pruritus. The skin was improved with less scale and erythema (Figure *3*). The patient remains off the semaglutide yet continues to have residual scarring and post-inflammatory hyperpigmentation.

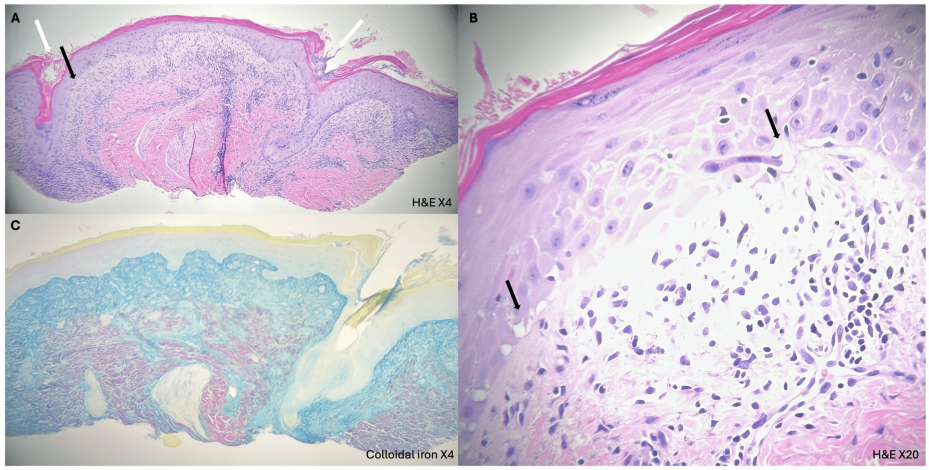

FIGURE 2: Histopathology of left scalp biopsy

(A) Hematoxylin and eosin (H&E) stained section (X4) showing vacuolar interface inflammation (black arrows), follicular plugging (white arrows), and perifollicular and periadnexal inflammation; (B) H&E-stained section (X20) showing similar vacuolar interface inflammation (black arrows); (C) Colloidal iron stain (X4) showing significant mucin deposits. Significant loss of pilosebaceous units is also noted.

FIGURE 3: Right chin and neck lesions four months after the initiation of topical tacrolimus 0.1% and clobetasol lotion; scale and erythema are improved, but residual hyperpigmentation and erythema can be appreciated.

Discussion

Drug-induced cutaneous lupus erythematosus (DICLE) is a cutaneous lupus variant occurring days to years following exposure to a culprit drug in those without a history of autoimmune disease [4,9]. A diagnosis of DICLE is usually made according to the clinical plausibility of the temporal relationship between the eruption and initiation of a new medication, physical examination, serology, and lesion biopsy [4]. Histopathology of discoid lesions demonstrates periadnexal inflammation, hyperkeratosis, follicular plugging, and interface dermatitis (i.e., basal cell damage). Dermal mucin deposits and basement membrane

thickening can also be appreciated [10]. Discontinuation of the culprit medication should be the first step in the management of all forms of DILE, as manifestations usually subside following the removal of the offending agent. Patients presenting with DICLE should also be evaluated for SLE at diagnosis and in the ensuing weeks to months [4].

Semaglutide is a GLP-1 RA widely used for the management of type 2 diabetes and weight loss. These incretin mimetics function to augment the actions of insulin, inhibit those of glucagon, and decrease gastric emptying, mimicking the actions of endogenous GLP-1 released from gut neuroendocrine cells [6]. The most commonly reported side effects of GLP-1 RAs are gastrointestinal, with 10% to 50% of patients experiencing nausea, vomiting, and diarrhea. Given the recent surge in popularity of this compound, its potential cutaneous adverse events are still being elucidated [11].

Emerging evidence suggests GLP-1 RAs might act to dampen the effects of the immune system through pathways independent from those promoting weight loss and glycemic control. Recent retrospective data have shown a modest but statistically significant reduction in the incidence of systemic inflammatory diseases, including SLE, among those using GLP-1 RAs [12]. GLP-1 RAs have been shown to inhibit the secretion of IFN-gamma and IL-4 by invariant natural killer T (iNKT) cells, which are key mediators between the innate and adaptive immune systems. These cytokine alterations have primarily been linked to psoriasis and have demonstrated dose-dependent benefits on disease severity [13].

A recent study found a positive association between genetically proxied GLP-1 receptor activation and an increased risk of developing SLE [7]. GLP-1 RAs have been shown to increase double-negative B cells, a subpopulation of B cells frequently implicated in autoimmune diseases, including SLE. These findings might provide a plausible mechanism to support how GLP-1 RAs may contribute to an increased risk of developing SLE or exacerbate preexisting autoimmune disease [7].

The pathophysiology of DICLE is not fully understood but is thought to involve genetic, epigenetic, and pharmacokinetic involvement [4]. Similar to idiopathic CCLE, both human leukocyte antigen (HLA) variants and alterations to key players in the complement cascade have been suggested as plausible mechanisms; however, findings across studies are not always consistent nor meant to represent definitive consensus [4,8]. Over 40 medications have been reported as probable culprits for DILE, several of which belong to a class of immunomodulating medications [14].

A case of DILE caused by semaglutide (Wegovy) was published less than a year ago [15]. The patient presented with diffuse petechial rash in the lower extremities and abdomen but did not appear to show signs of DLE. As of March 15, 2025, 60 prescriber and user reports of skin and subcutaneous tissue adverse events occurring in patients using semaglutide have been submitted to Health Canada [16]. This number is much higher at 3,271 events in the United States, according to Food and Drug Agency (FDA) data [17]. Unsurprisingly, most of these reports were filed in the last decade. Neither database reported on semaglutide-induced DLE explicitly; however, descriptions of skin atrophy and pigmentation changes can be appreciated, and a single case of “lupus-like syndrome” was reported to the FDA in November 2024. It is unclear if this case represents systemic or cutaneous lupus [17].

Conclusions

To our knowledge, this study reports a potential case of semaglutide-induced DLE in a young adult male patient. Given the proven efficacy of GLP-1 RAs in treating obesity and diabetes and their potential for further therapeutic development, the number of patients who will be prescribed this medication is likely to increase. Further research and post-market surveillance, including dermatologic monitoring, are needed to better characterize the mechanism of semaglutide-induced DLE.

Additional Information

Author Contributions

All authors have reviewed the final version to be published and agreed to be accountable for all aspects of the work.

Concept and design: Kristina Nazzicone, Ashley O'Toole

Acquisition, analysis, or interpretation of data: Kristina Nazzicone, Ashley O'Toole, Michael Sidiropoulos

Drafting of the manuscript: Kristina Nazzicone

Critical review of the manuscript for important intellectual content: Ashley O'Toole, Michael Sidiropoulos

Supervision: Ashley O'Toole

Disclosures

Human subjects: Consent for treatment and open access publication was obtained or waived by all participants in this study. **Conflicts of interest:** In compliance with the ICMJE uniform disclosure form, all authors declare the following: **Payment/services info:** All authors have declared that no financial support was received from any organization for the submitted work. **Financial relationships:** All authors have declared that they have no financial relationships at present or within the previous three years with any organizations that might have an interest in the submitted work. **Other relationships:** All authors have declared that there are no other relationships or activities that could appear to have influenced the submitted work.

Acknowledgements

We thank the patient for allowing us to share their case.

References

1. Izmirly P, Buyon J, Belmont HM, et al.: Population-based prevalence and incidence estimates of primary discoid lupus erythematosus from the Manhattan Lupus Surveillance Program. Lupus Sci Med. 2019, 6:e000344. 10.1136/lupus-2019-000344
2. Fabbri P, Cardinali C, Giomi B, Caproni M: Cutaneous lupus erythematosus: diagnosis and management. Am J Clin Dermatol. 2003, 4:449-65. 10.2165/00128071-200304070-00002
3. Jessop S, Whitelaw DA, Grainge MJ, Jayasekera P: Drugs for discoid lupus erythematosus. Cochrane Database Syst Rev. 2017, 5:CD002954. 10.1002/14651858.CD002954.pub3
4. He Y, Sawalha AH: Drug-induced lupus erythematosus: an update on drugs and mechanisms . Curr Opin Rheumatol. 2018, 30:490-7. 10.1097/BOR.0000000000000522
5. Szczęch J, Samotij D, Werth VP, Reich A: Trigger factors of cutaneous lupus erythematosus: a review of current literature. Lupus. 2017, 26:791-807. 10.1177/0961203317691369
6. Drucker DJ: Mechanisms of action and therapeutic application of glucagon-like peptide-1 . Cell Metab. 2018, 27:740-56. 10.1016/j.cmet.2018.03.001
7. Sun Y, Zhou Q, Onzere LE, et al.: Evaluating the causal effect of using glucagon-like peptide-1 receptor agonists on the risk of autoimmune diseases. Diabetes Metab Syndr. 2025, 19:103186. 10.1016/j.dsx.2025.103186
8. Achtman JC, Werth VP: Pathophysiology of cutaneous lupus erythematosus. Arthritis Res Ther. 2015, 17:182. 10.1186/s13075-015-0706-2
9. Drug-induced lupus erythematosus. (2020). Accessed: October 28, 2024: https://emedicine.medscape.com/article/1065086-overview.
10. McDaniel B, Sukumaran S, Koritala T, Tanner LS: Discoid Lupus Erythematosus. StatPearls [Internet], StatPearls Publishing, Treasure Island, FL; 2025.
11. Salazar CE, Patil MK, Aihie O, Cruz N, Nambudiri VE: Rare cutaneous adverse reactions associated with GLP-1 agonists: a review of the published literature. Arch Dermatol Res. 2024, 316:248. 10.1007/s00403-024-02969-3
12. Nassar M, Nassar O, Abosheaishaa H, Misra A: Comparative outcomes of systemic diseases in people with type 2 diabetes, or obesity alone treated with and without GLP-1 receptor agonists: a retrospective cohort study from the Global Collaborative Network: author list. J Endocrinol Invest. 2025, 48:483-97. 10.1007/s40618-024-02466-4
13. Hogan AE, Tobin AM, Ahern T, et al.: Glucagon-like peptide-1 (GLP-1) and the regulation of human invariant natural killer T cells: lessons from obesity, diabetes and psoriasis. Diabetologia. 2011, 54:2745-54. 10.1007/s00125-011-2232-3
14. Borucki R, Werth VP: Cutaneous lupus erythematosus induced by drugs - novel insights . Expert Rev Clin Pharmacol. 2020, 13:35-42. 10.1080/17512433.2020.1698290
15. Castellanos V, Workneh H, Malik A, Mehta B: Semaglutide-induced lupus erythematosus with multiorgan involvement. Cureus. 2024, 16:e55324. 10.7759/cureus.55324
16. Canada Vigilance Adverse Reaction Online Database. (2019). Accessed: October 28, 2024: https://cvp-pcv.hc-sc.gc.ca/arq-rei/.
17. FDA Adverse Events Reporting System (FAERS) public dashboard. (2024). Accessed: October 28, 2024: https://fis.fda.gov/sense/app/95239e26-e0be-42d9-a960-9a5f7f1c25ee/sheet/7a47a261-d58b-4203-a8aa-6d3021737452/state/a....