

Fever of Unknown Origin: A Rare Diagnosis Requiring High Suspicion

Beatriz R. Marques¹, Filipa Seixas², Mariana Nunes¹, Sofia L. Costa³, Victor Paz¹

Review began 11/27/2024

Review ended 12/06/2024

Published 12/08/2024

© Copyright 2024

Marques et al. This is an open access article distributed under the terms of the Creative Commons Attribution License CC-BY 4.0., which permits unrestricted use, distribution, and reproduction in any medium, provided the original author and source are credited.

DOI: 10.7759/cureus.75330

1. Internal Medicine, Unidade Local de Saúde de Trás-os-Montes e Alto Douro, Chaves, PRT 2. Hematology, Unidade Local de Saúde Trás-os-Montes e Alto Douro, Vila Real, PRT 3. Pathology, Unidade Local de Saúde Trás-os-Montes e Alto Douro, Vila Real, PRT

Corresponding author: Beatriz R. Marques, beatrizriquito@gmail.com

Abstract

Fever is a classic reason for hospital visits, sometimes requiring admission. Its etiologies are numerous, ranging from simple and relatively common conditions to rare and complex pathologies, for which the differential diagnosis can present a true challenge for internists. A 78-year-old healthy female is referred to the emergency department due to marked fatigue for the past four months, with no other symptoms. Physical examination revealed fever, significant lower limb edema, and low blood pressure. Laboratory results revealed anemia and thrombocytopenia, associated with high ferritin and lactate dehydrogenase levels (1924 U/L and 1519 U/L, respectively) and mild hyponatremia (133 mEq/L). A thoracic-abdominal-pelvic CT scan showed only a splenomegaly of 17 cm without other significant findings. No microorganisms were found in multiple cultural samples, and fever persisted despite two courses of antibiotics. Viral serologies and zoonosis panel were negative. A bone marrow study was conducted to help explain the cytopenias, which revealed hemophagocytic cells, confirming the diagnosis of hemophagocytic syndrome. She started with systemic corticosteroid therapy, which improved her symptoms, and a few days later, it was confirmed a diffuse large B-cell lymphoma was the etiology. Because of its mostly unspecific manifestations, hemophagocytic syndrome requires a high degree of suspicion for timely diagnosis and treatment.

Categories: Internal Medicine, Infectious Disease, Hematology

Keywords: fever of unknown origin, hemophagocytic lymphohistiocytosis, hemophagocytic syndrome, hyperferritinemia, undiagnosed fever

Introduction

Fever has preoccupied physicians since the earliest days of clinical medicine. Fever is a classic reason for hospital visits, has been scrutinized in recent decades, and remains a major diagnostic challenge. Its etiologies are numerous, ranging from simple and relatively common conditions to rare and complex pathologies with very different prognostic outcomes, for which the differential diagnosis can present a true challenge for internists [1]. A fever of unknown origin is defined as a temperature $>38.3^{\circ}\text{C}$ recorded several times for >3 weeks despite appropriate initial inpatient or outpatient evaluation [2]. Constant re-evaluation of clinical data is essential considering the dynamic changes in disease patterns.

The authors present a clinical case of a prolonged fever subjected to extended investigation, leading to a diagnosis of hemophagocytic lymphohistiocytosis (HLH) caused by lymphoma. This syndrome is a rare condition characterized by excessive immune system activation. It more commonly affects children but can occur at any age [3]. This case report aims to alert other physicians to this rare disease, which can be potentially fatal if not treated in time.

Case Presentation

A 78-year-old female, a former tailor with a known medical history of hypertension, dyslipidemia, and vertiginous syndrome, presents to the emergency department due to marked fatigue for the past four months. No respiratory, cardiac, genitourinary, or neurological symptoms were reported. The patient lived in an urban environment with potable water, denied consuming raw milk or raw milk products, and had no contact with animals. On examination, she presented with fever, significant lower limb edema, and arterial pressure of 96/55 mmHg without other noticeable findings. Laboratory results revealed severe microcytic anemia, thrombocytopenia, elevated lactate dehydrogenase (LDH), no hepatic cytolysis, and normal renal function. The patient reported no blood losses. She was admitted to the internal medicine ward for further investigation. The initial blood findings are shown in Table 1.

How to cite this article

Marques B R, Seixas F, Nunes M, et al. (December 08, 2024) Fever of Unknown Origin: A Rare Diagnosis Requiring High Suspicion. Cureus 16(12): e75330. DOI 10.7759/cureus.75330

Parameter	Result	Reference Value
Hemoglobin	7.3	12-16 g/dL
MCV	78.0	87-103 fL
Leucocyte count	6790	4-11 x 10 ³ /uL
Platelets	94000	150-400 x 10 ³ /uL
Urea/creatinine	40/1.0	<50/0.5-0.9 mg/dL
Sodium/Potassium	133/3.9	135-147/3.7-5.1 mEq/L
AST	38	<35 U/L
ALT	17	<33 U/L
γ-GT	9	7-32 U/L
Alkaline Phosphatase	46	35-105 U/L
Total Bilirubin	0.5	<1.2 mg/dL
Lactate Dehydrogenase	1519	135-214 U/L
INR	1.4	<1.2
aPTT	31.5	27-38 seg
C Reactive Protein	6.32	<0.5 mg/dL

TABLE 1: Analytic study at admission

aPTT: Activated partial thromboplastin time; ALT: Alanine transaminase; AST: Aspartate transaminase; INR: International normalised ratio; MCV: Mean corpuscular volume; γ-GT: Gamma-glutamyl transferase

The chest radiography was normal (Figure 1), as well as the electrocardiogram (Figure 2). A full-body computed tomography (CT) was performed, showing mild hepatic steatosis and an enlarged spleen (17.1 cm) without any other features worth mentioning (Figure 3).

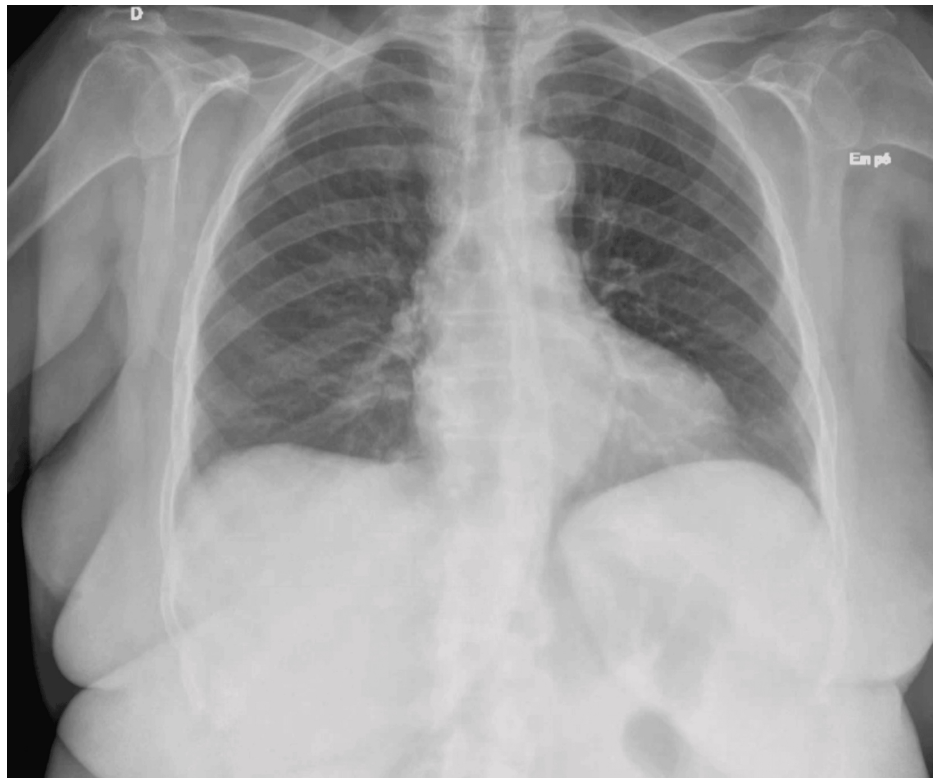


FIGURE 1: Chest radiography at admission

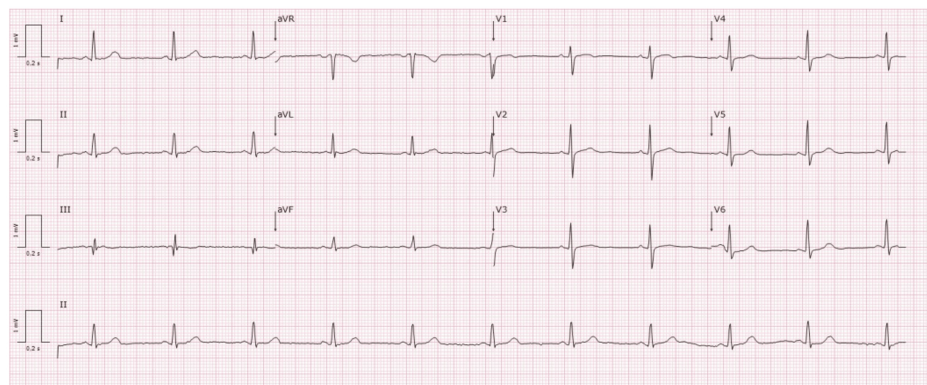


FIGURE 2: Electrocardiogram at admission

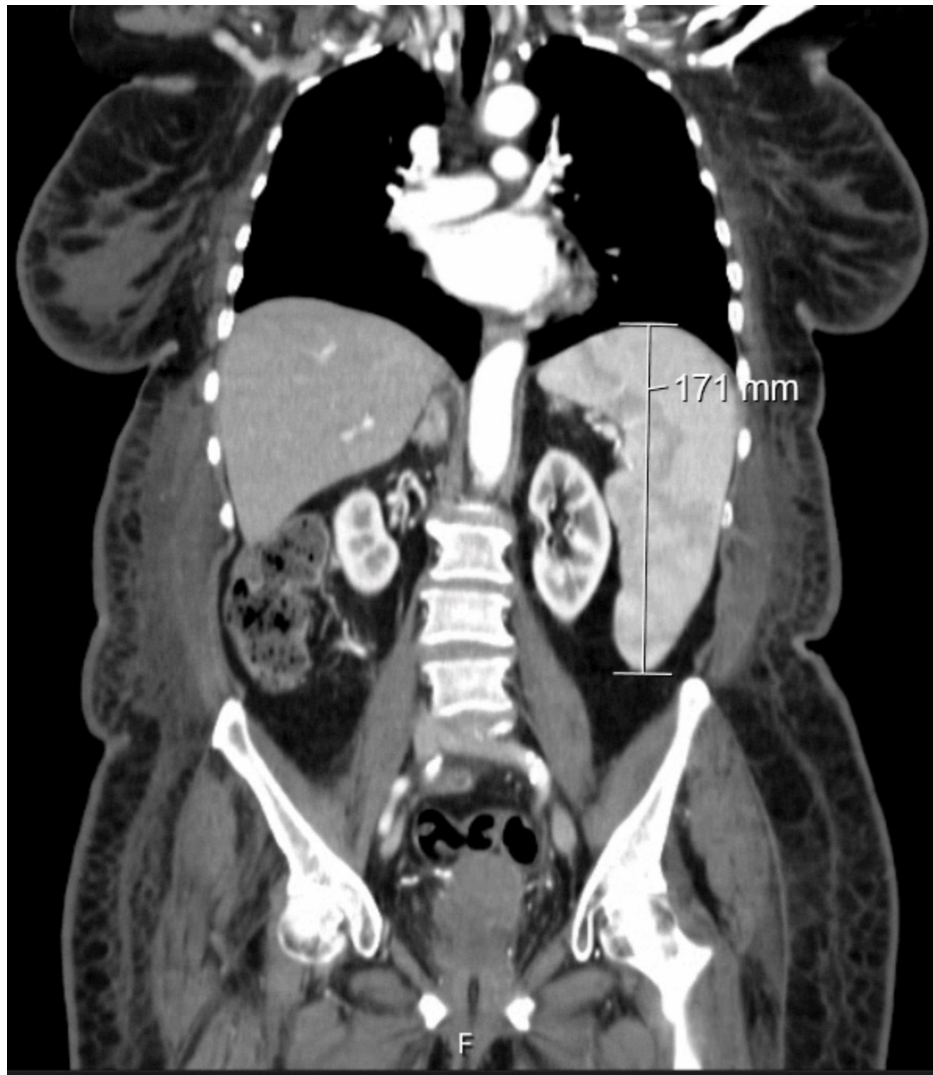

FIGURE 3: Computed tomography showing an enlarged spleen

She was submitted to an upper digestive endoscopy, which revealed severe reflux esophagitis (grade D) affecting 75% of the esophagus circumference (Figure 4). The colonoscopy did not show any suspicious lesions.

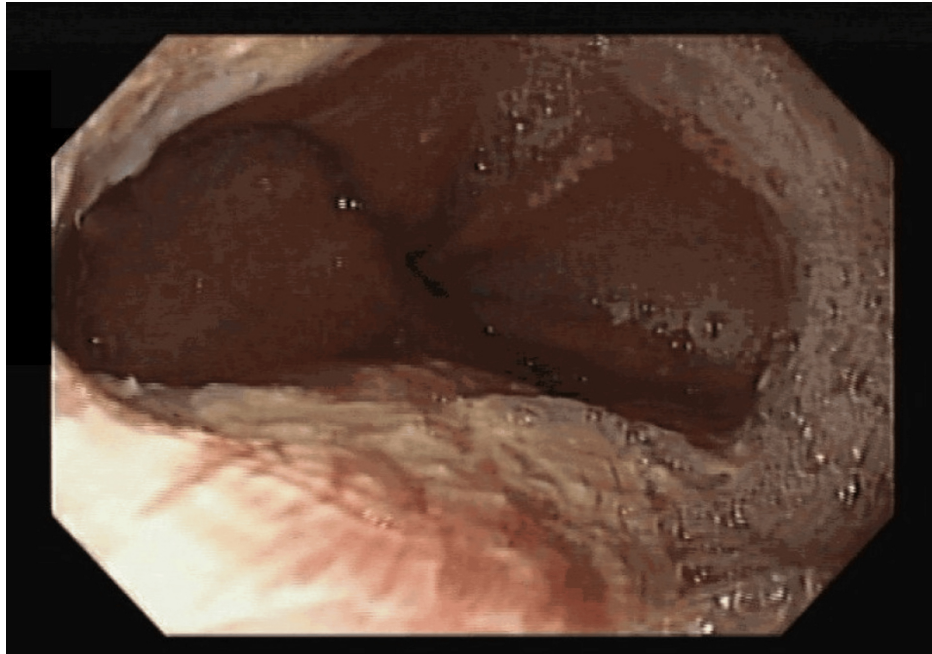


FIGURE 4: Severe reflux esophagitis (grade D)

An extended analytic study was performed to understand the cause of anemia, thrombocytopenia, and constitutional syndrome (Table 2). Whenever necessary, the patient was transfused with erythrocytes.

Parameter	Result	Reference Value
Reticulocytes	0.105	0.025-0.090 x 10 ¹²
Blood smear	Poikilocytosis	-
Serum Iron	18	37-145 ug/mL
TIBC	160	228-360 mg/dL
Transferrin saturation	10.1	>20%
Serum Ferritin	1924	15-150 ng/mL
Folic acid	2.9	2.2-17.5 ng/mL
Vitamin B12	387.9	191-663 pg/mL
Haptoglobin	154	30-200 mg/dL
TSH	1.89	0.27-4.2 mIU/L
T4	7.72	8.2-21 pmol/L
Serum Albumin	2.9	3.4-4.8 g/dL
Serum Total Proteins	5.2	6.6-8.7 g/dL
Protein electrophoresis	Normal	-
IgG/IgM/IgA	All normal	-
24h urine Proteins	159	<150 mg/24h
Uric acid	5.8	2.3-5.7 mg/dL
ESR 1 st hour	65	0-30 mm/1 st h
Fibrinogen	406	200-400 mg/dL
Anti-dsDNA antibodies	<1:10	<1:10
ANCA's	<1:20	<1:20
ANA's	Negative	-
Anti-phospholipid antibodies	Negative	-
Anti-CCP antibody	Negative	-
Anti-PR3 antibodies	Negative	-
Complement proteins	100/14	90-180/12-36 mg/dL
Serum Triglycerides	320	<150 mg/dL

TABLE 2: Extended analytic study

Anti-dsDNA: Anti-double stranded deoxyribonucleic acid; ANA: Antinuclear antibodies; ANCA: Antineutrophil cytoplasmic antibodies; Anti-CCP: Anti-cyclic citrullinated peptide; Anti-PR3: Anti-proteinase 3; ESR: Erythrocyte sedimentation rate; Ig: Immunoglobulin; TIBC: Total iron binding capacity; TSH: Thyroid-stimulating hormone; T4: Thyroxine

The patient was started on empiric antibiotics with ceftriaxone, and several exams were conducted to find the source of the fever. The transthoracic echocardiogram did not show signs of endocarditis. Table 3 shows the microbiology and serology results.

Parameter	Result	Parameter	Result
Blood cultures (2 nd day)	Negative	CMV antibodies IgG/IgM	Positive/Negative
Blood cultures (8 th day)	Negative	EBV antibodies IgG/IgM	Positive/Negative
Blood cultures (17 th day)	Negative	<i>Chlamydia trachomatis</i> IgG/IgM	Negative/Negative
Urine sediment	Normal	Wright Reaction	Negative
Urine culture	Negative	Rose Bengal	Negative
Respiratory virus panel	Negative	<i>Coxiella Burnetti</i> antibodies IgG/IgM	Positive/Negative
HBV antibodies	Non-reactive	<i>Mycoplasma pneumoniae</i> antibodies IgG/IgM	Negative/Negative
HBV HBs antigen	Non-reactive	<i>Rickettsia spp</i> antibodies IgG/IgM	Negative/Negative
HCV antibody	Non-reactive	<i>Parvovirus</i> antibodies IgG/IgM	Negative/Negative
HIV antibody	Non-reactive	Zoonoses Panel	Negative

TABLE 3: Analytic results in search of an infectious agent

:CMV: Cytomegalovirus; EBV: Epstein-Barr virus; HBV: Hepatitis B virus; HCV: Hepatitis C virus; HIV: Human immunodeficient virus; Ig: Immunoglobulin

The fever persisted after three weeks of exams, two cycles of antibiotics, and no microbiologic isolate. High ferritin levels associated with fever, anemia, and thrombocytopenia, with no other explanation, started to raise suspicions of hemophagocytic syndrome, so serum fibrinogen and serum triglycerides were measured (Table 2). Finally, on the 20th day, a bone marrow study (with bone marrow biopsy) revealed hemophagocytic cells (Figure 5), confirming the diagnosis of hemophagocytic syndrome, and systemic corticosteroid therapy was initiated.

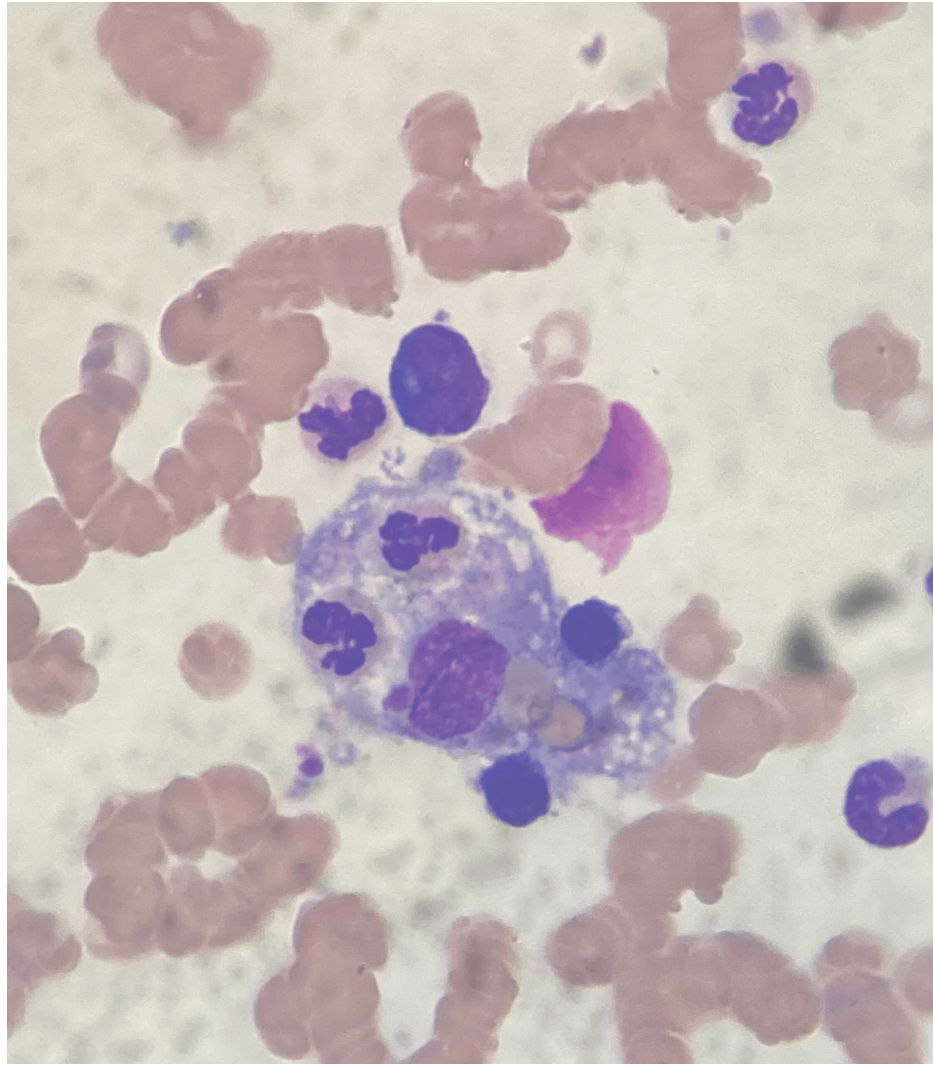


FIGURE 5: Macrophage phagocytosing cellular elements

This confirmed the diagnosis, fulfilling 6 out of 8 criteria of the revised diagnostic guidelines for HLH-2004 [4]. Figures 6-7 show the evolution of the hyperthermia and some laboratory parameters, respectively, during four weeks of hospitalization.

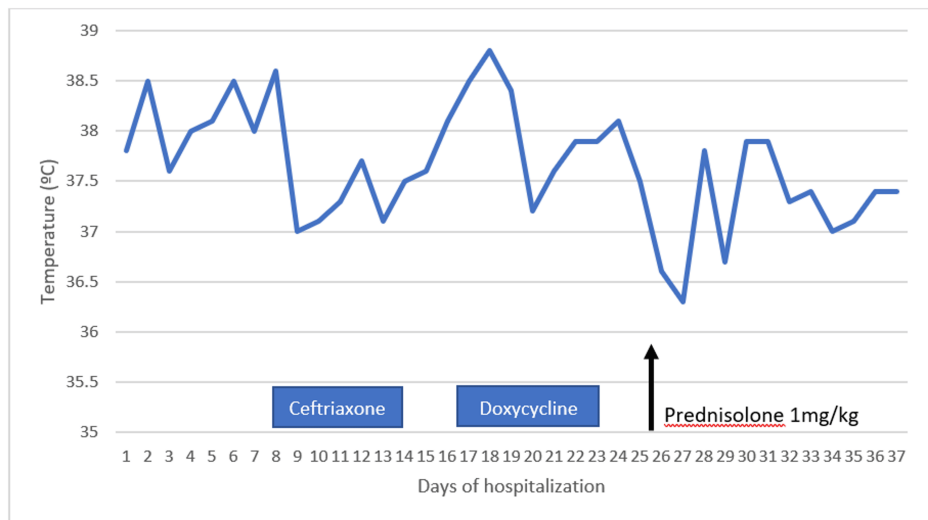


FIGURE 6: Temperature variation through hospitalization

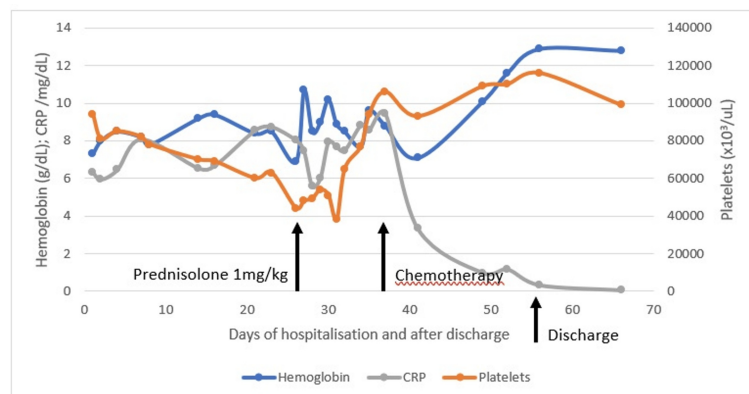


FIGURE 7: Hemoglobin, platelets and CRP variation through the hospital stay and after discharge

CRP – C Reactive Protein

During the hospital stay, the patient suffered a clinical worsening, with a transitory need for vasopressor support due to aggravated hypotension. After receiving the results from bone marrow immunophenotyping, a diagnosis of diffuse large B-cell lymphoma was confirmed, and targeted chemotherapy was initiated the following day with slow and steady improvement. Figure 7 illustrates the evolution of some analytic parameters through the hospital stay and the impact of different treatment phases.

Discussion

Hemophagocytic syndrome, or hemophagocytic lymphohistiocytosis, is characterized by an excessive activation of the immune system, more commonly affecting children but occurring at any age. It is classically divided into two groups - primary and secondary. Primary HLH occurs in children, typically within the first year of life, and is due to recessive genetic mutations that affect the function of T-NK lymphocytes and cytotoxic T-cells. In adults, secondary HLH arises from an underlying predisposing condition that disrupts immune regulation, such as neoplasms (particularly hematological), autoimmune diseases, or immunodeficiencies, and/or is triggered by bacterial, viral, fungal, or parasitic infections [5,6]. In a French study involving 162 adult patients, the most commonly associated condition with HLH was neoplasia (60%), followed by infection (25%) and autoimmune diseases (3%) [7].

Although mostly described in immunocompromised hosts associated with viral infections [8], most patients with HLH are not obviously immunosuppressed. When associated with a neoplasm (malignancy-associated hemophagocytic syndrome), it may either be the presenting clinical picture and initially mask the underlying malignancy or develop during the treatment for a known malignancy [4].

Clinically, HLH manifests as a fever associated with progressive dysfunction across multiple organs. The initial presentation can vary, often resembling common infections, hepatitis, or encephalitis, and may sometimes be diagnosed as a fever of unknown origin [9]. For these reasons, HLH is most known for its major diagnostic and therapeutic difficulties [4].

The first diagnostic guidelines were published by The Histiocyte Society in 1991 [10], which were later updated in 1994 with five criteria for its diagnosis (HLH-94 diagnostic criteria). In 2007, three more components were added [4] for a total of eight conditions (HLH 2004 criteria): fever, cytopenias involving two or more cell lines, hypertriglyceridemia or hypofibrinogenemia, splenomegaly, hemophagocytosis seen in bone marrow, lymph node or spleen, absent or low NK cell activity, raised serum ferritin, elevated sIL2R. HScore is another criterion used in adults to diagnose HLH [11].

The treatment involves, on the one hand, the removal of the trigger for HLH, whether it is infectious, neoplastic, or autoimmune, and, on the other hand, the management of the dysregulated immune system. Systemic corticosteroids are consensually the first-line therapy, with additional use of protocols based either on etoposide (as recommended by HLH-2004) or CHOP (cyclophosphamide, doxorubicin, vincristine, and prednisone) when cytotoxic drugs are necessary, such as the presented case. However, no consensus exists regarding the optimal initial therapy or its duration [5].

Conclusions

HLH is a rare disease that was fatal during the initial years when no proper diagnostic or treatment protocols were available. The presented case aims to illustrate a rare but real and likely underdiagnosed condition. Due to the nonspecific signs and symptoms, combined with a poor prognosis if left untreated, HLH requires a very high index of suspicion for a timely diagnosis and treatment.

Additional Information

Author Contributions

All authors have reviewed the final version to be published and agreed to be accountable for all aspects of the work.

Concept and design: Beatriz R. Marques, Victor Paz, Mariana Nunes

Acquisition, analysis, or interpretation of data: Beatriz R. Marques, Victor Paz, Sofia L. Costa, Filipa Seixas

Drafting of the manuscript: Beatriz R. Marques, Mariana Nunes

Critical review of the manuscript for important intellectual content: Beatriz R. Marques, Victor Paz, Mariana Nunes, Sofia L. Costa, Filipa Seixas

Disclosures

Human subjects: Consent for treatment and open access publication was obtained or waived by all participants in this study. **Conflicts of interest:** In compliance with the ICMJE uniform disclosure form, all authors declare the following: **Payment/services info:** All authors have declared that no financial support was received from any organization for the submitted work. **Financial relationships:** All authors have declared that they have no financial relationships at present or within the previous three years with any organizations that might have an interest in the submitted work. **Other relationships:** All authors have declared that there are no other relationships or activities that could appear to have influenced the submitted work.

References

1. Wright WF, Auwaerter PG: Fever and fever of unknown origin: Review, recent advances, and lingering dogma. *Open Forum Infect Dis.* 2020, 7:ofaa132. [10.1093/ofid/ofaa132](https://doi.org/10.1093/ofid/ofaa132)
2. Wright WF, Mulders-Manders CM, Auwaerter PG, Bleeker-Rovers CP: Fever of unknown origin (FUO) - A call for new research standards and updated clinical management. *Am J Med.* 2022, 135:173-8. [10.1016/j.amjmed.2021.07.038](https://doi.org/10.1016/j.amjmed.2021.07.038)
3. Chinnici A, Beneforti L, Pegoraro F, et al.: Approaching hemophagocytic lymphohistiocytosis. *Front Immunol.* 2023, 14:1210041. [10.3389/fimmu.2023.1210041](https://doi.org/10.3389/fimmu.2023.1210041)
4. Hayden A, Park S, Giustini D, Lee AY, Chen LY: Hemophagocytic syndromes (HPS) including hemophagocytic lymphohistiocytosis (HLH) in adults: A systematic scoping review. *Blood Rev.* 2016, 30:411-20. [10.1016/j.blre.2016.05.001](https://doi.org/10.1016/j.blre.2016.05.001)
5. Jordan MB, Allen CE, Weitzman S, Filipovich AH, McClain KL: How I treat hemophagocytic lymphohistiocytosis. *Blood.* 2011, 118:4041-52. [10.1182/blood-2011-03-278127](https://doi.org/10.1182/blood-2011-03-278127)
6. Rivière S, Galicier L, Coppo P, Marzac C, Aumont C, Lambotte O, Fardet L: Reactive hemophagocytic syndrome in adults: A retrospective analysis of 162 patients. *Am J Med.* 2014, 127:1118-25.

- [10.1016/j.amjmed.2014.04.034](https://doi.org/10.1016/j.amjmed.2014.04.034)
7. Janka G, Imashuku S, Elinder G, Schneider M, Henter JI: Infection- and malignancy-associated hemophagocytic syndromes. Secondary hemophagocytic lymphohistiocytosis. *Hematol Oncol Clin North Am.* 1998, 12:435-44. [10.1016/s0889-8588\(05\)70521-9](https://doi.org/10.1016/s0889-8588(05)70521-9)
 8. Henter JI, Horne A, Aricó M, et al.: HLH-2004: Diagnostic and therapeutic guidelines for hemophagocytic lymphohistiocytosis. *Pediatr Blood Cancer.* 2007, 48:124-31. [10.1002/pbc.21039](https://doi.org/10.1002/pbc.21039)
 9. Dhadwad JS, Kadiwala RS, Modi KK, Yadav PR, Vadivel SP: A case of pyrexia of unknown origin diagnosed as hemophagocytic lymphohistiocytosis. *Cureus.* 2024, 16:e53553. [10.7759/cureus.53553](https://doi.org/10.7759/cureus.53553)
 10. Henter JI, Elinder G, Ost A: Diagnostic guidelines for hemophagocytic lymphohistiocytosis. The FHL study group of the Histiocyte Society. *Semin Oncol.* 1991, 18:29-33.
 11. Fardet L, Galicier L, Lambotte O, et al.: Development and validation of the HScore, a score for the diagnosis of reactive hemophagocytic syndrome. *Arthritis Rheumatol.* 2014, 66:2613-20. [10.1002/art.38690](https://doi.org/10.1002/art.38690)