Cureus
Part of SPRINGER NATURE

Open Access Case Report

Renal Leiomyoma in a Female Adult: A Histopathological Case Report

Anastasia I. Bekyarova [1], Andreya Kirilova [1], Kristina Naydenova [1], Hristo Popov [1], George S. Stoyanov [2]

1. General and Clinical Pathology, Forensic Medicine and Deontology, Medical University of Varna, Varna, BGR 2. Pathology, Multiprofile Hospital for Active Treatment, Shumen, BGR

Corresponding author: Anastasia I. Bekyarova, anastasia.bekyarova@gmail.com

Review began 09/03/2024
Review ended 10/01/2024
Published 10/05/2024

© Copyright 2024
Bekyarova et al. This is an open access article distributed under the terms of the Creative Commons Attribution License CC-BY 4.0., which permits unrestricted use, distribution, and reproduction in any medium, provided the original author and source are credited.

DOI: 10.7759/cureus.70898

Abstract

Renal leiomyomas are rare benign mesenchymal tumors that arise from the smooth muscle cells in the renal capsule, renal pelvis, and the smooth muscles of vessels in the kidney. They are usually found by accident during autopsies or on different imaging modalities made on other occasions. The clinical presentation may include hematuria and abdominal or flank pain, although renal leiomyomas are most frequently asymptomatic. This case concerns a 45-year-old woman with an asymptomatic tumor mass in the left kidney, discovered incidentally on an outpatient CT scan conducted on an unrelated occasion. Histological examination revealed well-demarcated tumor formation on regular hematoxylin and eosin (H&E) staining consisting of intersecting fascicles of spindle cells with blunt-ended, cigar-shaped nuclei and eosinophilic cytoplasm. The neoplasm showed no mitotic activity. Immunohistochemistry (IHC) was performed to exclude different spindle cell pathologies, such as solitary fibrous tumor of the kidney, primary leiomyosarcoma, and, less probably, sarcomatoid variants of renal cell carcinoma (RCC). Tumor cell cytoplasm was positive for h-caldesmon, smooth muscle actin (SMA), and desmin. The proliferation index Kiel-67 (Ki-67) was evaluated as less than 1%. Considering the microscopic description and the IHC results, the neoplasm was interpreted as a renal leiomyoma. In light of the rarity of these tumors, pathologists should consider differential diagnosis with precision. In challenging cases, immunohistochemical examination can be beneficial to distinguish between several spindle cell renal neoplasms, such as solitary fibrous tumor, leiomyosarcoma, sarcomatoid variant of RCC, fat-poor angiomyolipoma, benign peripheral nerve sheath tumors, renomedullary interstitial cell tumor, benign fibrous histiocytoma, primary angiosarcoma, mucinous tubular and spindle cell renal cell carcinoma (MTSRCC).

Categories: Urology, Pathology
Keywords: benign mesenchymal tumor, kidney tumor, renal leiomyoma, renal tumor, spindle cell renal neoplasm

Introduction

Leiomyomas of the kidney are rare benign mesenchymal tumors, affecting predominantly females (2:1) with an average age of 47 [1]. They arise from the smooth muscle cells in the renal capsule, renal pelvis, and the vascular smooth muscle of vessels in the kidney. Based on their exact location, these tumors can be subclassified into subcapsular, capsular, and subpelvic types [1]. Renal leiomyomas account for less than 0.5% of surgically treated renal neoplasms. Their incidence seems to be greater in autopsies (4-5.5%), where they are usually found by accident. Imaging modalities, mostly done on other occasions, allow the detection of asymptomatic formations. Some patients may experience unspecific manifestations such as hematuria and abdominal or flank pain [2,3]. Renal leiomyomas have broad differential diagnosis regarding spindle cell renal neoplasms that should be considered during histological examination.

Case Presentation

This case study concerns a 45-year-old woman who was found to have an asymptomatic tumor mass in the left kidney. The formation was discovered incidentally during a CT scan conducted on an outpatient basis for reasons unrelated to this finding. An ambulatory sonogram showed left-sided peripheral heterogeneous, mainly iso- and hypoechogenic formation in the lower renal pole, which was 25 x 20 mm in size. The patient was referred for surgical treatment, and a robot-assisted partial resection of the affected kidney was performed.

Grossly, the excised specimen represented a round-to-oval, well-circumscribed tumor mass with grayish-white coloration, measuring 25 mm at its greatest dimension, located in the parenchymal periphery. No invasion of the capsule and the perirenal tissue was observed.

Histological examination revealed well-demarcated tumor formation on regular hematoxylin and eosin (H&E) staining consisting of intersecting fascicles of spindle cells with blunt-ended, cigar-shaped nuclei and eosinophilic cytoplasm (Figure *1A*). No mitoses were seen regardless of Kiel-67 (Ki-67) (proliferation index) being less than 1% positive. The surrounding renal tissue demonstrated atrophic changes (Figure *1B*).

How to cite this article
Bekyarova A I, Kirilova A, Naydenova K, et al. (October 05, 2024) Renal Leiomyoma in a Female Adult: A Histopathological Case Report. Cureus 16(10): e70898. DOI 10.7759/cureus.70898

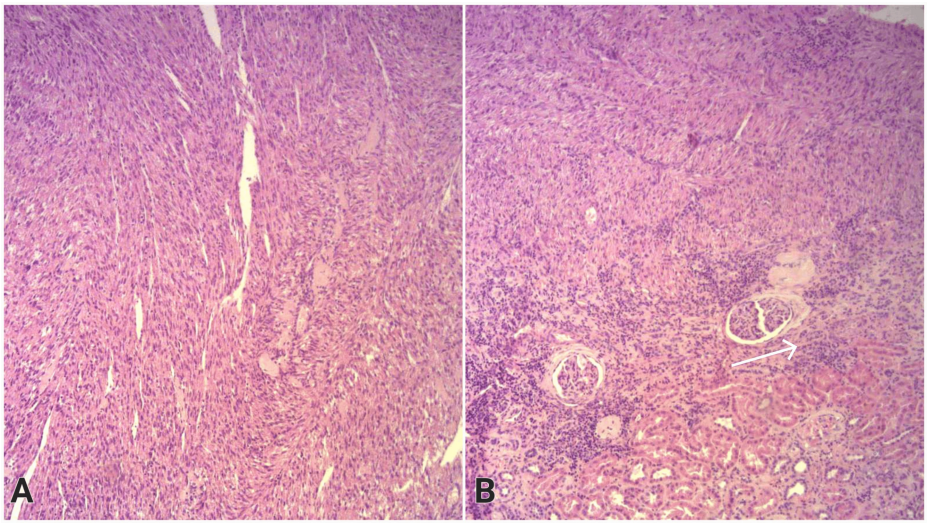

FIGURE 1: Histopathology of the renal leiomyoma, H&E stain, 100x

A: Central view of the tumor showing intersecting bundles of spindle cells with cigar-shaped nuclei and eosinophilic cytoplasm; B: In the periphery, the renal tubules exert signs of atrophy (arrow) due to compression by the tumor mass

H&E: Hematoxylin and eosin

At higher magnification, the tumor cells did not show any cellular or nuclear atypia, which contributed to the benign appearance of the tumor (Figure 2). Moreover, no necrotic foci were found within the specimen.

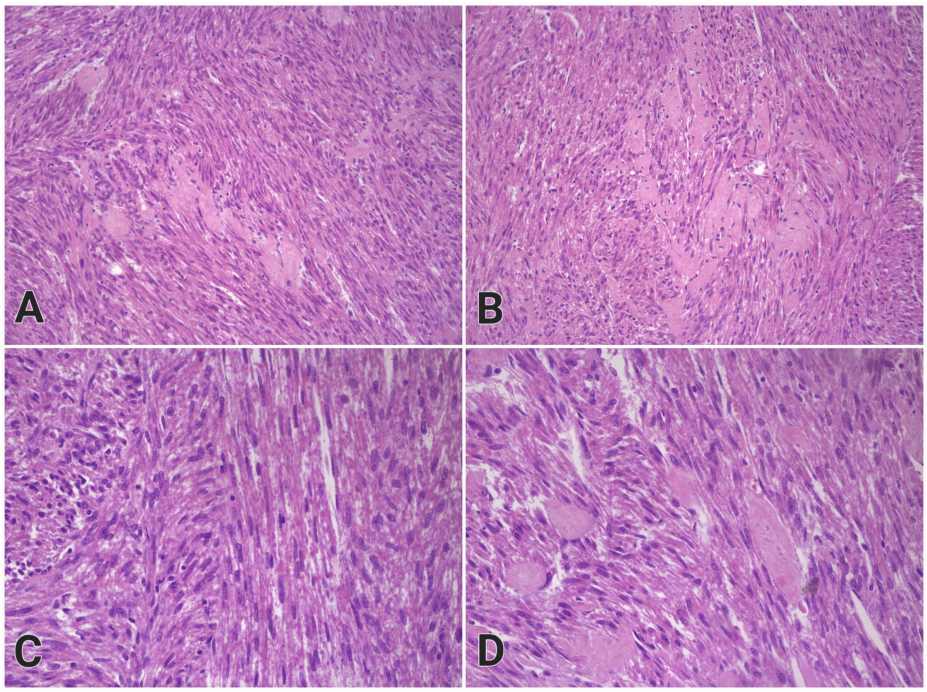

FIGURE 2: High magnification photos of the renal leiomyoma, demonstrating absence of cellular or nuclear atypia, H&E stain

A: 200x magnification, B: 200x magnification, C: 400x magnification, D: 400x magnification

In Figure 2A, the section crosses the tumor cell bundles longitudinally, and in Figure 2B, it is made transversely, resulting in a false loss of the spindle-shaped appearance of the cells. In Figure 2C, intersecting fascicles of tumor cells are shown, and in Figure 2D, in addition to the described histological picture, a homogeneous eosinophilic hyalinized substance is seen in the stroma.

H&E: Hematoxylin and eosin

Immunohistochemistry (IHC) was performed to exclude different spindle cell pathologies, such as solitary fibrous tumor of the kidney, primary leiomyosarcoma, and sarcomatoid variants of renal cell carcinoma (RCC). IHC panel included cluster of differentiation-34 (CD-34), Ki-67, epithelial membrane antigen (EMA), soluble 100 protein (S100), pankeratin (CK AE1/AE3), smooth muscle actin (SMA), h-caldesmon, desmin, vimentin. Tumor cell cytoplasm was positive for h-caldesmon, SMA, and desmin (Figure *3A*, *3B*, *3C*). Vimentin was expressed in some stromal cells (Figure *3D*).

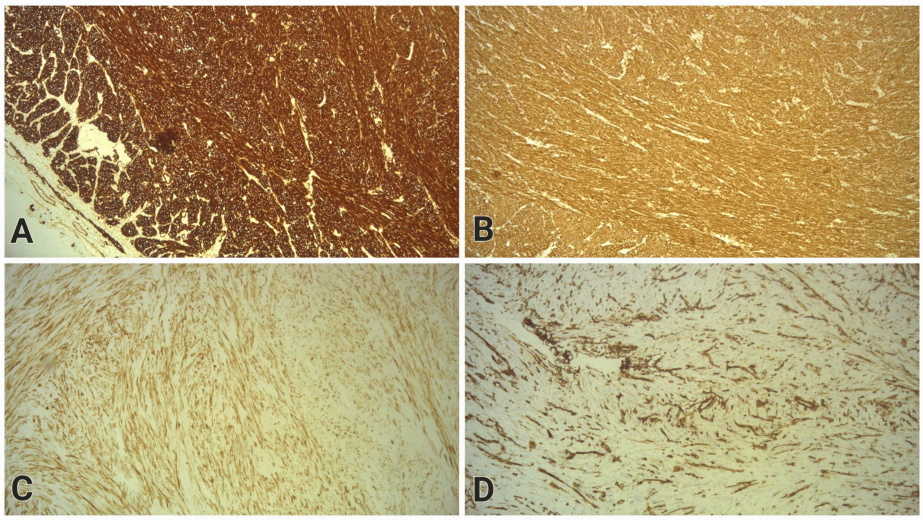

FIGURE 3: IHC displays diffusely positive reaction for h-caldesmon (A), SMA (B) and desmin (C) in the cells of the tumor parenchyma, while vimentin is expressed in some stromal cells (D), 100x

IHC: Immunohistochemistry, SMA: smooth muscle actin

Negative reaction by the tumor cells was reported for EMA, CK AE1/AE3, both expressed in the tubular epithelium. These negative epithelial markers excluded diagnoses with epithelial origin, such as sarcomatoid variant of RCC. S100, which was positive in the perirenal adipose tissue, showed no expression in the tumor cells. This finding excluded a neural crest origin of the tumor cells and neurofibroma or schwannoma as a potential diagnosis. CD-34 expression was noted only in vessel walls, which ruled out a solitary fibrous tumor. The proliferation index Ki-67 was evaluated as less than 1% (Figure *4*). Considering the microscopic description and the IHC results, the neoplasm was interpreted as a renal leiomyoma.

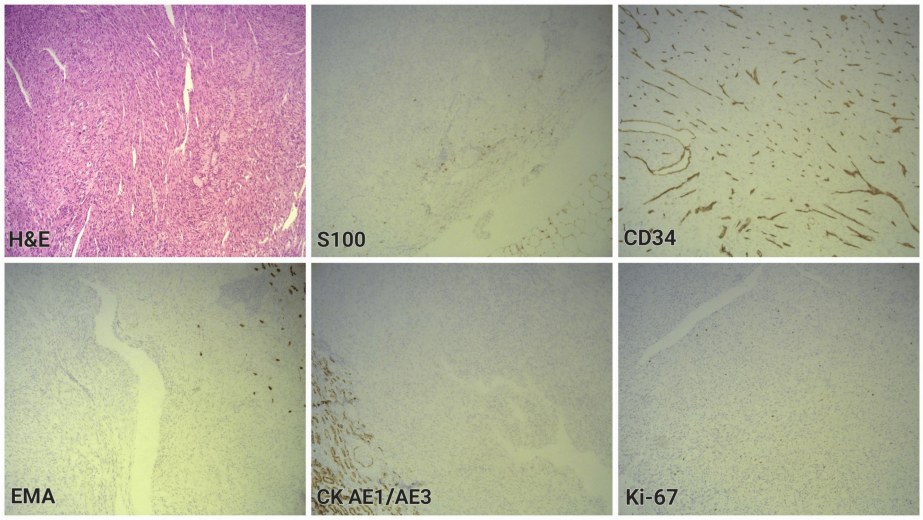

FIGURE 4: H&E staining of the specimen and IHC samples showing negative reaction in the tumor cells compared with internal controls, 100x

S100 is expressed in perirenal adipose tissue. CD-34 expression is observed in vessel walls. EMA and CK AE1/AE3 are expressed in tubular epithelium. Ki-67 expression marks low mitotic activity within the tumor (<1%).

H&E: Hematoxylin and eosin; IHC: Immunohistochemistry; S100: Soluble 100 protein; CD: Cluster of differentiation; EMA: Epithelial membrane antigen; CK AE1/AE3: Pankeratin; Ki-67: Kiel-67 (proliferation index)

Discussion

In light of the rarity of renal leiomyomas, pathologists should consider differential diagnosis with precision. In challenging cases, immunohistochemical examination can be beneficial to distinguish between several spindle cell renal neoplasms, namely solitary fibrous tumor, leiomyosarcoma, sarcomatoid variant of RCC (Table *1*). Other possible renal pathologies, included in the differential diagnosis, might be fat-poor angiomyolipoma, neurofibroma, schwannoma, renomedullary interstitial cell tumor, benign fibrous histiocytoma, primary angiosarcoma, mucinous tubular and spindle cell renal cell carcinoma (MTSRCC), although most of them have specific microscopic features which differ them morphologically from leiomyomas [4,5].

	Leiomyoma	Solitary fibrous tumor	Leiomyosarcoma	Sarcomatoid variant of RCC
Immunohistochemical profile	SMA (+)	CD-34 (+)	SMA (+)	CK (+)
	desmin (+)	Bcl-2 (+)	MSA (+)	RCC (+)
	h-caldesmon (+)	nuclear STAT6 (+)	desmin (+)	PAX8 (+)
	HMB-45 (+/–)	vimentin (+/–)	h-caldesmon (+)	CD-10 (+)
	Ki-67 ↓	CK (+/–)	vimentin (+)	EMA (+/–)
	-	SMA (+/–)	WT1 (+/–)	vimentin (+/–)
	-	desmin (+/–)	CK (+/–)	Ki-67 ↑
	-	S100 (+/–)	EMA (+/–)	-
	-	EMA (+/–)	CD-10 (+/–)	-
	-	Ki-67 ↓	Ki-67 ↑	-

TABLE 1: Immunophenotype of leiomyomas compared with other spindle cell tumors[5-9]

SMA: Smooth muscle actin; HMB: Human melanoma black; CD: Cluster of differentiation; Bcl-2: B-cell lymphoma 2; CK: Cytokeratins; STAT6: Signal transducer and activator of transcription 6; EMA: Epithelial membrane antigen; Ki-67: Kiel-67 (proliferation index); MSA: Muscle specific actin, RCC: Renal cell carcinoma; PAX8: Paired box gene 8; WT1: Wilms tumor 1 protein; S100: Soluble 100 protein

(+): Positive; (+/–): Rarely positive; ↓: Low expression (<1%); ↑: High expression (>10%)

Microscopically, leiomyomas exhibit benign characteristics such as no or minimal cellular atypia, no mitotic activity, and compressive behavior. In comparison, its malignant analogue demonstrates signs of malignant transformation. Abundant and aberrant mitotic figures, tumor necrosis, ability to infiltrate surrounding tissues, hemorrhages, and absence of granulation tissue around necrotic regions are indicative of leiomyosarcoma. Immunohistochemically, Ki-67 expression is usually low (<1%) in leiomyomas and other benign tumors and high (>10%) in malignancies [2].

Angiomyolipoma is a benign mesenchymal renal tumor composed of abnormally thick blood vessels, smooth muscle, and adipose tissue. Three types of angiomyolipoma are recognized: fat-rich (the most common), fat-poor, and epithelioid. They usually reveal IHC expression of SMA, MSA, human melanoma black-45 (HMB-45), Melan-A, S-100, and CD-117 [10].

Neurofibromas and schwannomas can be rarely observed in kidneys. These benign peripheral nerve sheath tumors strongly express S100 and are negative for smooth muscle molecular markers [11]. Common histological features of schwannomas are the Antoni A and Antoni B areas, which differ in cellularity and may contain Verocay bodies (parallel nuclear palisading separated by an anuclear zone) [12].

Renomedullary interstitial cell tumor, previously known as medullary fibroma, is also a benign neoplasm, mostly found incidentally because of its asymptomatic persistence. Immunohistochemically, the tumor has weak to moderate calponin and occasionally SMA expression [13].

Benign fibrous histiocytomas are divided into two types: superficial and deep. The former are located in the skin, and the latter, which are exclusively rare, involve internal organs (e.g., the kidneys). Their IHC profile includes diffuse vimentin and focal SMA expression in the tumor cells [14].

Primary renal angiosarcomas represent aggressive malignant neoplasms composed of pleomorphic spindle

cells with a vasoformative growth pattern. Gourley et al. reported a case revealing positive erythroblast transformation-specific related gene (ERG) and CD-31 [4].

Since 2004, MTSRCC has been considered a distinct entity after being previously recognized as a subtype of RCC. Difficulties in the diagnostic process may appear in cases of variant patterns, such as in spindle cell predominant MTSRCC. According to data in the literature, positive staining for alpha-methylacyl-CoA racemase (AMACR), CK AE1/AE3, CK7, CK19, EMA, and vimentin is expected [15].

Conclusions

The diagnosis of mesenchymal tumors of the kidneys represents a significant challenge for medical professionals. These neoplastic processes are less prevalent than epithelial tumors and encompass a diverse range of neoplasms, including benign and malignant variants. Some of these tumors are particularly rare in their specific locations. As illustrated in the case report, the differential diagnosis is inherently complex. Even in cases where tumors exhibit indolent clinical behaviors or evident histopathology, specialized studies are often necessary to exclude rare variants of malignant mesenchymal tumors. The description of rare nosological entities enhances the body of knowledge and facilitates the processes of diagnosis.

Additional Information

Author Contributions

All authors have reviewed the final version to be published and agreed to be accountable for all aspects of the work.

Concept and design: Anastasia I. Bekyarova, Kristina Naydenova, Andreya Kirilova, Hristo Popov, George S. Stoyanov

Acquisition, analysis, or interpretation of data: Anastasia I. Bekyarova, Kristina Naydenova, Andreya Kirilova, Hristo Popov, George S. Stoyanov

Drafting of the manuscript: Anastasia I. Bekyarova, Kristina Naydenova, Andreya Kirilova, Hristo Popov, George S. Stoyanov

Critical review of the manuscript for important intellectual content: Anastasia I. Bekyarova, Kristina Naydenova, Andreya Kirilova, Hristo Popov, George S. Stoyanov

Supervision: Kristina Naydenova, Andreya Kirilova, Hristo Popov, George S. Stoyanov

Disclosures

Human subjects: Consent was obtained or waived by all participants in this study. **Conflicts of interest:** In compliance with the ICMJE uniform disclosure form, all authors declare the following: **Payment/services info:** All authors have declared that no financial support was received from any organization for the submitted work. **Financial relationships:** All authors have declared that they have no financial relationships at present or within the previous three years with any organizations that might have an interest in the submitted work. **Other relationships:** All authors have declared that there are no other relationships or activities that could appear to have influenced the submitted work.

References

1. Karabulut D, Alkan A, Ozgur C, Gunay B, Burgazdere G, Oz Puyan F: Renal leiomyoma: an uncommon differential diagnosis of renal masses in pediatric age. Urol Case Rep. 2021, 36:101567. 10.1016/j.eucr.2021.101567
2. Gupta S, Jimenez RE, Folpe AL, Cheville JC: Renal leiomyoma and leiomyosarcoma: a study of 57 cases . Am J Surg Pathol. 2016, 40:1557-63. 10.1097/PAS.0000000000000681
3. Brunocilla E, Pultrone CV, Schiavina R, Vagnoni V, Caprara G, Martorana G: Renal leiomyoma: case report and literature review. Can Urol Assoc J. 2012, 6:E87-90. 10.5489/cuaj.11159
4. Gourley E, Digman G, Nicolas M, Kaushik D: Primary renal angiosarcoma. BMJ Case Rep. 2018, 2018:10.1136/bcr-2017-222672
5. Magro G, Cavallaro V, Torrisi A, Lopes M, Dell'Albani M, Lanzafame S: Intrarenal solitary fibrous tumor of the kidney report of a case with emphasis on the differential diagnosis in the wide spectrum of monomorphous spindle cell tumors of the kidney. Pathol Res Pract. 2002, 198:37-43. 10.1078/0344-0338-00182
6. Geramizadeh B, Marzban M, Churg A: Role of immunohistochemistry in the diagnosis of solitary fibrous tumor, a review. Iran J Pathol. 2016, 11:195-203.
7. Chaudhary D, Rath A, Mandal S, Khurana N, Agarwal PN: Primary leiomyosarcoma kidney - a rare entity with a diagnostic challenge. J Cancer Res Ther. 2022, 18:1186-8. 10.4103/jcrt.JCRT_107_19
8. DeLong W, Grignon DJ, Eberwein P, Shum DT, Wyatt JK: Sarcomatoid renal cell carcinoma. An immunohistochemical study of 18 cases. Arch Pathol Lab Med. 1993, 117:636-40.

9. Mentrikoski MJ, Wendroth SM, Wick MR: Immunohistochemical distinction of renal cell carcinoma from other carcinomas with clear-cell histomorphology: utility of CD10 and CA-125 in addition to PAX-2, PAX-8, RCCma, and adipophilin. Appl Immunohistochem Mol Morphol. 2014, 22:635-41. 10.1097/PAI.0000000000000004
10. Çalışkan S, Gümrükçü G, Özsoy E, Topaktas R, Öztürk Mİ: Renal angiomyolipoma. Rev Assoc Med Bras (1992). 2019, 65:977-81. 10.1590/1806-9282.65.7.977
11. Mondal SK, Mallick MG, Bandyopadhyay R, Mondal PK: Neurofibroma of kidney: an uncommon neoplasm and diagnostic dilemma with solitary fibrous tumor. J Cancer Res Ther. 2010, 6:388-90. 10.4103/0973-1482.73347
12. Hilton DA, Hanemann CO: Schwannomas and their pathogenesis . Brain Pathol. 2014, 24:205-20. 10.1111/bpa.12125
13. Lu Z, Al-Obaidy K, Cheng L, Perry KD, Grignon DJ, Williamson SR: Immunohistochemical characteristics of renomedullary interstitial cell tumor: a study of 41 tumors with emphasis on differential diagnosis of mesenchymal neoplasms. Hum Pathol. 2018, 82:46-50. 10.1016/j.humpath.2018.07.010
14. Du J, Zhang XT, Yang M, Liu XF, Lin XY: Deep benign fibrous histiocytoma occurring in the kidney: case report. Medicine (Baltimore). 2019, 98:e15150. 10.1097/MD.0000000000015150
15. Zhao M, He XL, Teng XD: Mucinous tubular and spindle cell renal cell carcinoma: a review of clinicopathologic aspects. Diagn Pathol. 2015, 10:168. 10.1186/s13000-015-0402-1