Cureus
Part of SPRINGER NATURE

Open Access Case Report

DOI: 10.7759/cureus.63984

Oral Manifestations of Parry-Romberg Syndrome: A Case Report

Review began 06/12/2024
Review ended 07/01/2024
Published 07/06/2024

© Copyright 2024
Hariri et al. This is an open access article distributed under the terms of the Creative Commons Attribution License CC-BY 4.0., which permits unrestricted use, distribution, and reproduction in any medium, provided the original author and source are credited.

El mehdi Hariri [1, 2], Mohamed Sellouti [3], Hind Ramdi [1]

1. Pediatric Dentistry, Faculty of Dental Medicine of Rabat, Mohammed V University in Rabat, Rabat, MAR 2. Pediatric Dentistry, Mohammed V Military Hospital of Rabat, Rabat, MAR 3. Neonatology, Faculty of Medicine and Pharmacy of Casablanca, Hassan II University of Casablanca, Casablanca, MAR

Corresponding author: El mehdi Hariri, haririelmehdi@gmail.com

Abstract

Parry-Romberg syndrome is a rare acquired disorder characterized by unilateral idiopathic progressive atrophy of the skin and soft tissues of the face, resulting in a sunken appearance. The muscles, cartilage, and underlying bony structures may also be affected. The etiology remains unclear and is based on several hypotheses. The incoherence of atrophy and the development of associated symptoms make the diagnosis, prognosis, and management of patients difficult. Here, we report the case of a 10-year-old boy who presented to the Department of Pediatric Dentistry at the Mohamed V Military Training Hospital in Rabat with progressive left hemifacial atrophy and was diagnosed by a pediatric rheumatologist as having Parry-Romberg syndrome. On extraoral examination, the patient presented a slight facial asymmetry and a small, dark, linear scar in the left zygomatic region. Intraoral examination revealed a left lateral open bite and atrophy of the left side of the tongue. Panoramic radiography showed incomplete eruption of the left mandibular first and second premolars (34/35), with significant root atrophy giving a narrowed appearance to the corresponding pulp chambers confirmed on retro alveolar radiographs. The mandible had a slightly reduced ramus height on the affected side confirming the patient's facial asymmetry. A better understanding of this syndrome will help to improve oral care in young patients.

Categories: Dentistry, Pediatrics, Rheumatology
Keywords: dark scar, dental abnormalities, oral manifestations, hemifacial atrophy, parry-romberg syndrome

Introduction

Parry-Romberg Syndrome, also known as progressive hemifacial atrophy, is a rare degenerative disorder characterized by unilateral atrophy of facial tissues including muscles, bones, skin, and cartilage [1,2]. This can lead to aesthetic concerns, as well as functional and psychological challenges due to facial asymmetry. It was first documented by Parry in 1825, and subsequently by Romberg in 1846 with unclear etiology, despite extensive study [3,4]. Historically, it has been debated whether progressive hemifacial atrophy is a form of linear scleroderma, known as morphea en coup de sabre [5]. Other authors are clear that it is an intrinsically different process or on a spectrum. It is now accepted that these two conditions are a part of the spectrum of localized scleroderma and often co-exist [6]. While dermatologic and ophthalmologic manifestations are well-documented, oral manifestations are less frequently reported [7,8].

Below, we report a case of oral manifestations observed in a young Moroccan patient diagnosed with Parry-Romberg Syndrome by a pediatric rheumatologist, which was confirmed by positive serological tests for antinuclear antibodies directed against double-stranded deoxyribonucleic acid and mitochondria, and by a biopsy revealing the presence of morphea.

Case Presentation

We received a 10-year-old Moroccan boy in the Department of Pediatric Dentistry at Mohamed V Military Hospital in Rabat with complaints of progressive hemifacial atrophy and difficulty chewing on the left side. The patient's general health was good, and we found no pathological history to explain the facial asymmetry (Figure *1*). No family history, particularly no siblings with the disease and our patient did not report the use of any medication prior to the discovery of the condition.

How to cite this article
Hariri E, Sellouti M, Ramdi H (July 06, 2024) Oral Manifestations of Parry-Romberg Syndrome: A Case Report. Cureus 16(7): e63984. DOI 10.7759/cureus.63984

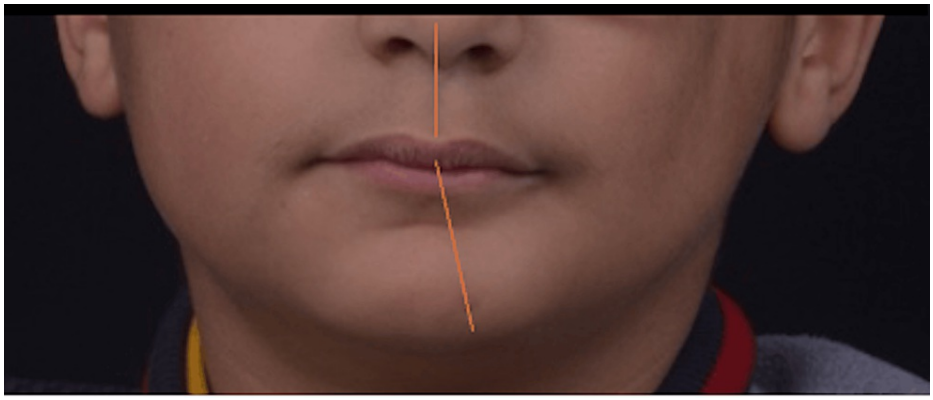

FIGURE 1: Facial asymmetry in relation to the median sagittal plane

The diagnosis of Parry-Romberg syndrome was made by a paediatric rheumatologist after carrying out two tests: serological tests for antinuclear antibodies directed against double-stranded deoxyribonucleic acid and mitochondria and a biopsy which revealed the presence of morphea. Several other diagnoses were suggested prior to testing, including hemifacial hypoplasia, scleroderma, oculoauriculovertebral-related disorders, lipodystrophy, and fat necrosis.

On extraoral examination, slight asymmetry was observed on the left side of the face, giving the appearance of a mandibular deviation, along with a small dark linear scar in the left zygomatic region, called morphea en coup de sabre (Figure 2).

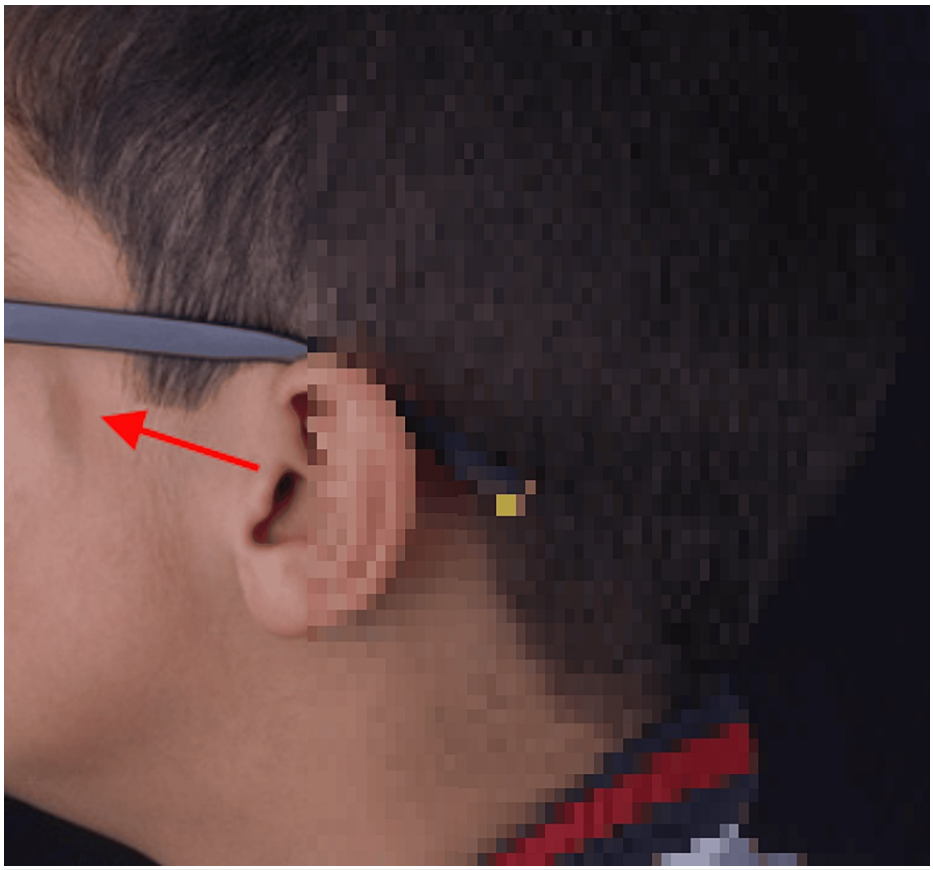

FIGURE 2: Morphea en coup de sabre in the left zygomatic region

During the intraoral examination, several notable findings were observed. These include a left lateral open bite due probably to incomplete eruption of the first and second left mandibular premolars (34/35) (Figure 3). The patient also has atrophy of the left side of the tongue, which gives the appearance of an asymmetrical tongue in relation to the median sagittal plane, resulting in significant difficulty in moving the tongue from

right to left (Figure 4). Additionally, there are signs of incipient temporomandibular joint dysfunction, particularly a slight left deviation of the mandible on opening.

FIGURE 3: Left unilateral open bite on the affected side

FIGURE 4: Atrophy of the left lateral border of the tongue

The panoramic radiograph (Figure 5) shows the incomplete eruption of the mandibular first and second premolars on the affected side (34/35), with significant root atrophy giving a narrowed appearance to the corresponding pulp chambers (Figures 6A, 6B). This appearance is very visible in the retro alveolar radiographs. The mandible has a slightly reduced ramus height on the affected side, which also confirms the patient's facial asymmetry and slight left deviation of the mandible on opening (Figure 5).

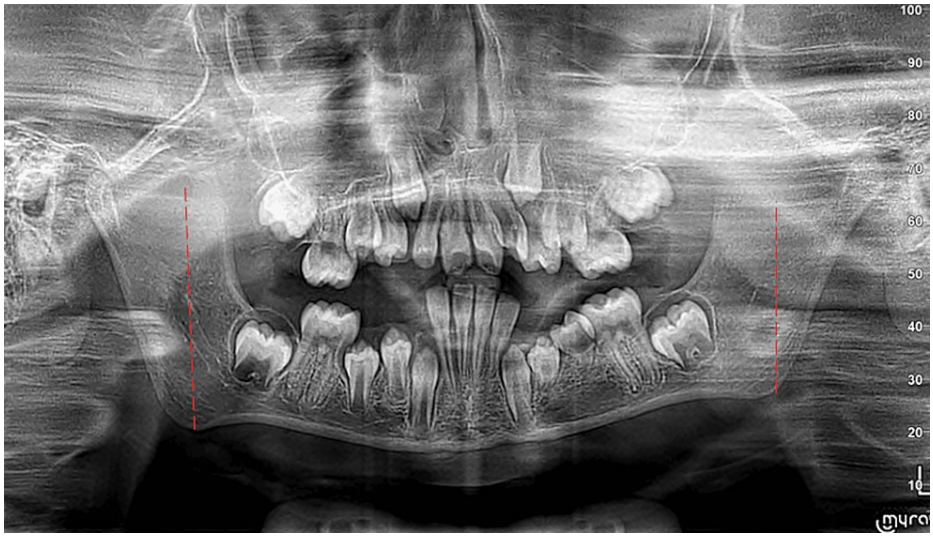

FIGURE 5: Decreased ramus height on the left side

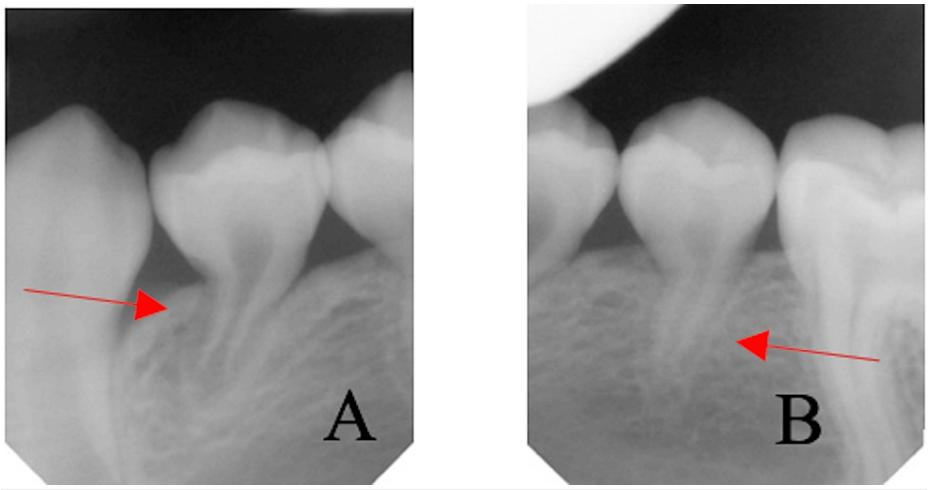

FIGURE 6: Root atrophy of the first and second left mandibular premolars

Premolars 34 (A) and 35 (B) with the narrowed appearance of the corresponding pulp chambers.

At this stage, our patient is only being treated with corticosteroids (oral prednisolone at a 1 mg/kg/day dose) to suppress the activity of the immune system in order to slow the progression of the condition and improve his quality of life. Our patient's parents have also reported a significant increase in the child's weight following treatment with no clear improvement in hemifacial atrophy. In order to have a positive impact on the patient's psychology, the parents have explained to the child that this is a temporary problem that will improve with time.

Discussion

This case illustrates some of the oral manifestations associated with Parry-Romberg syndrome, which can have a significant impact on the patient's oral health and quality of life. The condition is more common in females, with a predilection for the left side of the face [8]. The prevalence rate is estimated to be at least one in 7,000 in the general population. The condition is most common in the first and second decades of life [9]. The progression of this disorder can stabilize at any stage of growth and development. The skin on the affected side has a resembling scleroderma and may be pigmented, as in our case (Figure *2*). In some patients, a linear scar may mark the border between normal and abnormal skin, called morphea en coup de sabre [10,11].

Several factors have been identified as potentially involved in the pathogenesis of Parry-Romberg syndrome, including disturbances in fat metabolism, trauma, viral infections, heredity, endocrine disturbances, and

autoimmunity [12]. However, none of these theories provides a satisfactory explanation for the condition, and the pathogenesis of Parry-Romberg syndrome remains unresolved. Recently, there have been reports in the literature of extracutaneous involvement, which suggests that this is not only a cutaneous disease [13].

Although the intraoral soft tissues and masticatory muscles are affected, normal functions such as speech and deglutition are not affected [14,15]. There may be deformity of the mouth and nose on the affected side, as well as marked atrophy of the tongue papillae and the left lateral border, as observed in our case (Figure *4*). Lingual atrophy and oral mucosal changes may predispose the patient to periodontal disease and oral mucosal damage, emphasizing the importance of regular maintenance and monitoring of oral hygiene. Root atrophy, defects in tooth eruption, and delayed tooth formation and maturation can also be seen in Parry-Romberg syndrome, as in our case (Figures *6A*, *6B*). However, the affected teeth have a normal clinical appearance and are vital. Jaw hypoplasia and delayed eruption often result in a unilateral posterior open bite [16].

In addition, temporomandibular joint dysfunction, as evidenced by mandibular flexion towards the affected side and presenting malocclusion such as unilateral posterior open bite, highlights the need for comprehensive evaluation and management of temporomandibular joint disorders in patients with Parry-Romberg syndrome.

Treatment of atrophy is generally based on remodeling the adipose tissue destroyed by the condition [17]. Several therapeutic options are available, including autogenous fat grafts, cartilage grafts, silicone injections, the use of bovine collagen, and inorganic implants [18]. These therapeutic options are mainly intended to improve the aesthetic appearance of the face and the psychological comfort of patients. A multidisciplinary approach is often required, involving plastic surgeons, pediatric dentists, speech therapists, and psychologists [19,20]. Orthodontic treatment and prosthetic rehabilitation can help to resolve the aesthetic, functional, and psychological problems associated with this condition.

Conclusions

The present case highlights the importance of recognizing the various symptoms associated with Parry-Romberg syndrome, particularly the oral manifestations, and the need for comprehensive, multidisciplinary management of the aesthetic and functional aspects of this condition. Further research is needed to better understand the pathophysiology of the oral manifestations of Parry-Romberg syndrome and optimize treatment strategies for affected individuals, to improve their quality of life.

Additional Information

Author Contributions

All authors have reviewed the final version to be published and agreed to be accountable for all aspects of the work.

Concept and design: El mehdi Hariri, Mohamed Sellouti, Hind Ramdi

Acquisition, analysis, or interpretation of data: El mehdi Hariri, Mohamed Sellouti

Drafting of the manuscript: El mehdi Hariri, Mohamed Sellouti

Critical review of the manuscript for important intellectual content: El mehdi Hariri, Mohamed Sellouti, Hind Ramdi

Supervision: Hind Ramdi

Disclosures

Human subjects: Consent was obtained or waived by all participants in this study. **Conflicts of interest:** In compliance with the ICMJE uniform disclosure form, all authors declare the following: **Payment/services info:** All authors have declared that no financial support was received from any organization for the submitted work. **Financial relationships:** All authors have declared that they have no financial relationships at present or within the previous three years with any organizations that might have an interest in the submitted work. **Other relationships:** All authors have declared that there are no other relationships or activities that could appear to have influenced the submitted work.

References

1. El-Kehdy J, Abbas O, Rubeiz N: A review of Parry-Romberg syndrome . J Am Acad Dermatol. 2012, 67:769-84. 10.1016/j.jaad.2012.01.019
2. Ojeda Lewis E, Díaz Arangoitia S, Duránd Anahua P: Progressive hemifacial atrophy or Parry-Romberg syndrome: a pediatric case report. Medwave. 2020, 20:e7880. 10.5867/medwave.2020.03.7880

3. Tolkachjov SN, Patel NG, Tollefson MM: Progressive hemifacial atrophy: a review. Orphanet J Rare Dis. 2015, 10:39. 10.1186/s13023-015-0250-9
4. Blaszczyk M, Jablonska S: Linear scleroderma en Coup de Sabre. Relationship with progressive facial hemiatrophy (PFH). Adv Exp Med Biol. 1999, 455:101-4.
5. Papara C, De Luca DA, Bieber K, Vorobyev A, Ludwig RJ: Morphea: the 2023 update. Front Med (Lausanne). 2023, 10:1108623. 10.3389/fmed.2023.1108623
6. Bucher F, Fricke J, Neugebauer A, Cursiefen C, Heindl LM: Ophthalmological manifestations of Parry-Romberg syndrome. Surv Ophthalmol. 2016, 61:693-701. 10.1016/j.survophthal.2016.03.009
7. Al-Gburi S, Kreuter A, Moinzadeh P: Localized scleroderma (Article in German). Dermatologie (Heidelb). 2024, 75:197-207. 10.1007/s00105-024-05297-9
8. Dzefi-Tettey K, Edzie EK, Seadey MY, et al.: Parry Romberg syndrome in a young Ghanaian: a case report and a literature review. Cureus. 2022, 14:e32287. 10.7759/cureus.32287
9. Anderson PJ, Molony D, Haan E, David DJ: Familial Parry-Romberg disease. Int J Pediatr Otorhinolaryngol. 2005, 69:705-8. 10.1016/j.ijporl.2004.12.004
10. Carreño M, Donaire A, Barceló MI, et al.: Parry Romberg syndrome and linear scleroderma in coup de sabre mimicking Rasmussen encephalitis. Neurology. 2007, 68:1308-10. 10.1212/01.wnl.0000259523.09001.7a
11. Tollefson MM, Witman PM: En coup de sabre morphea and Parry-Romberg syndrome: a retrospective review of 54 patients. J Am Acad Dermatol. 2007, 56:257-63. 10.1016/j.jaad.2006.10.959
12. Guerrerosantos J, Guerrerosantos F, Orozco J: Classification and treatment of facial tissue atrophy in Parry-Romberg disease. Aesthetic Plast Surg. 2007, 31:424-34. 10.1007/s00266-006-0215-4
13. Lewkonia RM, Lowry RB: Progressive hemifacial atrophy (Parry-Romberg syndrome) report with review of genetics and nosology. Am J Med Genet. 1983, 14:385-90. 10.1002/amjg.1320140220
14. Goldhammer Y, Kronenberg J, Tadmor R, Braham J, Leventon G: Progressive hemifacial atrophy (Parry-Romberg's disease), principally involving bone. J Laryngol Otol. 1981, 95:643-7. 10.1017/s0022215100091210
15. Lehman TJ: The Parry Romberg syndrome of progressive facial hemiatrophy and linear scleroderma en coup de sabre. Mistaken diagnosis or overlapping conditions?. J Rheumatol. 1992, 19:844-5.
16. Foster TD: The effects of hemifacial atrophy on dental growth . Br Dent J. 1979, 146:148-50. 10.1038/sj.bdj.4804213
17. Castro-Govea Y, De La Garza-Pineda O, Lara-Arias J, Chacón-Martínez H, Mecott-Rivera G, Salazar-Lozano A, Valdes-Flores E: Cell-assisted lipotransfer for the treatment of parry-romberg syndrome . Arch Plast Surg. 2012, 39:659-62. 10.5999/aps.2012.39.6.659
18. Ye XD, Li CY, Wang C, Yu YS: Superficial temporal fascial flap plus lipofilling for facial contour reconstruction in bilateral progressive facial hemiatrophy. Aesthetic Plast Surg. 2010, 34:534-7. 10.1007/s00266-010-9480-3
19. Terenzi V, Leonardi A, Covelli E, et al.: Parry-Romberg syndrome. Plast Reconstr Surg. 2005, 116:97e-102e. 10.1097/01.prs.0000182402.58757.b9
20. Vaienti L, Soresina M, Menozzi A: Parascapular free flap and fat grafts: combined surgical methods in morphological restoration of hemifacial progressive atrophy. Plast Reconstr Surg. 2005, 116:699-711. 10.1097/01.prs.0000177449.12366.48