Cureus
Part of SPRINGER NATURE

Open Access Case Report

DOI: 10.7759/cureus.58279

Customizing the Emergence Profile Around an Immediately Loaded Single Implant in the Esthetic Zone: A Case Report

Grazina Fernandes [1], Ashwin Mysore [1], Omkar Shetye [2], Meena Aras [1], Vidya Chitre [1]

1. Department of Prosthodontics and Crown and Bridge, Goa Dental College and Hospital, Bambolim, IND 2. Department of Oral and Maxillofacial Surgery, Goa Dental College and Hospital, Bambolim, IND

Corresponding author: Grazina Fernandes, fernandesgrazina@gmail.com

Review began 03/25/2024
Review ended 03/27/2024
Published 04/15/2024

© Copyright 2024
Fernandes et al. This is an open access article distributed under the terms of the Creative Commons Attribution License CC-BY 4.0., which permits unrestricted use, distribution, and reproduction in any medium, provided the original author and source are credited.

Abstract

An optimal esthetic result is essential for an implant-supported restoration in the anterior zone. In the esthetic zone, providing immediate interim restorations following implant surgery has been proposed as a reliable and desirable treatment approach. A well-contoured interim restoration following implant placement minimizes hard and soft tissue changes in the peri-implant zone. This in turn has the potential to enhance the esthetic outcome and, therefore, patient satisfaction. Multiple prosthetic and surgical aspects need to be carefully planned and executed to achieve the intended final result. This is a report describing the steps involved in recontouring the gingiva to achieve an optimal emergence profile following the immediate loading of a single implant in the esthetic zone.

Categories: Dentistry
Keywords: customizing soft tissue, ridge augmentation, prosthetic rehabilitation, gingival recontouring, soft tissue contour, interim restoration, immediate loading, esthetics, implants, emergence profile

Introduction

Implant therapy is currently regarded as the most suitable method for replacing missing teeth, particularly in the anterior zone. The essential requirement for the success of implants is osteointegration. One of the most important elements in ensuring the longevity of implants and determining the ideal hard and soft tissues is the emergence profile. The emergence profile of dental implant restorations should resemble natural teeth. Inflamed soft tissue and limited access to oral hygiene are consequences of improperly shaped tissues and restorations that can lead to unappealing outcomes [1,2]. For both esthetic and functional implant therapy, a well-contoured restoration with a natural emergence profile and gingival structure that blends in with surrounding teeth is crucial [3].

In 1977, Stein and Kuwata introduced the term "emergence profile" to describe the contours of teeth and crowns as they traversed soft tissue and ascended toward the interproximal contact area and the buccal and lingual height of contour [4]. According to Croll's photographic analysis of natural teeth, emergence profiles are generally straight rather than convex or concave [5]. To provide favorable conditions for oral hygiene, interim crowns can be modified gradually by guided conditioning employing a dynamic compression technique in the peri-implant area [6].

This case report describes a technique to fabricate a screw-retained interim restoration using composite resin for immediate loading followed by transfer of the emergence profile using a customized impression coping.

Case Presentation

A healthy 25-year-old female patient presented with a fractured fixed partial denture (FPD) of teeth 11, 12, and 21. Clinical examination revealed a fracture of the pontic on the palatal aspect (Figure *1*). A cone beam computed tomography (CBCT) scan was performed, which revealed horizontal alveolar bone resorption at the missing central incisor site (Figure *2*). Rehabilitation of the missing incisor with a dental implant following bone augmentation was decided upon as the treatment of choice.

How to cite this article
Fernandes G, Mysore A, Shetye O, et al. (April 15, 2024) Customizing the Emergence Profile Around an Immediately Loaded Single Implant in the Esthetic Zone: A Case Report. Cureus 16(4): e58279. DOI 10.7759/cureus.58279

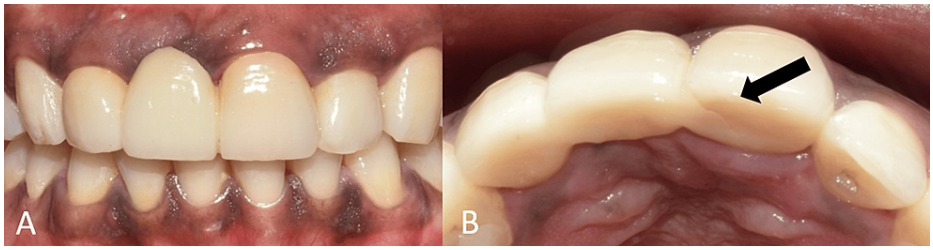

FIGURE 1: Pre-operative intraoral view showing fractured FPD.

(A) Frontal view on maximum intercuspation showing the FPD in relation to teeth no. 11, 12, and 21; (B) occlusal view showing fractured FDP on the palatal aspect (black arrow).

FPD, fixed partial denture

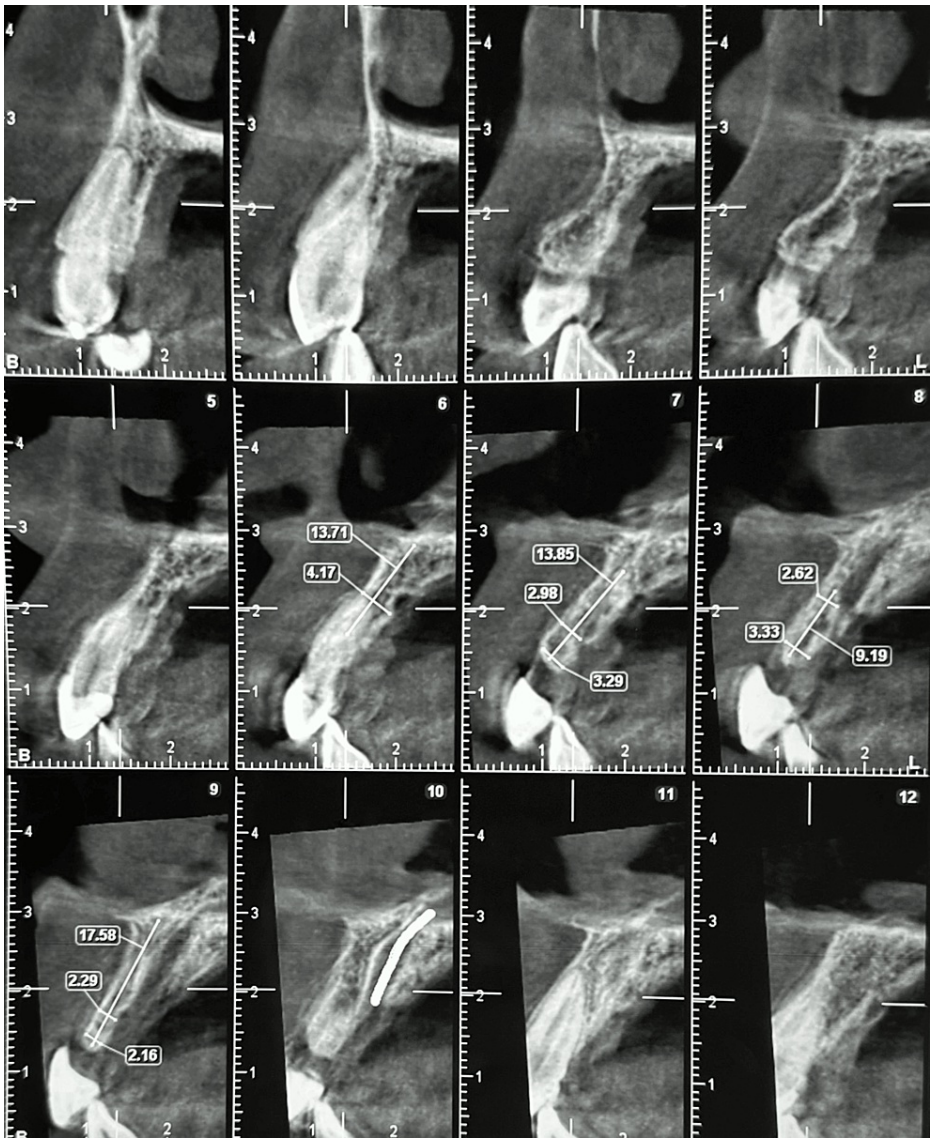

FIGURE 2: Pre-operative CBCT of anterior maxilla showing bone width at different sections.

CBCT, cone beam computed tomography

Following the removal of the FPD, the patient was instructed to rinse with 0.2% chlorhexidine for one

minute before beginning the surgical procedure. The perioral skin was disinfected with a 5% povidone-iodine solution. Local anesthetic (2% lignocaine with 1:80,000 adrenaline) was used during the surgery. In addition to releasing incisions, crestal and intrasulcular incisions were made on the labial surfaces of adjacent teeth to obtain access. A mucoperiosteal flap of full thickness was raised (Figure *3A*).

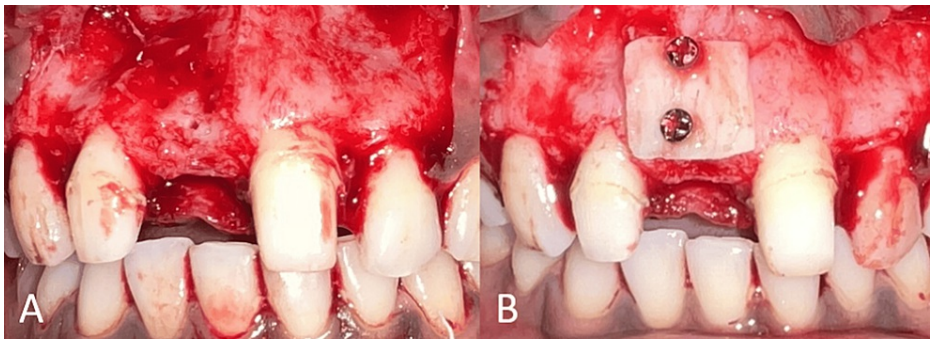

FIGURE 3: Surgical procedure.

(A) Flap elevation showing the labial defect; (B) placement of autogenous bone block harvested from the mandibular symphysis.

The Khoury technique of bone augmentation was used; wherein an autogenous bone block was harvested from the symphysis region of the mandible and stabilized using two microscrews (1.5x10 mm, AK instruments, India) on the labial aspect of the defect (Figure *3B*). The generated gap was filled with a combination of autogenous and deproteinized bovine bone xenograft (Bio-Oss; small granules, Geistlich Pharma, Wolhusen, Switzerland). The flap was sutured and primary closure was obtained. Postoperative instructions were provided to the patient. A heat-cured acrylic FPD was cemented post-operatively to serve as a tooth-supported provisional restoration (Figure *4*).

FIGURE 4: Frontal view showing heat-cured acrylic FPD in relation to tooth no. 11, 12, and 21.

FPD, fixed partial denture

After six months of healing, the site was reopened using a modified papilla-sparing incision, and a full-thickness mucoperiosteal flap was raised for implant placement. The bone demonstrated a horizontal width of 6 mm (Figure *5*). The two microscrews were removed and a 4x11.5 mm implant (Osstem implant TS III, Seoul, Korea) was placed in the central incisor region (Figure *6*).

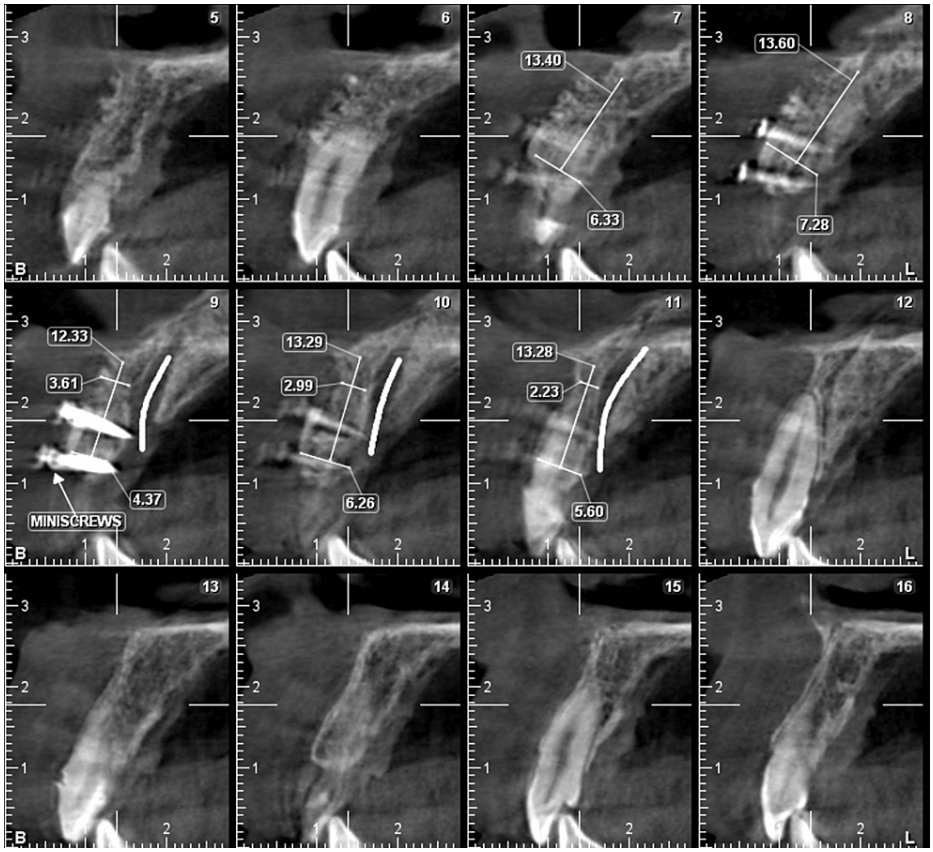

FIGURE 5: Post-operative CBCT of anterior maxilla showing the regenerated site and microscrews at different sections.

CBCT, cone beam computed tomography

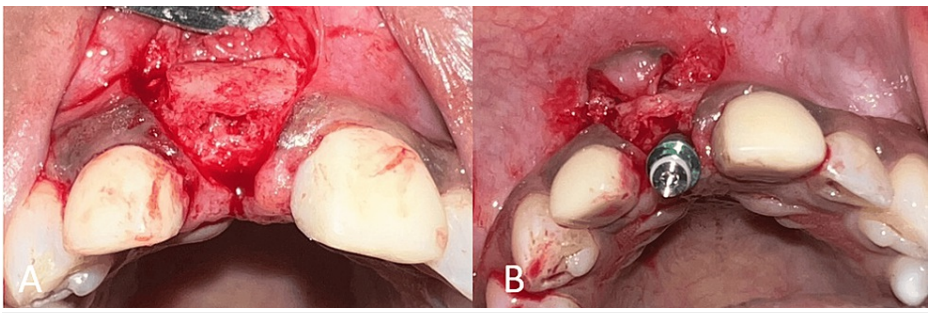

FIGURE 6: Surgical procedure.

(A) Flap elevation showing the regenerated site; (B) implant placement in relation to tooth no. 11.

The temporary abutment was positioned at the surgical site following the implant insertion. To fabricate an interim restoration, the composite resin was incrementally built up over and around the temporary abutment (Figure 7).

FIGURE 7: Screw-retained interim implant restoration.

To obtain the desired emergence profile, the soft tissue around the interim restoration was molded by relining the composite every two weeks for a period of two months (Figure *8*).

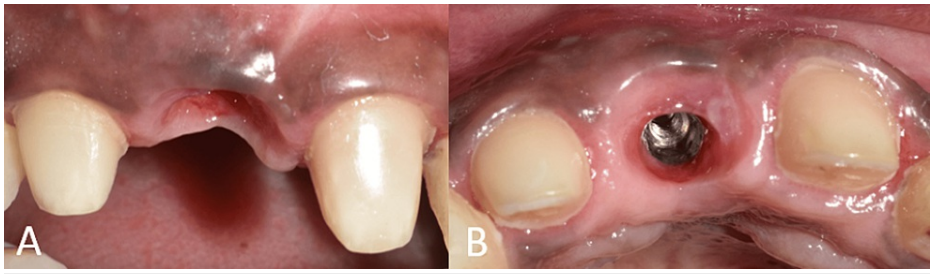

FIGURE 8: Emergence profile after customization.

(A) Frontal view showing the customized emergence profile in relation to tooth no. 11; (B) occlusal view showing the customized emergence profile in relation to tooth no. 11.

A final implant prosthesis was fabricated after the desired emergence profile was achieved. The gingival contour that was achieved using the prior restoration was transferred to an open-tray impression coping using the technique recommended by Hinds, following which an implant-level impression was made (Figure *9* and Figure *10*) [7].

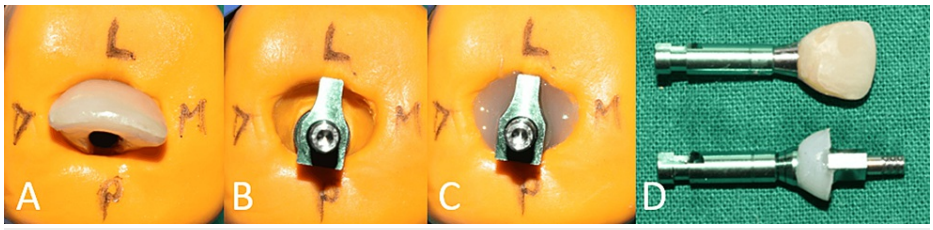

FIGURE 9: Customizing the open-tray impression coping.

(A) Placement of the interim restoration in the putty index; (B) removal of interim restoration followed by placement of the open-tray impression coping in the putty index; (C) placement of flowable composite into the space between putty and the impression coping; (D) contours of the interim restoration transferred to the impression coping.

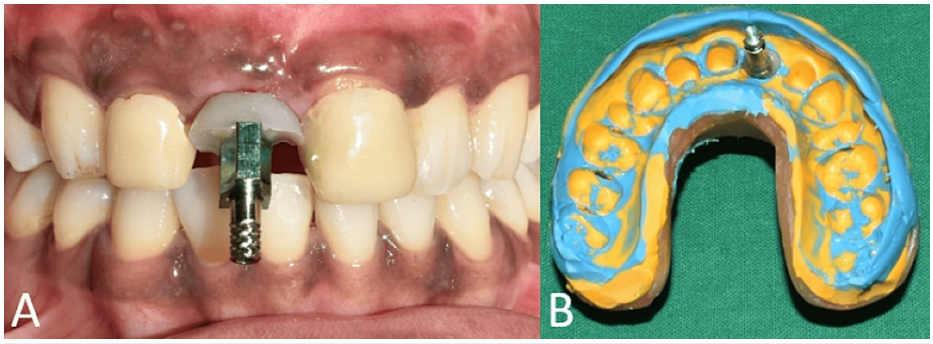

FIGURE 10: Open-tray implant impression to fabricate the prosthesis.

(A) Frontal view showing the customized impression coping; (B) open-tray implant impression.

The definitive prosthesis was fabricated and inserted (Figure *11* and Figure *12*).

FIGURE 11: Frontal view showing the final implant prosthesis.

FIGURE 12: Extraoral picture of the patient smiling after final restorations.

Discussion

In the maxillary anterior area, achieving optimal esthetic outcomes with dental implants is difficult and depends on bone quantity, quality, and interdental papilla preservation [8]. Benefits of immediately loaded implants include immediate function, interim restoration insertion without the need for second-stage surgery, a reduction in treatment time and trauma, and psychological benefits [9].

A favorable emergence profile supports the soft tissue around restorations; it allows the maintenance of oral hygiene [10]. For implant-supported restorations, a provisional restoration can aid in both obtaining and planning the desired esthetic outcome. A significant benefit of temporary restorations is the ability to contour the gingival architecture as it heals [11]. Various methods have been suggested to restore gingival contour, establish an emergence profile, and transfer the contour for an esthetic final restoration. Neale and Chee recommended recontouring the tissues using gingivoplasty techniques before fabricating interim restoration [1]. Ormianer et al. transferred the soft tissue shape by immediately placing autopolymerizing acrylic resin into the sulcus [12]. However, intraoral usage of acrylic resin monomer may irritate soft tissue chemically and thermally. Hinds et al. described a technique to customize impression coping for replicating the healed soft tissue [7].

The technique described in this article minimizes gingival discomfort by preventing the intraoral use of resin monomer. By reshaping the soft tissue as required throughout the healing process, it also reduces the need for second-stage surgery. A further significant benefit is the prevention of soft tissue collapse during the impression process, since the impression copings that are customized provide an accurate transfer of the peri-implant soft tissue contours to the cast and, therefore, to the final restorations.

Conclusions

In the esthetic zone, careful patient selection, diagnosis, and treatment planning are necessary to prevent undesirable results. Consideration must be given to the parameters at each stage, from implant placement to the postoperative phase, to create a harmonious and esthetic emerging profile. An implant prosthesis needs to have both a functional and esthetically pleasing design. The process of gingival recontouring with a temporary restoration is non-invasive. By adjusting the emerging profile during the healing period, it is possible to effectively achieve the final result, which consists of a soft tissue structure that is harmonious with the contours of the restoration.

Additional Information

Author Contributions

All authors have reviewed the final version to be published and agreed to be accountable for all aspects of the work.

Concept and design: Grazina Fernandes, Ashwin Mysore, Omkar Shetye, Meena Aras, Vidya Chitre

Acquisition, analysis, or interpretation of data: Grazina Fernandes, Ashwin Mysore, Omkar Shetye, Meena Aras, Vidya Chitre

Drafting of the manuscript: Grazina Fernandes, Ashwin Mysore, Omkar Shetye, Meena Aras, Vidya Chitre

Critical review of the manuscript for important intellectual content: Grazina Fernandes, Ashwin Mysore, Omkar Shetye, Meena Aras, Vidya Chitre

Supervision: Grazina Fernandes, Ashwin Mysore, Omkar Shetye, Meena Aras, Vidya Chitre

Disclosures

Human subjects: Consent was obtained or waived by all participants in this study. **Conflicts of interest:** In compliance with the ICMJE uniform disclosure form, all authors declare the following: **Payment/services info:** All authors have declared that no financial support was received from any organization for the submitted work. **Financial relationships:** All authors have declared that they have no financial relationships at present or within the previous three years with any organizations that might have an interest in the submitted work. **Other relationships:** All authors have declared that there are no other relationships or activities that could appear to have influenced the submitted work.

References

1. Neale D, Chee WW: Development of implant soft tissue emergence profile: a technique . J Prosthet Dent. 1994, 71:364-8. 10.1016/0022-3913(94)90095-7
2. Jansen CE: Guided soft tissue healing in implant dentistry . J Calif Dent Assoc. 1995, 23:57-8, 60, 62 passim.
3. Su H, Gonzalez-Martin O, Weisgold A, Lee E: Considerations of implant abutment and crown contour: critical contour and subcritical contour. Int J Periodontics Restorative Dent. 2010, 30:335-43. 10.11607/prd.00.0933
4. Stein RS, Kuwata M: A dentist and a dental technologist analyze current ceramo-metal procedures . Dent Clin North Am. 1977, 21:729-49. 10.1016/S0011-8532(22)00988-0
5. Croll BM: Emergence profiles in natural tooth contour. Part II: clinical considerations . J Prosthet Dent. 1990, 63:374-9. 10.1016/0022-3913(90)90223-Y
6. Wittneben JG, Buser D, Belser UC, Brägger U: Peri-implant soft tissue conditioning with provisional restorations in the esthetic zone: the dynamic compression technique. Int J Periodontics Restorative Dent. 2013, 33:447-55. 10.11607/prd.1268
7. Hinds KF: Custom impression coping for an exact registration of the healed tissue in the esthetic implant restoration. Int J Periodontics Restorative Dent. 1997, 17:584-91.
8. Kan JY, Rungcharassaeng K, Deflorian M, Weinstein T, Wang HL, Testori T: Immediate implant placement and provisionalization of maxillary anterior single implants. Periodontol 2000. 2018, 77:197-212. 10.1111/prd.12212
9. Stanley M, Braga FC, Jordao BM: Immediate loading of single implants in the anterior maxilla: a 1-year prospective clinical study on 34 patients. Int J Dent. 2017, 2017:8346496. 10.1155/2017/8346496
10. Croll BM: Emergence profiles in natural tooth contour. Part I: photographic observations . J Prosthet Dent. 1989, 62:4-10. 10.1016/0022-3913(89)90036-x
11. Ganddini MR, Tallents RH, Ercoli C, Ganddini R: Technique for fabricating a cement-retained single-unit implant-supported provisional restoration in the esthetic zone. J Prosthet Dent. 2005, 94:296-8. 10.1016/j.prosdent.2005.06.010
12. Ormianer Z, Laufer BZ, Nissan J, Gross M: An investigation of heat transfer to the implant-bone interface related to exothermic heat generation during setting of autopolymerizing acrylic resins applied directly to an implant abutment. Int J Oral Maxillofac Implants. 2000, 15:837-42.