

# Mucinous Carcinoma of the Breast: A Case Report

Jayashree Rey<sup>1</sup>, Samarth Shukla<sup>1</sup>, Sourya Acharya<sup>2</sup>, Pravin Gadkari<sup>1</sup>, Sapna Sihag<sup>5</sup>

Received 02/26/2024  
Review began 03/03/2024  
Review ended 03/17/2024  
Published 03/19/2024

© Copyright 2024

Rey et al. This is an open access article distributed under the terms of the Creative Commons Attribution License CC-BY 4.0., which permits unrestricted use, distribution, and reproduction in any medium, provided the original author and source are credited.

1. Pathology, Jawaharlal Nehru Medical College, Datta Meghe Institute of Higher Education and Research, Wardha, IND 2. Medicine, Jawaharlal Nehru Medical College, Datta Meghe Institute of Higher Education and Research, Wardha, IND 3. Biochemistry, Dr. Sampurnanand Medical College, Jodhpur, IND

**Corresponding author:** Jayashree Rey, jayashree1993rey@gmail.com

---

---

## Abstract

This case report presents the diagnostic journey of a 65-year-old female presenting with symptoms suggestive of breast pathology, ultimately diagnosed with mucinous carcinoma, following comprehensive clinical evaluation and histopathological confirmation. Initial assessments indicated a fibroadenoma; however, subsequent histopathological examination revealed mucinous carcinoma, highlighting the importance of histopathological confirmation in establishing definitive diagnoses. The case underscores the challenges in distinguishing between benign and malignant breast lesions based on clinical presentation and imaging findings alone. The multidisciplinary approach facilitated discussions regarding treatment options tailored to the patient's clinical and pathological characteristics. This case emphasizes the significance of a comprehensive diagnostic approach, integrating clinical evaluation, imaging studies, and histopathological analysis, in ensuring accurate diagnosis and guiding optimal management strategies for patients with breast cancer.

**Categories:** Pathology**Keywords:** mucinous carcinoma of breast, treatment, multidisciplinary approach, histopathology, diagnosis, breast cancer

---

## Introduction

Breast cancer is a significant global health concern, affecting millions of women worldwide. Among the various histological subtypes of breast cancer, mucinous carcinoma represents the rare form of breast carcinoma, comprising approximately 2% of all the diagnosed cases of breast cancer [1]. Mucinous breast cancer carries a relatively favorable prognosis with a low recurrence rate and a low incidence of lymph node metastasis [2]. Diagnostic evaluation of breast lesions typically involves a combination of clinical assessment, imaging studies, and histopathological analysis. Ultrasonography (USG) and computed tomography (CT) scans are commonly utilized imaging modalities to assess the size, location, and characteristics of breast lesions [3]. While USG provides high-resolution imaging, CT scans offer detailed anatomical information, aiding in determining tumor extent and involvement of adjacent structures [4].

Histopathological examination remains the gold standard for definitive diagnosis of breast lesions, including mucinous carcinoma. Biopsy specimens obtained through various techniques, such as fine-needle aspiration (FNA) or core needle biopsy, undergo thorough microscopic evaluation to identify cellular abnormalities indicative of malignancy [5]. The Breast Imaging Reporting and Data System (BIRADS) classification system is widely used to standardize reporting and guide management decisions based on imaging findings [6]. Mucinous carcinoma treatment strategies encompass a multidisciplinary approach, incorporating surgery, chemotherapy, radiation therapy, and targeted therapies tailored to individual patient characteristics and disease stages [7]. Early detection and prompt intervention are crucial in improving outcomes and reducing mortality rates, if any, associated with mucinous carcinoma [8].

## Case Presentation

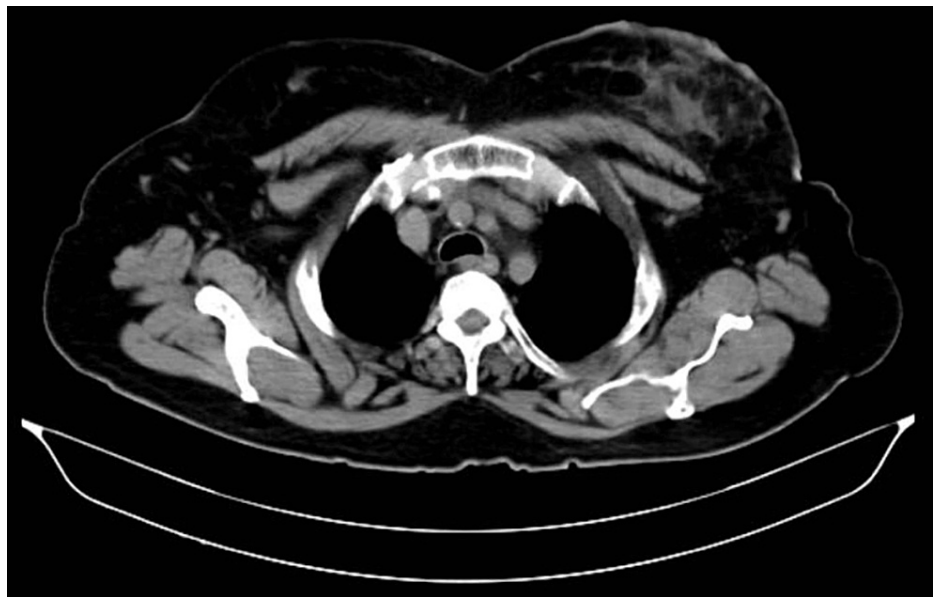
A 65-year-old woman presented to the outpatient department of a specialized hospital with complaints of left breast pain, enlargement, and swelling persisting for two months. She had sought medical attention previously at a local hospital, where she underwent investigations revealing elevated C-reactive protein (CRP) and leukocyte count. Following this, her primary physician referred her to our institution for further evaluation. Upon examination, noticeable enlargement, tenderness, and swelling of the left breast were observed, with no discharge. USG revealed an ill-defined heterogeneously hypoechoic lesion with internal vascularity at the 12 o'clock position in the left breast parenchyma, measuring approximately 3.8 x 1 cm, raising concerns for a neoplastic etiology. Notably, there were no signs of lymphadenopathy.

Considering the findings, a CT scan was recommended for a definitive diagnosis. Subsequently, a contrast-enhanced CT (CECT) scan of the abdomen and pelvis was performed, demonstrating an irregular non-enhancing lesion in the left breast measuring 8.3 x 5.3 x 3.2 cm (Figure 1), involving the skin and retroareolar region. The lesion did not extend to the pectoralis major muscle and showed no evidence of necrosis or calcifications suggestive of malignancy. Post-biopsy changes were noted, along with subtle

### How to cite this article

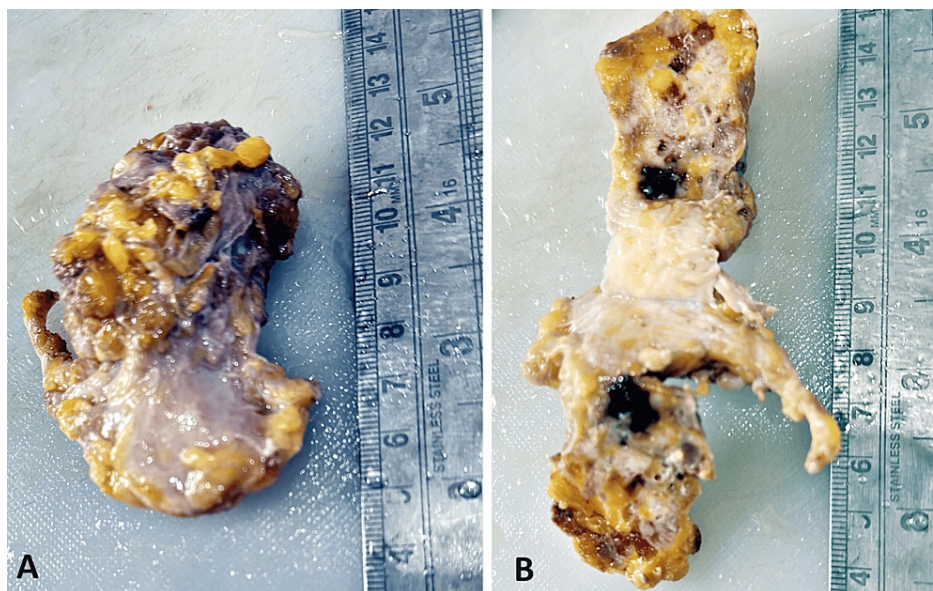
Rey J, Shukla S, Acharya S, et al. (March 19, 2024) Mucinous Carcinoma of the Breast: A Case Report. *Cureus* 16(3): e56515. DOI 10.7759/cureus.56515

enhancement in the bilateral axillary region, more pronounced on the left side. Additionally, degenerative changes were observed in the visualized spine.

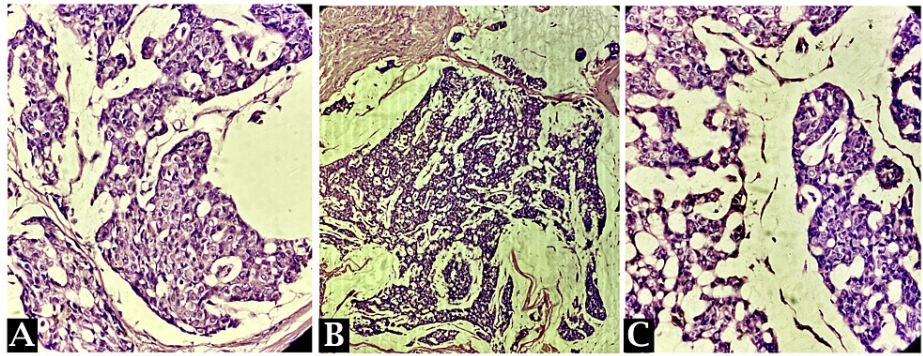


**FIGURE 1:** A contrast-enhanced CT scan of the abdomen and pelvis was performed, demonstrating an irregular non-enhancing lesion in the left breast measuring 8.3 x 5.3 x 3.2 cm.

Following the imaging studies, a USG-guided color Doppler was conducted, and a biopsy of the breast lesion was obtained. Despite initial suspicion of a fibroadenoma, the gross analysis revealed irregular, greyish-yellow fibrofatty tissue with areas of hemorrhage (Figure 2). Further histopathological examination showed features consistent with mucinous carcinoma of the breast (Figure 3). In light of these findings, the patient was diagnosed with mucinous carcinoma of the left breast.



**FIGURE 2:** Irregular, greyish-white fibro fatty tissue piece having a soft glistening appearance.



**FIGURE 3: Clusters/nests of tumor cells floating in pools of extracellular mucin. An intermediate nuclear grade in tumor cell clusters is seen.**

## Discussion

The presented case emphasizes several important clinical and diagnostic considerations in the evaluation of breast lesions, particularly the challenges associated with accurately diagnosing mucinous carcinoma of the breast amidst overlapping clinical and imaging findings. This case underscores the importance of thorough evaluation, including histopathological examination, in accurately diagnosing breast lesions, especially when initial imaging suggests benign pathology. Prompt diagnosis and intervention are critical for optimizing patient outcomes in such cases.

The initial presentation of the 65-year-old female with complaints of pain, breast enlargement, and swelling highlights common symptoms associated with breast pathology, warranting further investigation [9]. In the diagnostic workup, USG and CT scans played pivotal roles in characterizing the lesion, with USG revealing an ill-defined hypoechoic lesion suggestive of a neoplastic etiology [10]. Subsequent CECT provided additional information regarding the extent of the lesion and its involvement with adjacent structures, aiding in the differential diagnosis and treatment planning [11].

Histopathological examination following USG-guided biopsy ultimately confirmed the diagnosis of mucinous carcinoma of the breast, underscoring the importance of tissue analysis in establishing definitive diagnoses [12]. The discrepancy between the initial biopsy findings suggestive of a fibroadenoma and the final histopathological diagnosis of mucinous carcinoma of the breast highlights the inherent limitations of relying solely on imaging and clinical assessments in diagnosing breast lesions [13]. Such discrepancies emphasize the necessity of corroborating imaging findings with histopathological confirmation to guide appropriate management decisions.

The management of mucinous carcinoma typically involves a multidisciplinary approach, integrating surgical resection, chemotherapy, radiation therapy, and targeted therapies based on the tumor characteristics and disease stage [14]. In this case, the diagnosis of mucinous carcinoma prompted discussions regarding treatment options and formulating an individualized treatment plan tailored to the patient's clinical presentation and pathological findings. While the prognosis and long-term outcomes of the patient remain to be determined based on the response to therapy and disease surveillance, the timely diagnosis and initiation of treatment are crucial for optimizing outcomes in patients with mucinous carcinoma [8].

## Conclusions

In conclusion, the presented case of a 65-year-old female underscores the diagnostic challenges inherent in discerning between benign and malignant breast lesions. Despite initial clinical and imaging assessments suggesting a fibroadenoma, subsequent histopathological examination revealed mucinous carcinoma of the breast. This highlights the critical role of histopathological confirmation in establishing definitive diagnoses and guiding appropriate treatment strategies. The multidisciplinary approach facilitated discussions regarding treatment options tailored to the patient's clinical and pathological characteristics. Timely diagnosis and initiation of treatment are paramount in optimizing outcomes for patients with breast cancer. This case emphasizes the importance of a comprehensive diagnostic approach, integrating clinical evaluation, imaging studies, and histopathological analysis to ensure accurate diagnosis and guide optimal management strategies for patients with breast cancer.

## Additional Information

### Author Contributions

All authors have reviewed the final version to be published and agreed to be accountable for all aspects of the work.

**Concept and design:** Jayashree Rey, Samarth Shukla, Sourya Acharya, Pravin Gadkari

**Acquisition, analysis, or interpretation of data:** Jayashree Rey, Sourya Acharya, Pravin Gadkari, Sapna Sihag

**Drafting of the manuscript:** Jayashree Rey, Pravin Gadkari

**Critical review of the manuscript for important intellectual content:** Jayashree Rey, Samarth Shukla, Sourya Acharya, Pravin Gadkari, Sapna Sihag

**Supervision:** Samarth Shukla

## Disclosures

**Human subjects:** Consent was obtained or waived by all participants in this study. **Conflicts of interest:** In compliance with the ICMJE uniform disclosure form, all authors declare the following: **Payment/services info:** All authors have declared that no financial support was received from any organization for the submitted work. **Financial relationships:** All authors have declared that they have no financial relationships at present or within the previous three years with any organizations that might have an interest in the submitted work. **Other relationships:** All authors have declared that there are no other relationships or activities that could appear to have influenced the submitted work.

## Acknowledgements

I would like to express my deep appreciation for the integral role of Artificial Intelligence (AI) like Grammarly and ChatGPT in completing this research paper. Incorporating AI technologies has significantly elevated the efficiency and depth of our analysis, adding a layer of sophistication to our study. By utilizing advanced algorithms and machine learning techniques, we were able to process extensive datasets with unprecedented speed, allowing for a more comprehensive exploration of intricate patterns and trends.

## References

1. DeSantis CE, Ma J, Goding Sauer A, Newman LA, Jemal A: Breast cancer statistics, 2017, racial disparity in mortality by state. *CA Cancer J Clin.* 2017, 67:439-48. [10.3322/caac.21412](https://doi.org/10.3322/caac.21412)
2. Rakha EA, Reis-Filho JS, Baehner F, et al.: Breast cancer prognostic classification in the molecular era: the role of histological grade. *Breast Cancer Res.* 2010, 12:207. [10.1186/bcr2607](https://doi.org/10.1186/bcr2607)
3. Nicosia L, Gnocchi G, Gorini I, et al.: History of mammography: analysis of breast imaging diagnostic achievements over the last century. *Healthcare (Basel).* 2023, 11:1596. [10.3390/healthcare11111596](https://doi.org/10.3390/healthcare11111596)
4. Jeffrey SS, Pollack JR: The diagnosis and management of pre-invasive breast disease: promise of new technologies in understanding pre-invasive breast lesions. *Breast Cancer Res.* 2003, 5:320-8. [10.1186/bcr655](https://doi.org/10.1186/bcr655)
5. Wolff AC, Hammond ME, Hicks DG, et al.: Recommendations for human epidermal growth factor receptor 2 testing in breast cancer: American Society of Clinical Oncology/College of American Pathologists clinical practice guideline update. *J Clin Oncol.* 2013, 31:3997-4013. [10.1200/JCO.2013.50.9984](https://doi.org/10.1200/JCO.2013.50.9984)
6. Breast Imaging Reporting & Data System (BI-RADS®). (2023). Accessed: February 24, 2024; <https://www.acr.org/Clinical-Resources/Reporting-and-Data-Systems/BI-Rads>.
7. Gradishar WJ, Anderson BO, Balassanian R, et al.: Breast cancer, version 4.2017, NCCN Clinical Practice Guidelines in Oncology. *J Natl Compr Canc Netw.* 2018, 16:310-20. [10.6004/jnccn.2018.0012](https://doi.org/10.6004/jnccn.2018.0012)
8. Berry DA, Cronin KA, Plevritis SK, et al.: Effect of screening and adjuvant therapy on mortality from breast cancer. *N Engl J Med.* 2005, 353:1784-92. [10.1056/NEJMoa050518](https://doi.org/10.1056/NEJMoa050518)
9. Breast cancer signs and symptoms. (2023). Accessed: February 24, 2024; <https://www.cancer.org/cancer/types/breast-cancer/screening-tests-and-early-detection/breast-cancer-signs-and-symptom...>
10. Meucci R, Pistolesi Chiara A, Perretta T, et al.: MR imaging-guided vacuum assisted breast biopsy: radiological-pathological correlation and underestimation rate in pre-surgical assessment. *Eur J Radiol Open.* 2020, 7:100244. [10.1016/j.ejro.2020.100244](https://doi.org/10.1016/j.ejro.2020.100244)
11. Heller SL, Heacock L, Moy L: Developments in breast imaging: update on new and evolving MR imaging and molecular imaging techniques. *Magn Reson Imaging Clin N Am.* 2018, 26:247-58. [10.1016/j.mric.2017.12.003](https://doi.org/10.1016/j.mric.2017.12.003)
12. Wolff AC, Hammond ME, Allison KH, et al.: Human epidermal growth factor receptor 2 testing in breast cancer: American Society of Clinical Oncology/College of American Pathologists clinical practice guideline focused update. *Arch Pathol Lab Med.* 2018, 142:1364-82. [10.5858/arpa.2018-0902-SA](https://doi.org/10.5858/arpa.2018-0902-SA)
13. Elezaby M, Li G, Bhargavan-Chatfield M, Burnside ES, DeMartini WB: ACR BI-RADS assessment category 4 subdivisions in diagnostic mammography: utilization and outcomes in the National Mammography Database. *Radiology.* 2018, 287:416-22. [10.1148/radiol.2017170770](https://doi.org/10.1148/radiol.2017170770)
14. Gradishar WJ, Anderson BO, Balassanian R, et al.: Invasive breast cancer version 1.2016, NCCN Clinical Practice Guidelines in Oncology. *J Natl Compr Canc Netw.* 2016, 14:324-54. [10.6004/jnccn.2016.0037](https://doi.org/10.6004/jnccn.2016.0037)