Cureus

Open Access Case Report

DOI: 10.7759/cureus.48950

Patellar Dislocation Masking a Tibial Post Fracture: An Unusual Complication of Posterior Stabilized Total Knee Arthroplasty

Aditya Seth [1], Pranav K. Buddhapuram [1], Arvind Kadwad [1], Sandeep Boddeda [1], Ratnakar Vecham [1], Adarsh Annapareddy [1], A.V. Gurava Reddy [1]

1. Department of Orthopedics, KIMS-Sunshine Hospital, Hyderabad, IND

Corresponding author: Arvind Kadwad, arvindkk287@gmail.com

Review began 11/07/2023
Review ended 11/11/2023
Published 11/17/2023

© **Copyright** 2023
Seth et al. This is an open access article distributed under the terms of the Creative Commons Attribution License CC-BY 4.0., which permits unrestricted use, distribution, and reproduction in any medium, provided the original author and source are credited.

Abstract

Posterior stabilized total knee arthroplasty (TKA) has established itself as a highly effective design for total knee arthroplasty, renowned for its longevity and success. However, a subset of cases, approximately 6-12%, faces early failure, necessitating revision procedures. This case report presents a unique and previously undocumented complication involving a tibial post fracture following hyperflexion of the knee, masked by chronic patellar dislocation. This case highlights the importance of considering polyethylene wear-related failure in cases of instability without an apparent history of trauma. The surgical intervention involved polyethylene insert exchange, patellar debulking, lateral retinacular release, and quadriceps tendon double-breasting.

Categories: Orthopedics, Trauma
Keywords: posterior stabilized knee, cam and post, polyethylene post breakage, arthroplasty complication, chronic patella dislocation, arthroplasty, tibial post fracture

Introduction

The posterior stabilized total knee arthroplasty (TKA) implant stands out as one of the remarkably successful designs within the realm of total knee arthroplasty, and its efficacy is well-documented in the literature [1-3]. Over time, it has garnered recognition as the gold standard for ensuring the longevity of TKA procedures [2].

The foundation of this design lies in its role as a posterior cruciate ligament-substituting implant, where the native posterior cruciate ligament (PCL) is effectively replaced by a tibial post and femoral cam mechanism [3,4]. This construct facilitates femoral roll-back during knee flexion while effectively averting posterior tibial subluxation throughout the flexion process [4].

Nevertheless, it is crucial to recognize that despite the overall success of primary TKAs, a notable subset of cases, approximately 6-12%, encounters failure within the first decade post-surgery, necessitating revision procedures [5]. Remarkably, there is limited literature addressing polyethylene insert fracture being masked by patellar subluxation and instability.

In the present case, we draw attention to an exceptionally rare complication; the occurrence of a tibial post fracture following hyperflexion of the knee masquerading as patellar dislocation, several years after the patient's initial posterior stabilized total knee arthroplasty. To the best of our knowledge, this specific presentation and fracture concurrently has not been previously documented in the existing medical literature.

Case Presentation

A 61-year-old female patient presented to our outpatient department (OPD) with complaints of a clicking sensation in her right knee and a feeling of instability. She had undergone bilateral simultaneous total knee replacement surgery with Stryker NRG implants (Stryker Orthopedics, Kalamazoo, MI, USA) approximately eight years prior. Figure *1* shows the patient's preoperative radiograph and Figure *2* shows the three-month postoperative radiograph.

How to cite this article
Seth A, Buddhapuram P K, Kadwad A, et al. (November 17, 2023) Patellar Dislocation Masking a Tibial Post Fracture: An Unusual Complication of Posterior Stabilized Total Knee Arthroplasty. Cureus 15(11): e48950. DOI 10.7759/cureus.48950

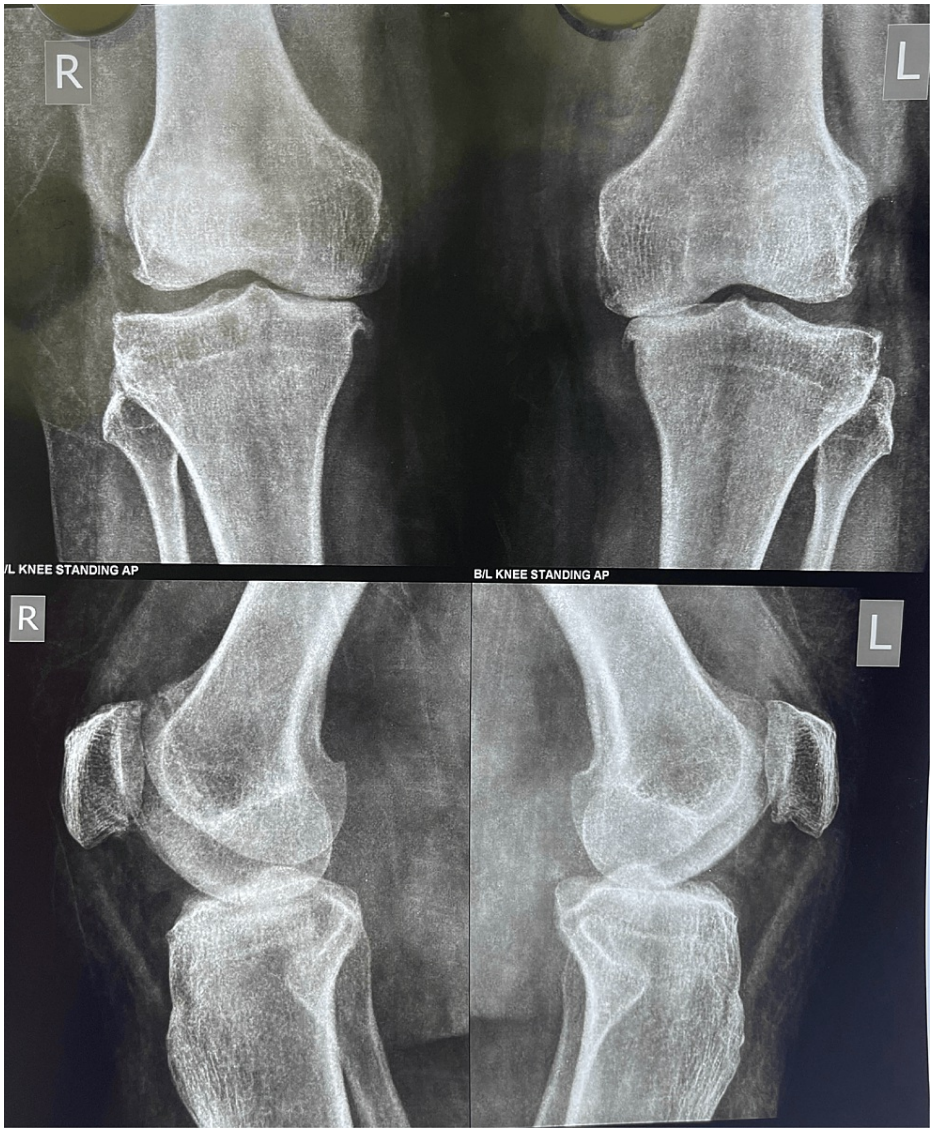

FIGURE 1: Preoperative radiograph showing a varus deformity with severe osteoarthritis over the medial side in both knees

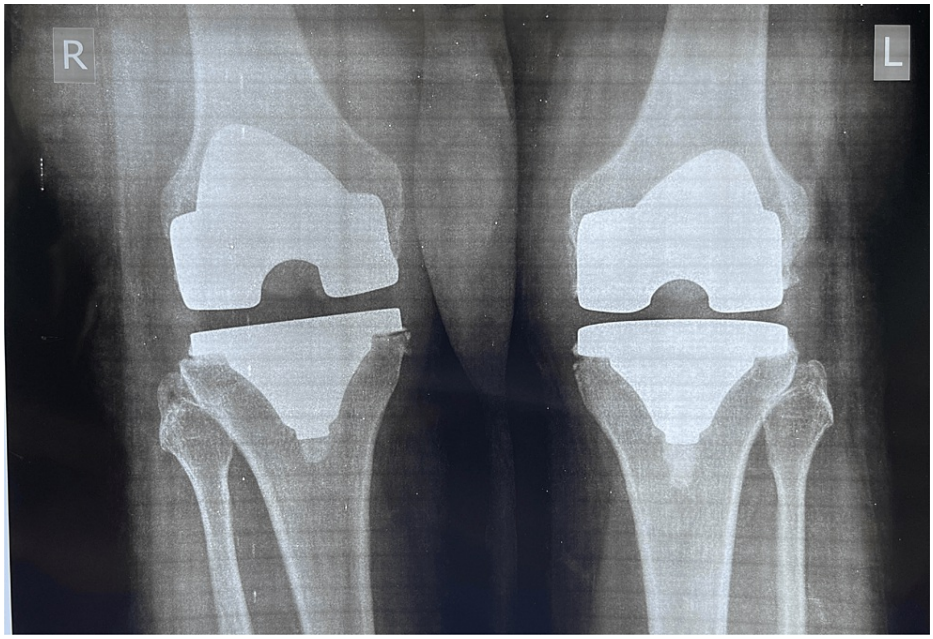

FIGURE 2: Three months postoperative weight-bearing radiograph showing well-balanced knees

The patient's medical history was devoid of any traumatic events. She did, however, recount an incident where she hyperflexed her right knee during a religious ritual. This event was followed by pronounced swelling, pain, and a temporary inability to bear weight on the affected leg. During our initial consultation, the patient did not mention any auditory phenomena associated with the hyperflexion incident. However, upon subsequent probing after surgery, she revealed that she had heard a distinct audible pop sound during the episode.

Upon initial examination, the patient's patella exhibited dislocation on the right side. The evaluation revealed grade 2 instability in the anteroposterior plane, with no evidence of varus-valgus instability. Radiographs were obtained, which confirmed the finding as shown in Figures *3*, *4*.

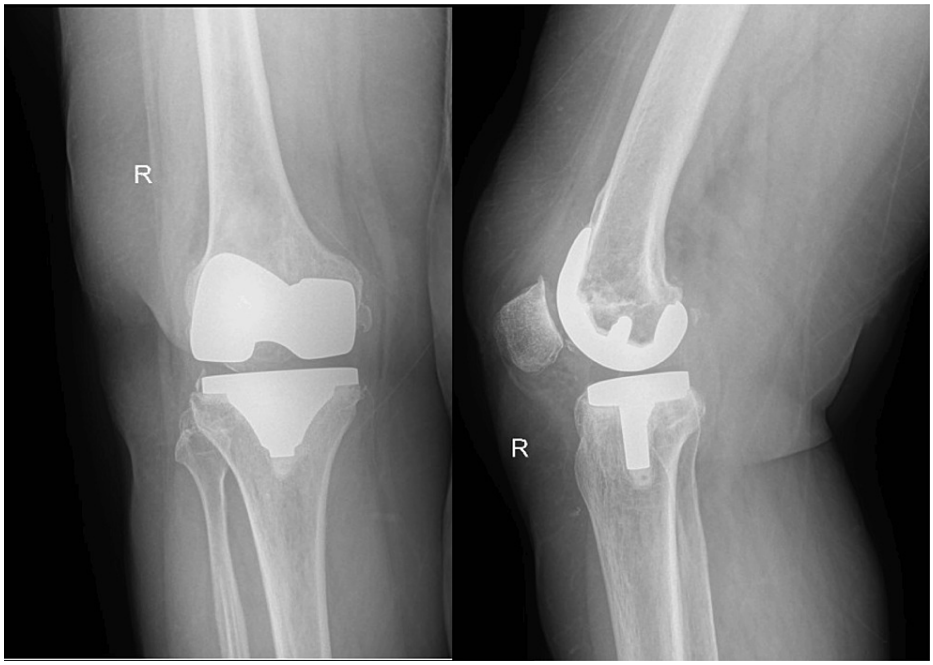

FIGURE 3: The anteroposterior and lateral views of the knee in the standing position

These radiographs show a well-balanced knee; however, the patella position couldn't be commented on in these radiographs.

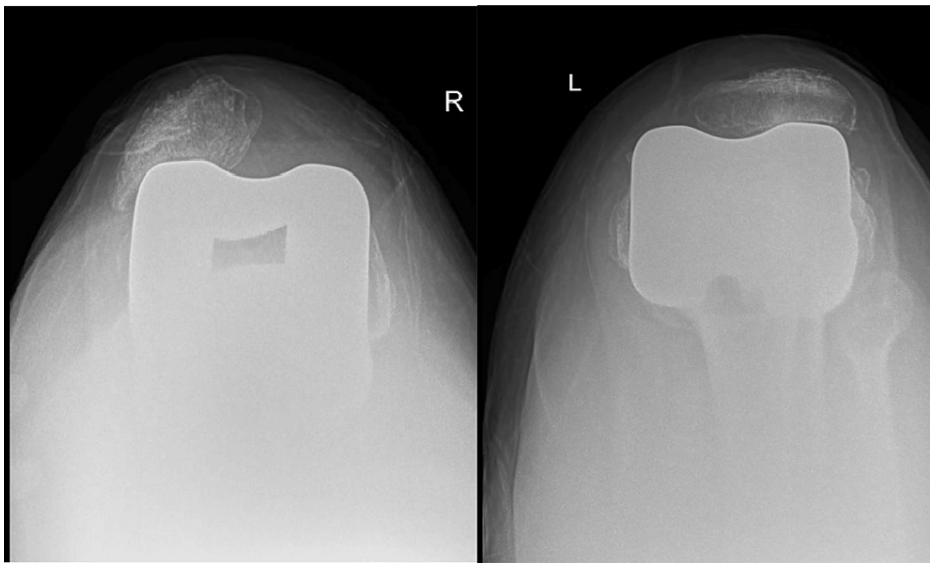

FIGURE 4: Skyline view of the knee with a patellar dislocation on the right side

The patient exhibited no clinical signs of infection, as indicated by her blood parameters within the normal range (erythrocyte sedimentation rate (ESR) - 16 mm/hr, C-reactive protein (CRP) - 0.30 mg/dL, total leucocyte count (TLC) - 6,600 cells/cumm).

In the course of the clinical assessment, the clicking sounds were linked to the patellar dislocation, which was also evident in the radiographs taken at the time of presentation. This prompted the decision to schedule a surgical procedure for patellar realignment.

Following the administration of anesthesia, flexion of the knee patellar dislocation was evident as shown in

Figure 5.



FIGURE 5: Dislocation of the patella upon flexion of the knee after the administration of anesthesia

However, upon conducting an arthrotomy, an unforeseen complication emerged, as the tibial post was identified as fractured, as seen in Figure 6, concomitant with an increase in the flexion and extension gaps.

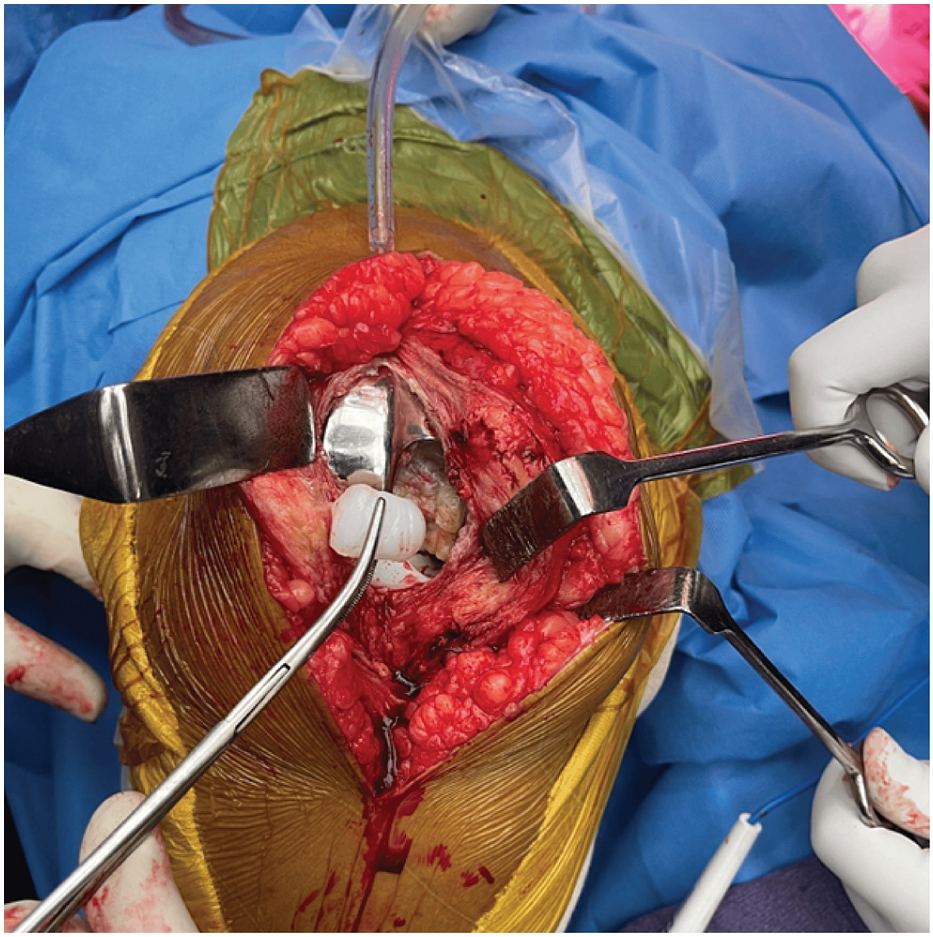

FIGURE 6: Tibial post fracture

The polyethylene insert was replaced with a larger 15mm size from 12mm due to an increase in both flexion and extension gaps. Additionally, debulking of the patella along with the removal of osteophytes followed by lateral retinaculum release and double-breasting technique was employed for the quadriceps tendon.

Subsequent to the surgical procedure, a radiograph was taken postoperatively as shown in Figure *7* and the patient received post-operative instructions, advising a range of motion of up to 30 degrees, with the prescription of a long knee brace to facilitate full weight-bearing. This comprehensive approach aimed at restoring the patient's knee functionality and mitigating her symptoms effectively.

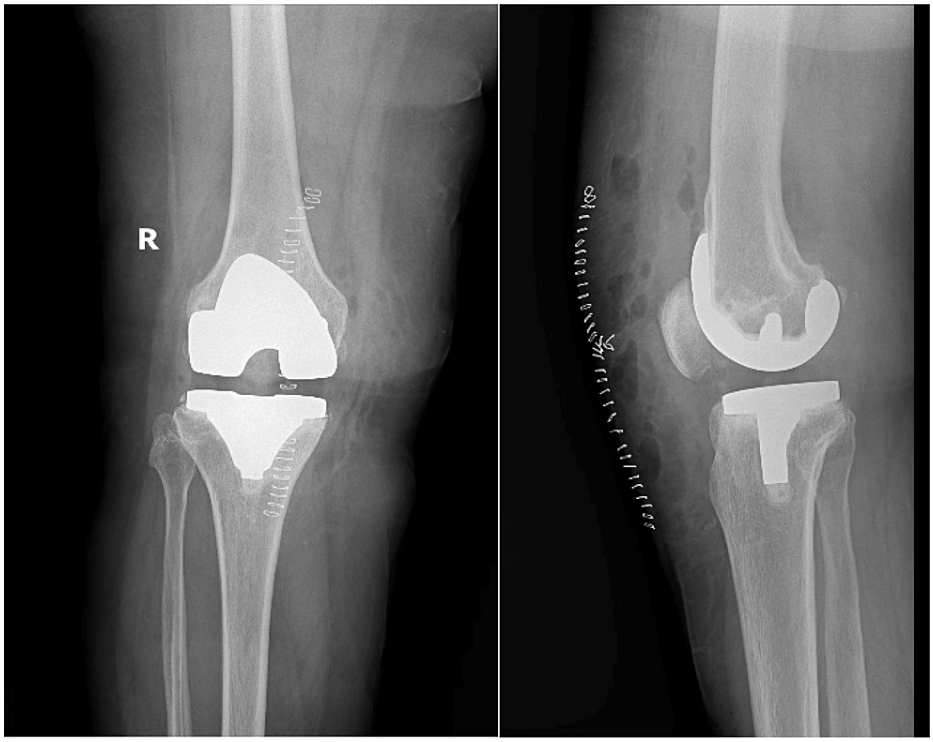

FIGURE 7: Postoperative radiograph of the right knee in the supine position

Discussion

In our presented case, a significant observation was the chronic patella dislocation on the patient's right side and subluxation of the patella on the left side. This is further corroborated by the evident contouring of the lateral facet, which, when analyzed in conjunction with the femoral component on the skyline view, offers a clear indication of the dislocation's chronic nature as shown in Figure *3*. Such findings emphasize the importance of thorough radiographic examinations in assessing the nuances of knee pathologies and understanding their potential implications.

Patellar stability is contingent upon several critical factors, including precise implant positioning, optimal soft-tissue balance, accurate bone resections, and the design of femoral and patellar components that are conducive to patellar health. Among these considerations, the design of femoral components assumes particular significance. Femoral components characterized by a shallow and symmetric trochlear groove, featuring abrupt changes in sagittal radius, have the potential to disrupt normal patellar kinematics and heighten the risk of patellar maltracking [6-8].

Surgical inaccuracies frequently underlie issues related to patellar instability. These inaccuracies encompass residual valgus limb malalignment, patella alta (an elevated patella), an increased internal rotation of either the femoral or tibial component, medial translation of the femoral component, excessive valgus alignment of the femoral component, asymmetric patellar resection, lateral positioning of the patellar button, and excessive patellar thickness [7-9]. These factors collectively play a substantial role in patellar stability and underscore the significance of precision in implant design and surgical execution.

Previous studies have extensively documented the occurrence of wear and failure of the tibial post, as presented in Table *1* [10]. The literature suggests a multitude of factors [11-15] that contribute to the wear and erosion of the tibial post. One such factor includes the increased posterior slope of the tibial baseplate, which may lead to premature and less-than-ideal contact between the femoral component and the post. Additionally, the rotation of the femoral component has been identified as a potential contributor to tibial post failure, particularly when it results in edge loading on non-rounded posts and cams. Another aspect to consider is the excessive flexion of the femoral component, which may precipitate cam post-impingement.

Furthermore, the wear of the tibial post is influenced by dynamic physiological conditions, specifically the velocity at which the post-cam engagement occurs and the angle of flexion during engagement [16]. In the most severe instances, complete erosion of the tibial post has been observed. Moreover, although infrequent, a significant complication that has been noted is the fracture of the tibial post. Such fractures are rare, occurring in less than 1% of cases, but they are often associated with wear and deformation of the

post [17-20].

Study	Year	Mode of Failure	Diagnosis	Comments
Ip et al. [21]	2004	Atraumatic	Patella clunk syndrome	The IB II prosthesis (PS design) is especially prone to cause patella clunk syndrome
Jung et al. [22]	2009	Atraumatic	Tibial post-fracture	Hard mass palpable in the suprapatellar pouch
Kumar et al. [18]	2015	Atraumatic	Tibial post-fracture and polywear	Complaint of pain and swelling, locking, and clicking sensation
Lim et al. [19]	2009	Traumatic	Tibial post-fracture and polywear	Pain, effusion, genu recurvatum, patella fracture, and soft endpoints on varus-valgus stress test
Bal et al. [4]	2008	Traumatic/Atraumatic	Tibial post-delamination	Excessive femoral component flexion, anterior positioning of the tibial tray, excessive posterior tibial slope, and joint line alterations of 8 mm or greater can predispose to anterior tibial post-impingement and failure
Clarke et al. [23]	2004	Traumatic	Tibial post-fracture	Calf pain, swelling, locking sensation

TABLE 1: Tibial post complications reported in the literature in posterior-stabilized total knee arthroplasty

As depicted in the case report, it becomes evident that tibial post failure following TKA can occur in the absence of any obvious history of trauma or falls. In our case, it happened after hyperflexion of the knee. However, in our case, the evident patellar dislocation masqueraded as the tibial post fracture. To the best of our knowledge, no such case report has been previously reported in the literature.

When confronted with cases of instability and chronic patellar dislocation in the absence of documented trauma, it is incumbent upon surgeons to consider the potential contribution of polyethylene wear-related failure.

Conclusions

In summary, this case report sheds light on an exceptional and rarely encountered scenario in the realm of knee arthroplasty. The occurrence of a tibial post fracture, initially concealed by chronic patellar dislocation, presents a diagnostic challenge. Such a presentation, with concurrent patellar instability and tibial post fracture, has not been previously documented in medical literature. Surgeons should be alert to the possibility of polyethylene wear-related failure in cases of unexplained instability, even in the absence of apparent traumatic events. Timely recognition and appropriate intervention can lead to successful outcomes and improved patient quality of life. This case serves as a reminder of the complexities that can arise in knee arthroplasty and highlights the need for comprehensive evaluation and meticulous surgical management when faced with atypical clinical presentations.

Additional Information

Author Contributions

All authors have reviewed the final version to be published and agreed to be accountable for all aspects of the work.

Concept and design: Pranav K. Buddhapuram, Aditya Seth, Sandeep Boddeda, Ratnakar Vecham

Drafting of the manuscript: Pranav K. Buddhapuram, Aditya Seth, Arvind Kadwad, Sandeep Boddeda

Critical review of the manuscript for important intellectual content: Aditya Seth, Arvind Kadwad, Sandeep Boddeda, Ratnakar Vecham, Adarsh Annapareddy, A.V. Gurava Reddy

Acquisition, analysis, or interpretation of data: Arvind Kadwad, Sandeep Boddeda, Ratnakar Vecham, Adarsh Annapareddy, A.V. Gurava Reddy

Supervision: Sandeep Boddeda, Ratnakar Vecham, Adarsh Annapareddy, A.V. Gurava Reddy

Disclosures

Human subjects: Consent was obtained or waived by all participants in this study. **Conflicts of interest:** In compliance with the ICMJE uniform disclosure form, all authors declare the following: **Payment/services info:** All authors have declared that no financial support was received from any organization for the submitted work. **Financial relationships:** All authors have declared that they have no financial relationships at present or within the previous three years with any organizations that might have an interest in the submitted work. **Other relationships:** All authors have declared that there are no other relationships or activities that could appear to have influenced the submitted work.

References

1. Ritter MA, Campbell E, Faris PM, et al.: Long term survival analysis of posterior cruciate condylar total knee arthroplasty. A 10 year evaluation. J Arthroplasty. 1989, 4:293. 10.1016/s0883-5403(89)80029-4
2. Colizza WA, Insall JN, Scuderi GR: The posterior stabilized total knee prosthesis. Assessment of polyethylene damage and osteolysis after a ten-year-minimum follow-up. J Bone Joint Surg Am. 1995, 77:1713-20. 10.2106/00004623-199511000-00011
3. Dorr LD, Ochsner JL, Gronley J, Perry J: Functional comparison of posterior cruciate-retained versus cruciate-sacrificed total knee arthroplasty. Clin Orthop Relat Res. 1988, 36-43.
4. Bal BS, Greenberg D, Li S, R Mauerhan D, Schultz L, Cherry K: Tibial post failures in a condylar posterior cruciate substituting total knee arthroplasty. J Arthroplasty. 2008, 23:650-5. 10.1016/j.arth.2007.08.002
5. Klika AK, Higuera C, Barsoum WA, Siqueira MBP: Modes of failure of total knee arthroplasty: registries and realities. J Knee Surg. 2015, 28:127-38.
6. Theiss SM, Kitziger KJ, Lotke PS, Lotke PA: Component design affecting patellofemoral complications after total knee arthroplasty. Clin Orthop Relat Res. 1996, 326:183-7. 10.1097/00003086-199605000-00021
7. Yoshii I, Whiteside LA, Anouchi YS: The effect of patellar button placement and femoral component design on patellar tracking in total knee arthroplasty. Clin Orthop Relat Res. 1992, 211-9.
8. Petersilge WJ, Oishi CS, Kaufman KR, Irby SE, Colwell CW Jr: The effect of trochlear design on patellofemoral shear and compressive forces in total knee arthroplasty. Clin Orthop Relat Res. 1994, 124-30.
9. Rand JA: Failures in patellar replacement in total knee arthroplasty . Total Knee Arthroplasty. Bellemans J, Ries MD, Victor JMK (ed): Springer, Berlin; 2005. 57-64.
10. Shah S, Mulpur P, Vecham R, Jayakumar T, Hippalgaonkar K: Erosion and failure of the tibial post after posterior-stabilized total knee replacement: a case report. J Orthop Case Rep. 2023, 13:127-31. 10.13107/jocr.2023.v13.i10.3962
11. Furman BD, Lipman J, Kligman M, Wright TM, Haas SB: Tibial post wear in posterior-stabilized knee replacements is design-dependent. Clin Orthop Relat Res. 2008, 466:2650-5. 10.1007/s11999-008-0422-1
12. Puloski SK, McCalden RW, MacDonald SJ, Rorabeck CH, Bourne RB: Tibial post wear in posterior stabilized total knee arthroplasty. An unrecognized source of polyethylene debris. J Bone Joint Surg Am. 2001, 83:390-7. 10.2106/00004623-200103000-00011
13. Pang HN, Bin Abd Razak HR, Jamieson P, Teeter MG, Naudie DD, MacDonald SJ: Factors affecting wear of constrained polyethylene tibial inserts in total knee arthroplasty. J Arthroplasty. 2016, 31:1340-5. 10.1016/j.arth.2015.12.011
14. Dolan MM, Kelly NH, Nguyen JT, Wright TM, Haas SB: Implant design influences tibial post wear damage in posterior-stabilized knees. Clin Orthop Relat Res. 2011, 469:160-7. 10.1007/s11999-010-1515-1
15. Mihalko WM, Lowell J, Higgs G, Kurtz S: Total knee postcam design variations and their effects on kinematics and wear patterns. Orthopedics. 2016, 39:S45-9. 10.3928/01477447-20160509-14
16. Fitzpatrick CK, Clary CW, Cyr AJ, Maletsky LP, Rullkoetter PJ: Mechanics of post-cam engagement during simulated dynamic activity. J Orthop Res. 2013, 31:1438-46. 10.1002/jor.22366
17. Lachiewicz PF: How to treat a tibial post fracture in total knee arthroplasty? A systematic review . Clin Orthop Relat Res. 2011, 469:1709-15. 10.1007/s11999-010-1609-9
18. Kumar N, Yadav C, Raj R, Yadav S: Fracture of the polyethylene tibial post in a posterior stabilized knee prosthesis: a case report and review of literature. J Orthop. 2015, 12:160-3. 10.1016/j.jor.2015.01.002
19. Lim HC, Bae JH, Hwang JH, Kim SJ, Yoon JY: Fracture of a polyethylene tibial post in a Scorpio posterior-stabilized knee prosthesis. Clin Orthop Surg. 2009, 1:118-21. 10.4055/cios.2009.1.2.118
20. D'Angelo F, Marcolli D, Bulgheroni P, Murena L, Congiu T, Cherubino P: Two stage fracture of a polyethylene post in a 9-year-old posterior-stabilized knee prosthesis: a case report. J Med Case Rep. 2010, 4:65. 10.1186/1752-1947-4-65
21. Ip D, Ko PS, Lee OB, Wu WC, Lam JJ: Natural history and pathogenesis of the patella clunk syndrome . Arch Orthop Trauma Surg. 2004, 124:597-602. 10.1007/s00402-003-0533-9
22. Jung KA, Lee SC, Hwang SH, Kim SM: Fractured polyethylene tibial post in a posterior-stabilized knee prosthesis presenting as a floating palpable mass. J Knee Surg. 2009, 22:374-6. 10.1055/s-0030-1247780
23. Clarke HD, Math KR, Scuderi GR: Polyethylene post failure in posterior stabilized total knee arthroplasty . J Arthroplasty. 2004, 19:652-7. 10.1016/j.arth.2004.02.026