Cureus

Open Access Case Report

DOI: 10.7759/cureus.48810

Corrected: A Not-So-Sweet Syndrome: A Case Report of a Male Presenting With Acute Febrile Neutrophilic Dermatosis

Review began 10/15/2023
Review ended 11/06/2023
Published 11/14/2023
Corrected 11/21/2023

© **Copyright** 2023
Nguyen et al. This is an open access article distributed under the terms of the Creative Commons Attribution License CC-BY 4.0., which permits unrestricted use, distribution, and reproduction in any medium, provided the original author and source are credited.

Kim-Long R. Nguyen [1] , Aaron J. Lacy [1] , SueLin Hilbert [1] , Rosanne S. Naunheim [1]

1. Emergency Medicine, Washington University School of Medicine, St. Louis, USA

Corresponding author: Aaron J. Lacy, aaronjlacy@gmail.com

This article has been corrected.

Correction date: November 21, 2023. Cite this correction as Nguyen K R, Lacy A J, Hilbert S, et al. (November 21, 2023) Correction: A Not-So-Sweet Syndrome: A Case Report of a Male Presenting With Acute Febrile Neutrophilic Dermatosis. Cureus 15(11): c145. doi:10.7759/cureus.c145.

This article has been corrected to clarify that Figure 3 is not original to the case and is meant to serve only as an example of Sweet syndrome histopathology. The paragraph preceding Figure 3 has been updated to make this clear and the figure attribution and license information has been moved from the reference list to the Figure 3 description.

Abstract

Physicians often encounter patients who present with a chief complaint of skin changes or lesions in both acute and primary care settings. Early initiation of appropriate treatment and pharmacotherapy in patients who present with rash is crucial to prevent decompensation, morbidity, and further downstream utilization of hospital resources. Acute febrile neutrophilic dermatosis, more commonly known as Sweet syndrome, is a rare and highly symptomatic inflammatory skin condition. Early recognition of Sweet syndrome is important as it requires specific treatment considerations and often can be a sign of an underlying pro-inflammatory condition, malignancy, or reaction to new medication that must be identified. This article discusses the presentation and management of a 50-year-old male who presented with a classic presentation of Sweet syndrome.

Categories: Dermatology, Emergency Medicine, Allergy/Immunology
Keywords: corticosteroid therapy, skin biopsy, acute febrile neutrophilic dermatosis, skin lesion, dermatology, sweet syndrome

Introduction

Physicians in the acute care setting often encounter patients who present with skin changes or lesions. The recognition of concerning rashes and skin changes is important for physicians to understand as mis-triage and misdiagnosis of these patients can have a range of consequences, ranging from poor patient outcomes to overutilization of hospital resources. In patients with skin changes, appropriate therapy initiation is crucial in those who are at risk of decompensation, are highly symptomatic, or may have a serious underlying medical condition manifesting as a skin finding. Acute febrile neutrophilic dermatosis, also termed Sweet syndrome, is a rare inflammatory skin condition that has been observed in association with pro-inflammatory conditions, hematologic or oncologic malignancy, and the initiation of new medications [1,2].

Case Presentation

A 50-year-old male presented to the emergency department (ED) for skin lesions. His medical history was notable for chronic obstructive pulmonary disease, hepatitis C, and end-stage renal disease on dialysis. The painful lesions appeared one week prior to his presentation, and he was initially seen at another hospital where he was treated with intravenous antibiotics. Subsequently, his lesions enlarged and spread diffusely, prompting him to represent to the ED.

On examination, he had normal vital signs and appeared uncomfortable. Skin examination was notable for polymorphic, raised, hemorrhagic, and bullous skin lesions with heaped margins across the body, including his intraoral mucosa (Figure *1*). The lesions were Nikolsky sign negative and spared the palms and soles (Figure *2*). At the time of evaluation in the ED, monkeypox, herpes simplex virus, varicella-zoster virus, blood cultures, gonorrhea/chlamydia, human immunodeficiency virus (HIV), rapid plasma reagin (RPR), and hepatitis panel testing were initiated. Ultimately, all were negative, except for a positive hepatitis C RNA result. Other notable results included a white blood cell count of 5,000/µL and a C-reactive protein of 159 mg/L. Given the concern about systemic and highly symptomatic skin changes, which could indicate

concurrent infection or underlying occult disease process, he was admitted for further evaluation and empirically started on both broad-spectrum antibiotics and high-dose intravenous steroids.



FIGURE 1: Raised, erythematous, painful, Nikolsky-negative, hemorrhagic skin lesions of the oral mucosa and extremities



FIGURE 2: Raised, erythematous, painful, Nikolsky-negative, hemorrhagic, bullous skin lesions of the hands that spared the palms

Workup for underlying infectious, autoimmune, and oncologic disease processes by the inpatient team included cryptococcal antigens, blastomyces antibodies, histoplasma antibodies, screening computed tomography of the chest, abdomen, and pelvis, and microorganism testing of a lesion biopsy. Ultimately, these tests were negative, and skin biopsy demonstrated collections of neutrophils in the upper dermis with fibrinoid change of capillary-sized vessels, with negative microorganism testing, consistent with a diagnosis of acute febrile neutrophilic dermatosis, also termed Sweet syndrome. An example of Sweet syndrome histopathology can be seen below (Figure *3*). Please note that this figure is not from this case. His antibiotics were discontinued, and treatment with 1 mg/kg of prednisone was initiated. Ultimately, after significant symptom improvement during his four-day hospital course, he was discharged with an oral prednisone taper and specialty follow-up arranged.

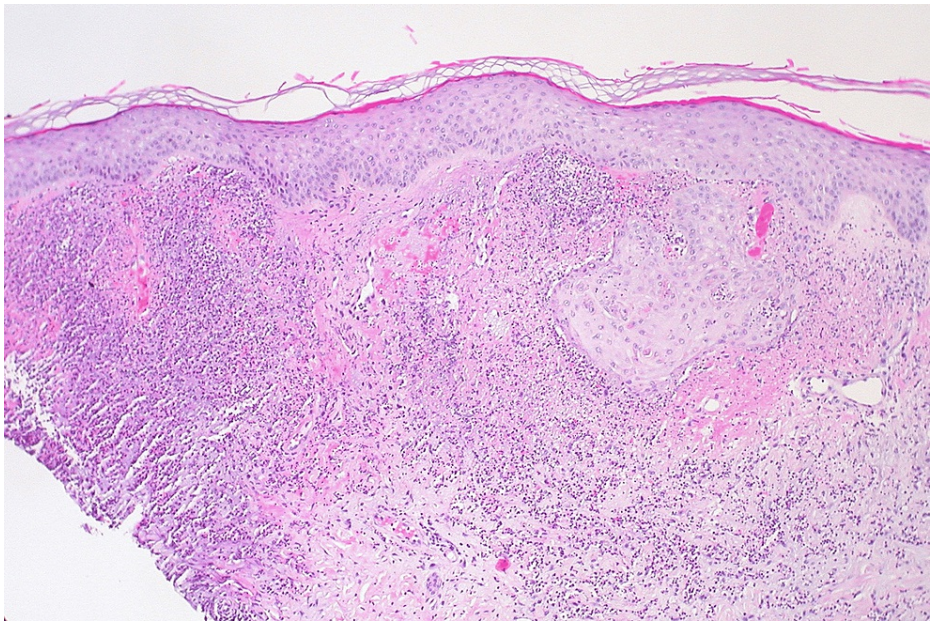

FIGURE 3: Example histopathology slide of a patient's skin biopsy showing neutrophils in the upper dermis with fibrinoid change of capillary-sized vessels consistent with a diagnosis of Sweet syndrome

Figure reproduced via Creative Commons Attribution 2.0 Generic license courtesy of Ed Uthman: https://commons.wikimedia.org/wiki/File:Sweet_Syndrome_(neutrophilic_dermatosis)_(4703671002).jpg

Discussion

Physicians in the acute care setting often see patients who present with skin findings of undetermined origin. It is crucial for providers to recognize when a skin condition requires immediate treatment and further inpatient management or is a sign of a possible occult disease process. Misdiagnosis can lead to improper treatment initiation, increased morbidity due to delay in treatment, or failure to recognize a serious, occult disease process requiring intervention. Sweet syndrome is one such condition, as it is often associated with underlying infection or malignancy [1]. Sweet syndrome was first described in 1964 by Robert Sweet after describing eight cases of skin eruptions similar to erythema multiforme associated with fever.

The diagnosis of Sweet syndrome includes major criteria (abrupt onset of painful erythematous plaques and/or nodules, and histopathologic evidence of dense neutrophilic infiltrate without evidence of leukocytoclastic vasculitis) and two of four minor criteria (fever, known malignancy or infection, elevated inflammatory markers, and/or excellent response to systemic steroids) [1-4]. High-dose corticosteroid therapy is the first-line treatment, with topical or intralesional injections suggested for mild disease and systemic treatment for extensive/systemic disease. Colchicine, dapsone, and potassium iodide are less frequently used but also utilized [1,3]. Our patient had the rare bullous form of Sweet syndrome, which is often associated with an underlying hematologic malignancy. Fortunately, a workup for underlying malignancy was non-revealing. In this patient, early initiation of high-dose intravenous steroids ultimately resulted in a suitable outcome, with a substantial reduction in symptoms and improvement in skin findings noted on follow-up with dermatology.

Conclusions

This is a case of a patient who presented with Sweet syndrome. Sweet syndrome often presents with both skin changes and fever, which can mimic cellulitis, prompting physicians to start empiric antibiotics. Early recognition of this disease process is important, as the treatment is steroids, not antibiotics. Importantly, providers should be aware that Sweet syndrome is commonly associated with underlying inflammatory conditions and malignancy and should prompt a thorough workup and evaluation of patients who have the disease process confirmed or suspected.

Additional Information

Author Contributions

All authors have reviewed the final version to be published and agreed to be accountable for all aspects of the

work.

Concept and design: Aaron J. Lacy, Kim-Long R. Nguyen, Rosanne S. Naunheim

Acquisition, analysis, or interpretation of data: Aaron J. Lacy, Kim-Long R. Nguyen, SueLin Hilbert, Rosanne S. Naunheim

Drafting of the manuscript: Aaron J. Lacy, Kim-Long R. Nguyen, Rosanne S. Naunheim

Critical review of the manuscript for important intellectual content: Aaron J. Lacy, Kim-Long R. Nguyen, SueLin Hilbert, Rosanne S. Naunheim

Supervision: Aaron J. Lacy, Rosanne S. Naunheim

Disclosures

Human subjects: Consent was obtained or waived by all participants in this study. **Conflicts of interest:** In compliance with the ICMJE uniform disclosure form, all authors declare the following: **Payment/services info:** All authors have declared that no financial support was received from any organization for the submitted work. **Financial relationships:** All authors have declared that they have no financial relationships at present or within the previous three years with any organizations that might have an interest in the submitted work. **Other relationships:** All authors have declared that there are no other relationships or activities that could appear to have influenced the submitted work.

References

1. Ferea CR, Mihai SN, Balan G, Badescu MC, Tutunaru D, Tatu AL: Sweet syndrome associated with myelodysplastic syndrome-a review of a multidisciplinary approach. Life (Basel). 2023, 13:10.3390/life13030809
2. White JM, Mufti GJ, Salisbury JR, du Vivier AW: Cutaneous manifestations of granulocyte colony-stimulating factor. Clin Exp Dermatol. 2006, 31:206-7. 10.1111/j.1365-2230.2005.01996.x
3. von den Driesch P: Sweet's syndrome (acute febrile neutrophilic dermatosis). J Am Acad Dermatol. 1994, 31:535-56. 10.1016/s0190-9622(94)70215-2
4. Cohen PR, Kurzrock R: Sweet's syndrome: a review of current treatment options . Am J Clin Dermatol. 2002, 3:117-31. 10.2165/00128071-200203020-00005