

The Abscopal Effect Exists in Non-small Cell Lung Cancer: A Case Report and Review of the Literature

Jacob Bitran ¹

1. Oncology, Advocate Lutheran General Hospital, Park Ridge, USA

✉ **Corresponding author:** Jacob Bitran, jbitran@oncmed.net

Disclosures can be found in Additional Information at the end of the article

Abstract

The case of a 62-year-old woman who presented with stage IV adenocarcinoma of the left lung and a large left adrenal metastasis is presented. Following local radiation therapy to the left lung and nivolumab, she is now disease free 4.5 years from the time of the diagnosis. Five additional cases that have been reported are reviewed. The abscopal effect exists in non-small cell lung cancer (NSCLC) and has been reported with local radiation therapy alone as well as local radiation followed by either nivolumab or ipilimumab. Future randomized studies should address the synergist effects of local radiation therapy and the programmed cell death 1 (PD-1) checkpoint inhibitors versus the PD-1 checkpoint inhibitors alone.

Categories: Radiation Oncology, Oncology

Keywords: abscopal effect, radiation treatment, nivolumab, non-small cell lung cancer, ipilimumab

Introduction

The abscopal effect was described 50 years ago and is a phenomenon in which local radiation therapy is associated with regression of metastatic cancer at a distance from the irradiated site [1-2]. While the conventional wisdom is that locally directed ionizing radiation therapy (RT) induces lethal chromosomal changes and simultaneously activates deoxyribonucleic acid (DNA) damage response pathways [3-4], it is also at the same time immunomodulatory as RT activates nuclear factor-kappa B [5]. Garnett et al. reported that radiation therapy can alter the immunophenotype of cancer [6]. These authors conducted in vitro experiments with human cancer cell lines treated with sublethal radiation therapy and reported upregulation of Fas, intercellular adhesion molecule-1, mucin-1, carcinoembryonic antigen, and major histocompatibility class 1 antigens [6]. Deng and colleagues have reported that ablative radiation activates an immunologic response in that DNA from which irradiated tumor is taken up by antigen presenting cells and in turn induces type 1 interferon production [7]. These experiments support the hypothesis that alterations of the immuno-phenotype may make cancer more immunogenic and cause destruction by activating the person's own immune system.

Pembrolizumab and nivolumab are programmed cell death 1 (PD-1) checkpoint inhibitors that are in clinical use to treat a variety of disseminated or locally advanced cancers including non-small cell lung cancer (NSCLC). These drugs are efficacious and relatively well tolerated. Adverse effects include skin rashes, hypothyroidism, autoimmune colitis, pneumonitis, and endocrinopathies including autoimmune adrenal insufficiency and hypopituitarism.

Ribeiro Gomes et al. [8] published a small study analyzing the abscopal effect coupled with

Received 12/12/2018

Review began 12/13/2018

Review ended 02/17/2019

Published 02/22/2019

© Copyright 2019

Bitran. This is an open access article distributed under the terms of the Creative Commons Attribution License CC-BY 3.0., which permits unrestricted use, distribution, and reproduction in any medium, provided the original author and source are credited.

How to cite this article

Bitran J (February 22, 2019) The Abscopal Effect Exists in Non-small Cell Lung Cancer: A Case Report and Review of the Literature. Cureus 11(2): e4118. DOI 10.7759/cureus.4118

anti-PD 1 therapy in a variety of patients with metastatic solid tumors. They reported the occurrence of an abscopal effect in patients with melanoma but the absence of the effect in patients with renal cell carcinoma or NSCLC.

Herein, the author reports the case of a patient with adenocarcinoma of the left lung, stage IV at presentation, who had an abscopal effect augmented by nivolumab and who is now alive and clinically disease-free 4.5 years since the time of diagnosis. In this case report, the author reviews the patients reported to date with NSCLC and an abscopal effect [9-13].

Case Presentation

A now 62-year-old woman presented to the Advocate Lutheran General Hospital (ALGH) on June 6, 2014 because of a three-week history of hemoptysis. She had a 40-pack year history of cigarette smoking. A computed tomographic (CT) scan of the chest, abdomen, and pelvis documented a 5 cm, necrotic, left lower lung mass with pathologic (3-4 cm) hilar and left mediastinal adenopathy. There was an 8 cm mass found in the left adrenal consistent with metastatic involvement. No other metastatic sites were identified. A CT guided fine needle aspiration of the adrenal mass document a poorly differentiated adenocarcinoma consistent with a primary lung adenocarcinoma based on histochemical staining (TTF-1 positive). The epidermal growth factor receptor (EGFR) and anaplastic lymphoma kinase (ALK) studies were negative. A staging magnetic resonance imaging (MRI) of the brain was normal. On her first visit, she had blood loss anemia (hemoglobin 6.9 gms/dL) because of on-going hemoptysis that she estimated to be a cupful daily. On July 1, 2014 she was hospitalized at ALGH, transfused, and started on chemotherapy with carboplatin and pemetrexed. She was discharged and seen weekly. The hemoptysis persisted, and she required one unit of packed red blood cells weekly to maintain a hemoglobin of greater than 7 gms/dL. On July 22, 2014, she received her second cycle of carboplatin and pemetrexed. She continued to have ongoing hemoptysis with weekly transfusion requirements. Following the second cycle of carboplatin and pemetrexed, a restaging chest and abdominal CT documented progressive disease as did the positron emission tomography (PET) scan (Figure 1).

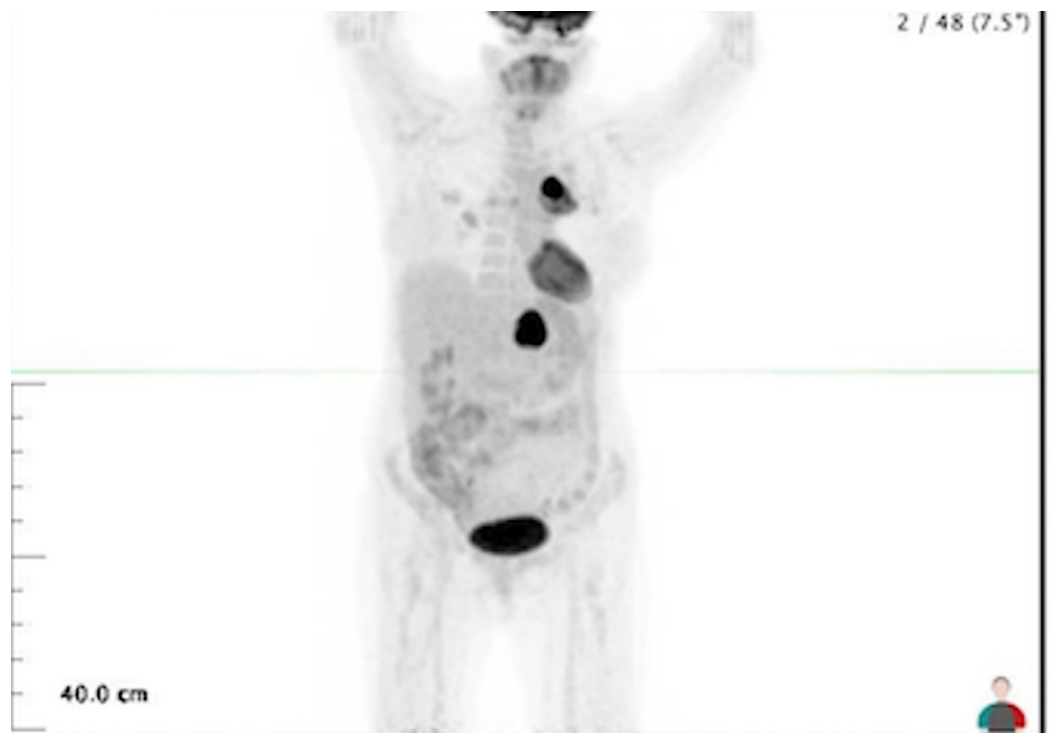


FIGURE 1: Positron emission tomography (PET) scan dated

08/07/2014 prior to radiation therapy

The positron emission tomography (PET) scan shows intense uptake in the left lung and the left adrenal mass. The standardized uptake value (SUV) in the lung was 15 and SUV in the adrenal mass was 22.

The adrenal mass was now 10 cm and the lung primary was now 7 cm. She was referred to radiation oncology in an attempt to better control the ongoing hemoptysis so that she didn't exsanguinate. She received 27 Gy to the left lower lobe lung mass in 9 fractions.

The hemoptysis started to abate and she was enrolled on a compassionate use nivolumab study, ALGH 1408, and was started on nivolumab 3 mg/kg every two weeks commencing on September 24, 2014; the patient continues on nivolumab now 480 mg monthly.

The PET scan performed on January 25, 2015, after 15 cycles of nivolumab is shown in Figure 2. The left adrenal mass reading was an SUV of 2.2 and the size decreased to 2.2 cm.

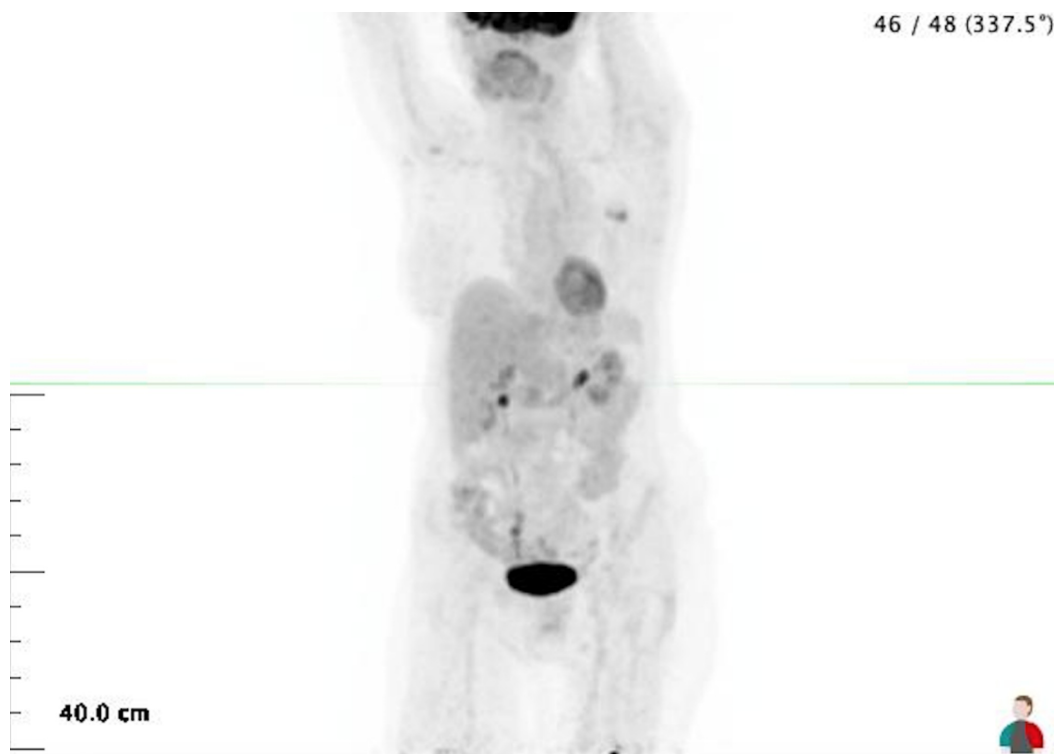


FIGURE 2: Positron emission tomography (PET) scan dated 01/25/2015 after 15 cycles of nivolumab

There is no longer any uptake in the left lung. The left adrenal mass is now 2.2 cm and the SUV is 2.2.

Discussion

There have been six case reports (including the current one) of an abscopal effect in patients with NSCLC [9-13] as shown in Table 1.

Reference No.	Age/Sex	Stage	Prior Therapy	Radiation Therapy	Abscopal Effect
[9]	64/M	IV	C&P V&G	30Gy/5 to liver + ipili	Regression at distant sites
[10]	63/M	IV	none	45Gy/15 to CNS and 30Gy/10 to L3	Regression of lung primary
[11]	78/F	IIIA	none	60Gy/30 to LUL SBRT to RLL	Developed adrenal & humeral mets that disappeared
[12]	47/M	IIIB	Chemotherapy Radiation+ Cetuximab Resection	SBRT to 2 of 3 RPN + nivo	3rd RPN disappeared
[13]	47/M	IIIA	Chemotherapy then resection	40Gy/20 to liver + nivo	Lung mets regressed
Present Case	62/F	IV	C&P	27Gy/9 to left lung +nivo	Adrenal met disappeared

TABLE 1: Case reports of an abscopal effect in NSCLC

NSCLC: non-small cell lung cancer; C&P: carboplatin and pemetrexate; V&G: vinorelbine and gemcitabine; SBRT: stereotactic body radiation therapy; RPN: retroperitoneal lymph nodes; nivo: nivolumab; ipili: ipilimumab; LUL: left upper lobe; RLL: right lower lobe.

In two of the six cases [10-11], radiation therapy alone to either the primary lung cancer or a metastatic lesion leads to regression and represent a bona fide abscopal effect. Of these two patients, one had a short-lived abscopal effect [10], the other patient reported [11] had a long-lived response. In the remaining four patients [9,12-13], including the current case, the abscopal effect was augmented by either ipilimumab [9] or nivolumab [12-13]. One could certainly argue that the effect seen in these patients was not a true abscopal effect but rather the consequence of the immunotherapy used. The activity of nivolumab as a second line therapy in patients with previously treated NSCLC is modest at best. There was 17.1% overall response rate and only one complete response (CR) among 74 patients with a non-squamous histology (CR rate 1.3%) [14]. Alternatively, the counter-argument is that the local radiation therapy caused an alteration of the immuno-phenotype of the lung cancer making it more immunogenic and the immunotherapy augmented the abscopal effect. The patient reported here is alive and clinically disease-free 4.5 years after the time of initial diagnosis.

Conclusions

In conclusion, there appears to be a bona fide abscopal effect in patients with NSCLC. The author is of the opinion that the PD-1 inhibitors augment this effect. Ultimately, the way to conclude as to whether local radiation therapy heightens the immunogenicity of NSCLC is to perform randomized studies comparing anti-PD1 therapy alone to anti-PD 1 coupled with initial local stereotactic radiation therapy to either a primary or metastatic target. Such a study will quantify whether there is an additive effect of local radiation therapy on the control of metastatic NSCLC and its impact on progression free and overall survival.

Additional Information

Disclosures

Human subjects: Consent was obtained by all participants in this study. **Conflicts of interest:** In compliance with the ICMJE uniform disclosure form, all authors declare the following: **Payment/services info:** All authors have declared that no financial support was received from any organization for the submitted work. **Financial relationships:** All authors have declared that they have no financial relationships at present or within the previous three years with any organizations that might have an interest in the submitted work. **Other relationships:** All authors have declared that there are no other relationships or activities that could appear to have influenced the submitted work.

References

1. Canman CE, Lim DS, Cimprich KA, et al.: Activation of ATM kinase by ionizing radiation and phosphorylation of p53. *Science*. 1998, 281:1677-79. [10.1126/science.281.5383.1667](https://doi.org/10.1126/science.281.5383.1667)
2. Hall EJ, Giaccia A: *Radiobiology for the Radiologist*. Lippincott Williams & Wilkins, Philadelphia; 2011.
3. Hallahan DE, Virudachalam S, Sherman ML, Huberman E, Weichselbaum RR: Tumor necrosis factor gene expression is mediated by protein kinase C following activation by ionizing radiation. *Cancer Res*. 1991, 51:4565-69.
4. Hara T, Namba H, Yang TT, et al.: Ionizing radiation activates c-Jun NH-2 terminal kinase (JNK/SAPK) via a PKC-dependent pathway in human thyroid cells. *Biochem Biophys Res Commun*. 1998, 244:41-4. [10.1006/bbrc.1998.8210](https://doi.org/10.1006/bbrc.1998.8210)
5. Li N, Karin M: Ionizing radiation and short wavelength UV activate NF-kappaB through two distinct mechanisms. *Proc Natl Acad Sci*. 1998, 95:13012-17. [10.1073/pnas.95.22.13012](https://doi.org/10.1073/pnas.95.22.13012)
6. Garnett CT, Palena C, Chakraborty M, Tsang KY, Schlom J, Hodge JW.: Sublethal irradiation of human tumor cells modulates phenotype resulting in enhanced killing by cytotoxic T lymphocytes. *Cancer Res*. 2004, 64:7985-94. [10.1158/0008-5472.CAN-04-1525](https://doi.org/10.1158/0008-5472.CAN-04-1525)
7. Deng L, Liang H, Xu M, et al.: STING-dependent cytosolic DNA sensing promotes radiation-induced type 1 interferon dependent immunity in immunogenic tumors. *Immunity*. 2014, 41:843-52. <https://www.sciencedirect.com/science/article/pii/S1074761314003951>
8. Riberio Gomes J, Schmerling RA, Haddad CK: Analysis of the abscopal effect with anti-PD 1 therapy in patients with metastatic solid tumors. *J Immunother*. 2016, 39:367-72. [10.1097/CJI.0000000000000141](https://doi.org/10.1097/CJI.0000000000000141)
9. Golden EB, Demaria S, Schiff P B, Chaxchoua A, Formenti SC: An abscopal response to radiation and ipillimumab in patient with metastatic non-small lung cancer. *Cancer Immunol Res*. 2013, 1:365-72. [10.1158/2326-6066.CIR-13-0115](https://doi.org/10.1158/2326-6066.CIR-13-0115)
10. Katayama K, Tamiya A, Koba T, Fukuda S, Atagi, S: An abscopal response to radiation therapy in a patient with metastatic non small lung cancer: a case report. *J Cancer Sci Ther*. 2017, 9:363-365. [10.4172/1948-5956.1000443](https://doi.org/10.4172/1948-5956.1000443)
11. Siva S, Callahan J, MacManus MP, Martin O, Hicks RJ, Ball DL: Abscopal effect after conventional and stereotactic lung irradiation of non-small-cell lung cancer. *J Thorac Oncol*. 2013, 8:e71-e72. [10.1097/JTO.0b013e318292c55a](https://doi.org/10.1097/JTO.0b013e318292c55a)
12. Britschgi C, Riesterer O, Burger IA, Guckenberger M, Curioni-Fontecedro A: Report of an abscopal effect induced by stereotactic body radiotherapy and nivolumab in a patient with metastatic non-small cell lung cancer. *Radiat Oncol*. 2018, 13:102. [10.1186/s13014-018-1049-3](https://doi.org/10.1186/s13014-018-1049-3)
13. Komatsu T, Nakamura K, Kawase A: Abscopal effect of nivolumab in a patient with primary lung cancer. *J Thorac Oncol*. 2017, 12:e143-e144. [10.1016/j.jtho.2017.05.004](https://doi.org/10.1016/j.jtho.2017.05.004)
14. Gettinger SN, Horn L, Gandhi L, et al.: Overall survival and long-term safety of nivolumab (anti-programmed death-1 antibody, BMS-936558, ONO-4538) in patients with previously treated advanced non-small cell lung cancer. *J Clin Oncol*. 2015, 33:2004-12. [10.1200/JCO.2014.58.3708](https://doi.org/10.1200/JCO.2014.58.3708)