

Synchronous Bilateral Breast Cancer: A Case Report Piloting and Evaluating the Implementation of the AI-Powered Large Language Model (LLM) ChatGPT

Review began 03/08/2023
Review ended 03/29/2023
Published 04/14/2023

© Copyright 2023

Naik et al. This is an open access article distributed under the terms of the Creative Commons Attribution License CC-BY 4.0., which permits unrestricted use, distribution, and reproduction in any medium, provided the original author and source are credited.

Himani R. Naik¹, Andrew D. Prather², Grzegorz T. Gurda^{3,4}

1. Gundersen Medical Foundation, Gundersen Lutheran Medical Center, La Crosse, USA 2. Radiology, Gundersen Lutheran Medical Center, La Crosse, USA 3. Biology, University of Wisconsin-La Crosse, La Crosse, USA 4. Pathology, Gundersen Lutheran Medical Center, La Crosse, USA

Corresponding author: Grzegorz T. Gurda, gtgurda@gundersenhealth.org

Abstract

Primary breast carcinoma is the most common cancer type in women, and although bilateral synchronous breast cancers (s-BBC) remain quite rare, the reported incidence may increase with the adoption of more sensitive imaging modalities. Here, we present a case of histomorphological and clinically distinct s-BBC, together with a discussion of clinical management decisions, prognosis, and treatment standards and how these relate to outcomes vis-à-vis more established standards in unifocal breast carcinoma. The case report also constitutes a pilot and formal evaluation of a large language model (LLM) of ChatGPT as a tool to aid in generating a single patient case report.

Categories: Pathology, Radiology, Oncology

Keywords: chatgpt aided case report, chatgpt, breast cancer risk, multifocal, bilateral, ductal carcinoma, breast cancer

Introduction

The text below was generated through a combination of ChatGPT queries and manual (human) writing and editing. The full constituent components of the text, including analysis of the writing, are presented in the appendices.

Synchronous bilateral breast cancer (s-BBC) is a rare presentation of breast cancer, accounting for 1%-3% of all breast cancer cases. s-BBC is typically defined as the presence of invasive or in situ breast cancer in both breasts diagnosed within six months of each other [1,2]. The diagnosis of s-BBC can be challenging, as the tumors can present at different stages and have different clinical presentations and histopathological characteristics. The prognosis and treatment options for s-BBC depend on several factors, including the stage, histological grade, and other prognostic factors of each individual tumor. Here, we present a case report of a patient with s-BBC, one intermediate-risk ductal carcinoma in the right breast with positive right axillary lymph nodes, and one low-risk ductal carcinoma with lobular features in the left breast with negative left axillary lymph nodes. We discuss the clinical management, prognosis, and treatment implications of s-BBC.

Case Presentation

A 58-year-old woman presented with a history of a painless lump in her right breast. Mammography and ultrasound showed a 4.5-cm suspicious mass in the mid-posterior upper outer quadrant of the right breast (Figure 1A) and initially no significant suspicious lesions in the left breast (Figure 1B). Following a malignant diagnosis of the right breast mass upon ultrasound (US)-guided needle core biopsy, a contrast-enhanced diagnostic magnetic resonance imaging (MRI) of both breasts was performed and identified an additional 1.5 cm of enhancing lesion in the upper inner quadrant of the left breast (Figure 1C).

How to cite this article

Naik H R, Prather A D, Gurda G T (April 14, 2023) Synchronous Bilateral Breast Cancer: A Case Report Piloting and Evaluating the Implementation of the AI-Powered Large Language Model (LLM) ChatGPT. Cureus 15(4): e37587. DOI 10.7759/cureus.37587

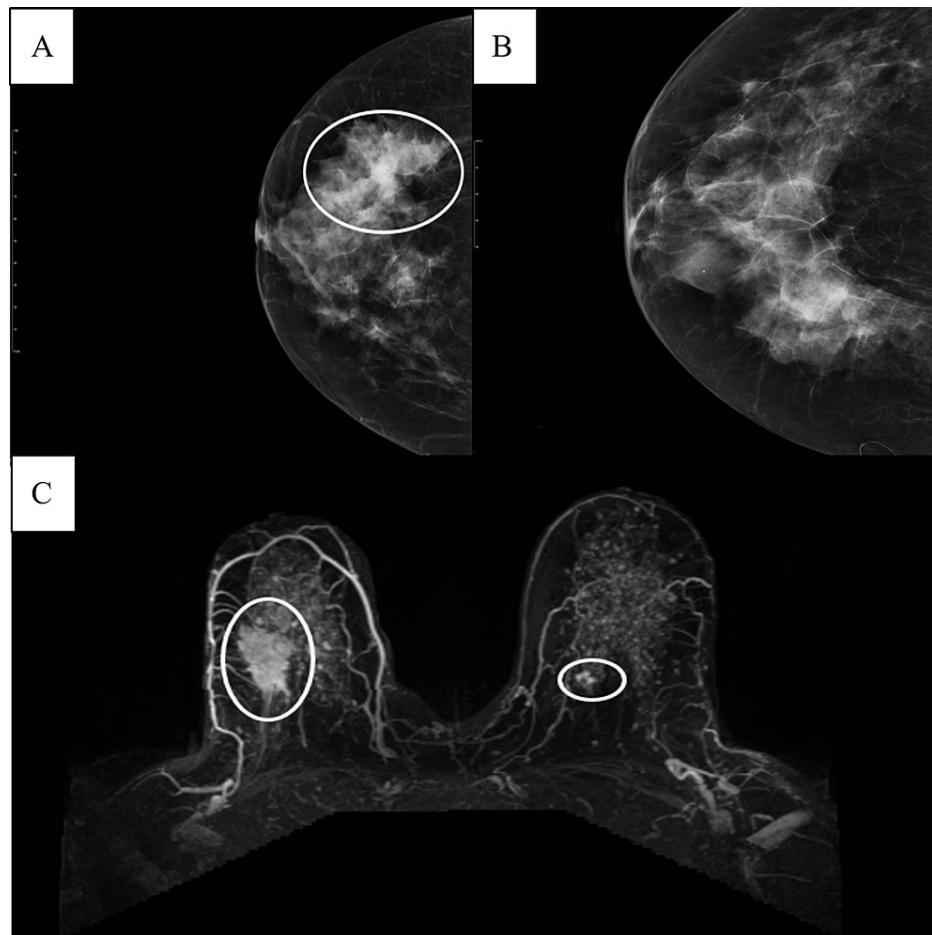


FIGURE 1: Pre-operative imaging

A. Mammography, right breast, cranio-caudal (CC) view, white oval to indicate lesion area B. Mammography, right breast, cranio-caudal (CC) view, no definite findings C. Magnetic resonance imaging (MRI), post-contrast T1, white ovals to indicate lesions bilaterally.

An MRI-guided needle biopsy was performed, establishing the diagnosis of invasive ductal carcinoma with lobular carcinoma of the left breast. The tumors were both estrogen receptor (ER) strongly positive, progesterone receptor (PR) weakly to moderately positive, and HER2/neu-negative (Figure 2); an E-cadherin immunohistochemical stain showed strong, preserved membranous staining, supporting the histomorphologic impression of a predominantly ductal phenotype but also focal lobular neoplasia in situ (ALH) of the left breast.

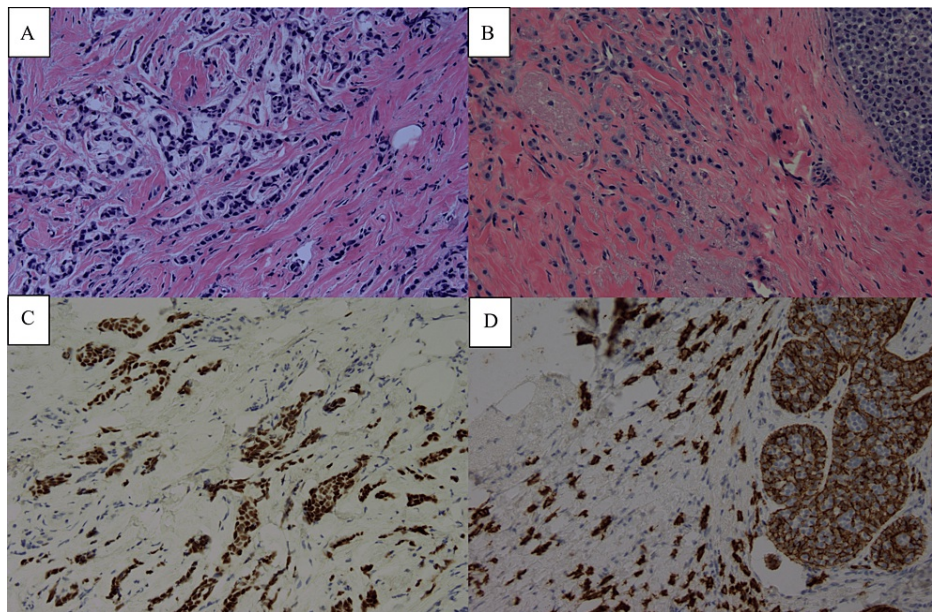


FIGURE 2: Pre-operative pathology (needle core biopsies, right and left breast)

A. H&E, 20X, histomorphology of right-sided ductal carcinoma B. Estrogen receptor (ER) strong positivity, progesterone receptor (PR) weak positivity (not shown) C. H&E, 20X, histomorphology of right-sided ductal carcinoma with lobular features and adjacent atypical lobular hyperplasia (ALH) D. Partial loss of E-cadherin membranous staining within ALH, preserved within invasive carcinoma; estrogen receptor (ER) strong positivity; progesterone receptor (PR) weak-moderate positivity (not shown)

The patient had no family history of breast or ovarian cancer, and her risk assessment (the Gail model) indicated a low risk. The patient also met with a genetic counselor and underwent germline testing for high-prevalence breast cancer risk genes (Invitae, San Francisco, CA), but no pathologic variants (category 1 or 2) were found. The patient was diagnosed with s-BBC and underwent a multidisciplinary evaluation at our institutional breast cancer tumor board to determine the best treatment plan.

The patient underwent a bilateral skin-sparing mastectomy with reconstruction, bilateral sentinel lymph node biopsy, and axillary lymph node dissection. The final pathology revealed a 4.5 cm intermediate-grade (Nottingham combined grade 2 of 3) ductal carcinoma with 7 of 21 positive right axillary lymph nodes in the right breast and a 1.4 cm low-grade (Nottingham combined grade 1 of 3) ductal carcinoma with lobular features in the left breast with negative left axillary lymph nodes. The patient's pathologic staging (AJCC 8th ed.) was, therefore, pT2 N2a on the right side and pT1c pN0(sn) on the left side.

The patient received adjuvant radiation therapy to the right breast and axilla, as well as systemic adjuvant AC-T chemotherapy, i.e., doxorubicin hydrochloride (Adriamycin) and cyclophosphamide, followed by paclitaxel (Taxol) and subsequent adjuvant endocrine therapy with a non-steroidal aromatase inhibitor (AI), anastrozole. The right breast was closely monitored with regular radiographic screening and clinical examinations of the reconstructed breast tissue and implant, and there has been no evidence of disease recurrence during the five-year follow-up period.

Discussion

The management of s-BBC depends on several factors, including the stage of the disease, the histopathological characteristics of the tumors, the patient's health status, including age and comorbidities, as well as the patient's own health management preferences. Treatment options include breast-conserving surgery, mastectomy, radiation therapy, and systemic therapy with chemotherapy, endocrine therapy, or targeted therapy.

Breast-conserving surgery (BCS) is a reasonable option for patients with s-BBC, provided that the tumors can be completely excised with negative margins. The prognosis of s-BBC has long been considered to be generally worse than that of unilateral breast cancer, with worse overall survival than either unilateral or metachronous breast cancer likely due to an earlier and perhaps higher risk of distant metastasis [1]. This has been re-appraised in more recent studies with larger sample sizes, stringent data collection at the outset, longer follow-up, and multivariate adjustment for tumor biology to show that the inferior prognosis of s-BBC may not be due to the higher aggressiveness of cancers in this setting per se, but the combined

detrimental effect due to simultaneous malignancies [2,3]. The presence of positive lymph nodes is associated with a worse prognosis, and patients with positive lymph nodes should receive adjuvant chemotherapy in addition to surgery and radiation therapy [4]. In this case, the patient received adjuvant chemotherapy based on the intermediate risk of right breast cancer.

Mastectomy may be considered or recommended in patients with large or multifocal tumors, an extensive intraductal component, or a strong family history of breast cancer [4]. Radiation therapy is recommended for s-BBC patients who undergo breast-sparing surgery such as lumpectomy to reduce the risk of local recurrence. Bilateral breast irradiation can be challenging with different fields and dose requirements for variably aggressive tumors at two sites, but a hypofractionated schedule is technically feasible, can minimize acute toxicity/side effects, and shows no increase in the risk of significant late effects (for instance, secondary malignancies such as angiosarcomas), though the study conclusions should be viewed with caution due to the relatively short follow-up [5].

Systemic therapy with chemotherapy, endocrine therapy, or targeted therapy may be considered based on the histological characteristics of the tumors and the patient's overall health. In our case, the patient received adjuvant endocrine therapy with an AI (anastrozole) given the hormone receptor-positive status of both tumors, particularly the larger, more biologically aggressive right-sided tumor. In a retrospective study of 1,214 patients with s-BBC, there was a similar range of distribution for tumor size, pathological grade, ER positivity, and axillary lymph node involvement, and when corrected with multivariate competing risk models using both tumor sites as opposed to unilateral breast cancer, there was no difference in overall survival (Risk Ratio (RR) = 1.01, CI: 1.08-1.57, $p=0.93$) [2]. Similarly, in a large multi-site clinical trial based on the utilization of a 70-gene signature in low-risk breast cancer patients, 238 s-BBC patients with the multifocal disease showed a slightly elevated genomic risk profile versus unifocal breast cancer patients (high risk of 22.7% vs. 17.3%, odds ratio [OD] = 1.45, $p=0.038$), but no association in disease-free survival (DFS 96.9% vs. 97.1%, hazard ratio [HR] = 1.55, $p=0.172$) [3], albeit with some limitations as to the general applicability of the study due to the characteristics of the patient accrual. Nearly all studies seem to agree with the generally accepted paradigm that invasive lobular carcinoma and lobular neoplasia in situ (ALH/LCIS) are surrogate risk markers for the development of future breast cancer (in both breasts) and that lobular carcinoma in situ (LCIS) is a non-obligate precursor of breast cancer. In the studies discussed thus far, the lobular phenotype was enriched in s-BBC, representing 11% in the unilateral setting versus 13.7%-15.6% in s-BBC [2] or 6.6% in metachronous BBC versus 8.6% in s-BBC [1]. For the patient presented in this case report, there was documented lobular neoplasia in situ (ALH) in the smaller tumor, as well as lobular features histomorphologically, albeit this characterization is difficult to stringently and uniformly apply. In terms of late recurrence and metastasis, there also does not appear to be a significant difference in the anatomic site and distribution of late/distal metastasis versus metachronous breast cancer (in descending order, bone, lymph nodes, lungs, liver, and brain, among others) [1]. Lastly, in the setting of s-BBC, consideration of metastasis to the contralateral breast rather than two synchronous primary cancers should be considered, especially if the tumors appear histomorphological similar, have similar receptor status, are of high grade/stage, have axillary metastasis on one side, but lack carcinoma in situ (DCIS/LCIS) in the contralateral breast. More rigorous analytical approaches, such as next-generation sequencing, have shown that about 5% of s-BBC may indeed constitute metastatic disease involving the contralateral breast rather than multifocal synchronous cancers [6]. Although these advanced molecular diagnostics approaches are informative in terms of further prognosis and management, they can be difficult to execute in a typical clinical setting and, due to some limitations, may still give equivocal results.

As stated in the case presentation, the patient underwent genetic counseling and underwent broad-panel germline testing with negative results. Per current national comprehensive cancer network (NCCN) guidelines (version 3.2023), an indication for testing for high penetrance cancer susceptibility genes (BRCA1/2, CDH1, PALB2, PTEN, and TP53) is indicated in women with multiple primary breast cancers, regardless of age, and this includes both s-BBC and metachronous breast cancer [4].

There is limited evidence on the optimal follow-up strategy for patients with s-BBC. The general approach is to follow the patient clinically after surgery, with imaging at least once or twice within the next two years [7]. Magnetic resonance imaging (MRI) may be considered for high-risk patients, such as those with a strong family history of breast or ovarian cancer or with dense breast tissue [8]. Adoption of more advanced and sensitive imaging techniques such as MRI may lead to increased detection of what would otherwise be clinically and grossly (by surgical pathology) occult carcinomas and thus lead to an increased reported incidence of s-BBC in the future.

Conclusions

s-BBC is a rare presentation of breast cancer that requires a careful diagnostic and clinical management approach. Treatment options include breast-conserving surgery, mastectomy, radiation therapy, and systemic therapy, with decisions currently most commonly driven by the more advanced and biologically aggressive site of the tumor. The prognosis of s-BBC is generally thought to be either somewhat worse or quite similar to that of unilateral breast cancer. Close surveillance with regular mammography and clinical follow-up is recommended for patients who undergo breast-conserving surgery to detect any new or recurrent breast cancer. Given the relative rarity of this clinical setting, further research is needed to

determine the optimal management, risk assessment (i.e., appropriate application of prognostic molecular testing such as mammaprint or Oncotype), and risk-reduction strategies for patients with s-BBC.

Appendices

Three similar queries were attempted with ChatGPT, and analyzed by GPTzero (<https://gptzero.me/>):

Ver 1: Perplexity 39; Burstiness 15.7 (entirely AI)

Ver 2: Perplexity 44; Burstiness 22 (partly AI)

Ver 3: Perplexity 35; Burstiness 16.7 (entirely AI)

ChatGPT queries

Query #1

GT Create a medical case report about bilateral synchronous breast cancer: case report and review of clinical management, prognosis and treatment implications. Ductal carcinoma, woman in late 50s, low risk. 1000-1200 words, 10 references from pubmed.gov

Introduction

Breast cancer is the most common cancer in women worldwide. Bilateral synchronous breast cancer (BSBC) refers to the simultaneous occurrence of cancer in both breasts, with a prevalence of 1-3% in breast cancer patients. BSBC presents unique challenges in terms of diagnosis, treatment, and prognosis. Here, we present a case report of a woman in her late 50s with BSBC and review the clinical management, prognosis, and treatment implications.

Case report

A 58-year-old woman presented with a palpable lump in her right breast. Mammography

Query #2

GT Create a medical case report about bilateral synchronous breast cancer: case report and review of clinical management, prognosis and treatment implications. Intermediate risk ductal carcinoma right breast, low risk ductal carcinoma with lobular features left breast, woman in late 50s. 1000-1200 words, incorporating mammography figure 1 and histopathology figure 2. 10 references from pubmed.gov

Introduction:

Breast cancer is one of the most common types of cancer in women worldwide. Bilateral synchronous breast cancer (BSBC) is defined as the presence of two separate primary tumors in both breasts detected at the same time or within a short interval. It is estimated that 1-3% of breast cancer patients have BSBC. The diagnosis of BSBC poses significant challenges in terms of clinical management, prognosis, and treatment implications. In this report, we present a case of a woman in her late 50s with BSBC, one with intermediate risk ductal carcinoma and the other with low risk ductal carcinoma with lobular features, and review the clinical management, prognosis, and treatment implications based on the current evidence.

Case Report:

A 57-year-old woman presented with a palpable lump in her right breast. Mammography

Query #3

GT Create a medical case report about bilateral synchronous breast cancer: review of clinical management, prognosis and treatment implications. Intermediate risk ductal carcinoma right breast with positive right axillary lymph nodes, low risk ductal carcinoma with lobular features left breast with negative left axillary lymph nodes, woman in late 50s. 1000-1200 words, incorporating mammography of both right and left breasts as figure 1 and histopathology as figure 2. Ten 10 references from pubmed.gov including Begg CB et al. "Contralateral breast cancers: Independent cancers or metastases?"

Introduction:

Bilateral synchronous breast cancer (BSBC) is the occurrence of two separate primary tumors in both breasts that are detected either simultaneously or within a short time frame. The incidence of BSBC is relatively low, estimated to be between 1-3% of all breast cancer cases. BSBC presents a unique challenge in terms of diagnosis, clinical management, and treatment. In this report, we present a case of a woman in her late 50s with BSBC, one with intermediate risk ductal carcinoma with positive right axillary lymph nodes and the other with low risk ductal carcinoma with lobular features and negative left axillary lymph nodes. We also review the clinical management, prognosis, and treatment implications based on current evidence.

Case Report:

A 58-year-old woman presented with a palpable lump in her right breast. Mammography

ChatGPT Feb 13 Version. Free Research Preview. Our goal is to make AI systems more natural and safe to interact with. Your feedback will help us improve.

FIGURE 3: ChatGPT queries

Three ChatGPT queries, stepwise more complex, with initial text generated. The final component of AI-generated text contained fragments from all three queries, but predominantly query #2.

One additional query (same as ver3) was attempted via BLOOM (a different LLM algorithm, trained with domain-specific text)

Perplexity 50.7; Burstiness 33.8 (partly AI)

For comparison, my most recent prior published case report is: Perplexity 120.3; Burstiness 88.8 (entirely human)

Lastly, the ChatGPT-assisted final version of the manuscript (~60% human text, discussion, and conclusion

sections): Perplexity 62.3 Burstiness 45.8 (likely entirely human)

Methods: Default setting for GPTzero API (beta); at a threshold of 0.65, 85% of AI documents are classified as AI, and 99% of human documents are classified as human.

Author impressions (Dr. Gurda)

Unfortunately, there is no such thing as a "free lunch" and not everything is as easy as it seems. The discussion sections generated by my queries to ChatGPT seemed to make sense, and superficially, the text generated appeared sensible, but the numbers and the citations produced were entirely fictitious. The authors and the journals existed; the article titles and numbers made general sense but were apparently pulled out of "thin air", or rather generated by a confluence of text in the training set. As an example, ChatGPT text reads:

"In a retrospective study of 166 patients with s-BBC who underwent BCS, the 10-year overall survival rate was 77%, and the disease-free survival rate was 67%.

The study found that the presence of lobular carcinoma in situ, an extensive intraductal component, and lymph node involvement were significant predictors of worse outcomes (1).

Sun J, Huo L, Xie C, et al. The prognosis of synchronous bilateral breast cancer: a single-center experience. PLoS One. 2015;10(6):e0128343."

It sounds credible, but this study does not exist. The authors exist, the journal exists, but the article and, most importantly, the data cited do not. Overall, for the purposes of generating a discussion section, ChatGPT at this point in its development (early 2023) appears to mostly have the characteristics of a 'confidence man' -- superficially accurate and strong, but the substance rings hollow.

Nonetheless, as stated elsewhere, I found ChatGPT and other LLMs to be useful in generating a skeletonized outline, organizing my thoughts about the subject in a logical manner (even if I had to gather the evidence for the arguments being made in the discussion 'manually' later), and in general as a motivation to get started and/or overcome writer's block.

Lastly, the full text of the article. What was generated by ChatGPT (verbatim) is highlighted, and manual human entry and edits are in standard text (Figures 4, 5):

Introduction:

Synchronous bilateral breast cancer (s-BBC) is a rare presentation of breast cancer, accounting for 1-3% of all breast cancer cases. s-BBC is typically defined as the presence of invasive or in situ breast cancer in both breasts diagnosed within 6 months of each other [1,2]. The diagnosis of s-BBC can be challenging, as the tumors can present at different stages and have different clinical presentations and histopathological characteristics. The prognosis and treatment options of s-BBC depend on several factors, including the stage, histological grade, and other prognostic factors of each individual tumor. Here, we present a case report of a patient with s-BBC, one intermediate-risk ductal carcinoma in the right breast with positive right axillary lymph nodes and one low-risk ductal carcinoma with lobular features in the left breast with negative left axillary lymph nodes. We discuss the clinical management, prognosis, and treatment implications of s-BBC.

Case Presentation:

A 58-year-old woman presented with a history of a painless lump in her right breast. Mammography and ultrasound showed a 4.5cm suspicious mass in mid-posterior upper outer quadrant of the right breast (Figure 1A) and initially no significant suspicious lesions in the left breast (Figure 1B). Following a malignant diagnosis of the right breast mass upon ultrasound (US)-guided needle core biopsy, a contrast-enhanced diagnostic magnetic resonance imaging (MRI) of both breasts was performed and identified an additional 1.5cm enhancing lesion of the upper inner quadrant of the left breast (Figure 1C). The patient had no family history of breast or ovarian cancer, and her risk assessment (the Gail model) indicated a low risk. The patient also met with a genetic counselor and underwent germline testing for high prevalence breast cancer risk genes (Invitae, San Francisco, CA), but no pathologic variants (category 1 or 2) were found. The patient was diagnosed with s-BBC and underwent a multidisciplinary evaluation at our institutional breast cancer tumor board to determine the best treatment plan. The patient underwent a bilateral skin-sparing mastectomy with reconstruction, bilateral sentinel lymph node biopsy, and axillary lymph node dissection.

The final pathology revealed a 4.5 cm intermediate-grade (Nottingham combined grade 2 of 3) ductal carcinoma with 7 of 21 positive right axillary lymph nodes in the right breast and a 1.4 cm low-grade (Nottingham combined grade 1 of 3) ductal carcinoma with lobular features in the left breast with negative left axillary lymph nodes. The patient's pathologic staging (AJCC 8th ed.) was, therefore, pT2 N2a on the right side and pT1c pN0(sn) on the left side. The patient received adjuvant radiation therapy to the right breast and axilla, as well as systemic adjuvant AC-T chemotherapy, i.e. doxorubicin hydrochloride (Adriamycin) and cyclophosphamide, followed by paclitaxel (Taxol) and subsequent adjuvant endocrine therapy with a non-steroidal aromatase inhibitor (AI) anastrozole. The right breast was closely monitored with regular radiographic screening and clinical examinations of the reconstructed breast tissue and implant, and there has been no evidence of disease recurrence during the five-year follow-up period.

Discussion:

The management of s-BBC depends on several factors, including the stage of the disease, the histopathological characteristics of the tumors, the patient's health status including age and comorbidities as well as the patient's own health management preferences. Treatment options include breast-conserving surgery, mastectomy, radiation therapy, and systemic therapy with chemotherapy, endocrine therapy, or targeted therapy. Breast-conserving surgery (BCS) is a reasonable option for patients with s-BBC, provided that the tumors can be completely excised with negative margins. The prognosis of s-BBC has long been considered to be generally worse than that of unilateral breast cancer, with worse overall survival than either unilateral or metachronous breast cancer likely due to earlier and perhaps higher risk of distant metastasis [1]. This has been re-appraised in more recent studies, with larger sample sizes, stringent data collection at outset, longer followup and multivariate adjustment for tumor biology to show that inferior prognosis of s-BBC may not be due to higher aggressiveness of cancers in this setting per se, but the combined detrimental effect due to simultaneous malignancies [2, 3]. The presence of positive lymph nodes is associated with a worse prognosis, and patients with positive lymph nodes should receive adjuvant chemotherapy in addition to surgery and radiation therapy [4]. In this case, the patient received adjuvant chemotherapy based on the intermediate risk of the right breast cancer.

Mastectomy may be considered in patients with large or multifocal tumors, extensive intraductal component, or a strong family history of breast cancer [4]. Radiation therapy is recommended for patients who undergo s-BBC to reduce the risk of local recurrence. Bilateral breast irradiation can be challenging with different fields and dose requirements of variably aggressive tumors at two sites, but hypofractionated schedule is technically feasible, can minimize acute toxicity/side effects, and shows no increase in the risk of significant late effects (for instance secondary malignancies

FIGURE 4: Script as generated by ChatGPT (Part A)

such as angiosarcomas), though the study conclusions should be viewed with caution due to the relatively short follow-up [5].

Systemic therapy with chemotherapy, endocrine therapy, or targeted therapy may be considered based on the histological characteristics of the tumors and the patient's overall health. In our case, the patient received adjuvant endocrine therapy with an AI (anastrozole) given the hormone receptor-positive status of both tumors, but particularly the larger more biologically aggressive right-sided tumor. In a retrospective study of 1,214 patients with s-BBC, there was a similar range of distribution for tumor size, pathological grade, ER positivity, and axillary lymph node involvement, and when corrected with multivariate competing risk models using both tumor sites as opposed to unilateral breast cancer, there was no difference in overall survival (Risk Ratio (RR) = 1.01, CI: 1.08-1.57, p=0.93) [2]. Similarly, in a large multi-site clinical trial based on the utilization of a 70-gene signature in low-risk breast cancer patients, 238 s-BBC patients with the multifocal disease showed a slightly elevated genomic risk profile versus unifocal breast cancer patients (high risk of 22.7% vs. 17.3%, odds ratio [OD] = 1.45, p=0.038), but no association in disease-free survival (DFS 96.9% vs. 97.1%, hazard ratio [HR] = 1.55, p=0.172) [3], albeit with some limitations as to the general applicability of the study due to the characteristics of the patient accrual. Nearly all studies seem to agree with the generally accepted paradigm that invasive lobular carcinoma and lobular neoplasia in situ (ALH/LCIS) are surrogate risk markers for the development of future breast cancer (in both breasts) and that lobular carcinoma in situ (LCIS) is a non-obligate precursor of breast cancer. In the studies discussed thus far, the lobular phenotype was enriched in s-BBC, representing 11% in the unilateral setting versus 13.7%-15.6% in s-BBC [2] or 6.6% in metachronous BBC versus 8.6% in s-BBC [1]. For the patient presented in this case report, there was documented lobular neoplasia in situ (ALH) in the smaller tumor, as well as lobular features histomorphologically, albeit this characterization is difficult to stringently and uniformly apply. In terms of late recurrence and metastasis, there also does not appear to be a significant difference in the anatomic site and distribution of late/distal metastasis versus metachronous breast cancer (in descending order, bone, lymph nodes, lungs, liver, and brain, among others) [1]. Lastly, in the setting of s-BBC, consideration of metastasis to the contralateral breast rather than two synchronous primary cancers should be considered, especially if the tumors appear histomorphologically similar, have similar receptor status, are of high grade/stage, have axillary metastasis on one side, but lack carcinoma in situ (DCIS/LCIS) in the contralateral breast. More rigorous analytical approaches, such as next-generation sequencing, have shown that about 5% of s-BBC may indeed constitute metastatic disease involving the contralateral breast rather than multifocal synchronous cancers [6]. Although these advanced molecular diagnostics approaches are informative in terms of further prognosis and management, they can be difficult to execute in a typical clinical setting and, due to some limitations, may still give equivocal results.

As stated in the case presentation, the patient underwent genetic counseling and underwent broad-panel germline testing with negative results. Per current national comprehensive cancer network (NCCN) guidelines (version 3.2023), an indication for testing for high penetrance cancer susceptibility genes (BRCA1/2, CDH1, PALB2, PTEN, and TP53) is indicated in women with multiple primary breast cancers, regardless of age, and this includes both s-BBC and metachronous breast cancer [4].

There is limited evidence on the optimal follow-up strategy for patients with s-BBC. The general approach is to follow the patient clinically after surgery, with imaging at least once or twice within the next two years [7]. Magnetic resonance imaging (MRI) may be considered for high-risk patients, such as those with a strong family history of breast or ovarian cancer or with dense breast tissue [8]. Adoption of more advanced and sensitive imaging techniques such as MRI may lead to increased detection of what would otherwise be clinically and grossly (by surgical pathology) occult carcinomas and thus lead to an increased reported incidence of s-BBC in the future.

Conclusions:

s-BBC is a rare presentation of breast cancer that requires careful diagnostic and clinical management approach. Treatment options include breast-conserving surgery, mastectomy, radiation therapy, and systemic therapy, with decisions currently most commonly driven by the more advanced and biologically aggressive site of tumor. The prognosis of s-BBC is generally thought to be either somewhat worse or quite similar to unilateral breast cancer. Close surveillance with regular mammography and clinical follow-up is recommended for patients who undergo breast-conserving surgery to detect any new or recurrent breast cancer. Given relative rarity of this clinical setting, further research is needed to determine the optimal management, risk assessment (i.e. appropriate application of prognostic molecular testing such as mammprint or Oncotype) and risk-reduction strategies for patients with s-BBC.

FIGURE 5: Script as Generated by ChatGPT (Part B)

Additional Information

Disclosures

Human subjects: Consent was obtained or waived by all participants in this study. **Conflicts of interest:** In compliance with the ICMJE uniform disclosure form, all authors declare the following: **Payment/services info:** All authors have declared that no financial support was received from any organization for the submitted work. **Financial relationships:** All authors have declared that they have no financial relationships at present or within the previous three years with any organizations that might have an interest in the submitted work. **Other relationships:** All authors have declared that there are no other relationships or activities that could appear to have influenced the submitted work.

Acknowledgements

The manuscript includes input from the AI-powered large language model (LLM) ChatGPT (OpenAI, San Francisco, CA), although a significant (<50%) component of the text is manually (human) generated. Text generated by ChatGPT versus human input, as well as text analysis via GPTzero (OpenAI, San Francisco, CA) of the three queries to ChatGPT and one query via domain-trained LLM (Bloom), as well as author impressions of the writing process, are available in the appendix.

References

1. Sas-Korczyńska B, Kamzol W, Kołodziej-Rzepa M, Mituś JW, Wysocki WM: The characteristics of bilateral breast cancer patients. *Now Jr Onc*. 2018, 68:221-226.
2. Mejdahl MK, Wohlfahrt J, Holm M, et al.: Breast cancer mortality in synchronous bilateral breast cancer patients. *Br J Cancer*. 2019, 120:761-767.
3. Aalders KC, Kuijer A, Straver ME, et al.: Characterisation of multifocal breast cancer using the 70-gene signature in clinical low-risk patients enrolled in the EORTC 10041/BIG 03-04 MINDACT trial. *Eur J Cancer*. 2017, 79:98-105. [10.1016/j.ejca.2017.03.034](https://doi.org/10.1016/j.ejca.2017.03.034)
4. Gradishar WJ, Anderson BO, Balassanian R, et al.: Breast cancer, version 4. 2017, NCCN clinical practice guidelines in oncology. *J Natl Compr Canc Netw*. 2018, 16:310-20. [10.6004/jnccn.2018.0012](https://doi.org/10.6004/jnccn.2018.0012)
5. Gadea J, Ortiz I, Roncero R, et al.: Synchronous bilateral breast cancer treated with a 3-week hypofractionated radiotherapy schedule: clinical and dosimetric outcomes. *Clin Transl Oncol*. 2021, 23:1915-22. [10.1007/s12094-021-02600-1](https://doi.org/10.1007/s12094-021-02600-1)
6. Begg CB, Ostrovnaya I, Geyer FC, et al.: Contralateral breast cancers: Independent cancers or metastases?. *Int J Cancer*. 2018, 142:347-56. [10.1002/ijc.31051](https://doi.org/10.1002/ijc.31051)
7. Schootman M, Jeffe DB, Lian M, Aft R, Gillanders WE: Surveillance mammography and the risk of death among elderly breast cancer patients. *Breast Cancer Res Treat*. 2008, 111:489-96. [10.1007/s10549-007-9795-1](https://doi.org/10.1007/s10549-007-9795-1)
8. Saslow D, Boetes C, Burke W, et al.: American Cancer Society guidelines for breast screening with MRI as an adjunct to mammography. *CA Cancer J Clin*. 2007, 57:75-89. [10.3322/canjclin.57.2.75](https://doi.org/10.3322/canjclin.57.2.75)