

Acral Prurigo Nodularis: A Case Report

Abdulaziz Albinhamad¹, Mohammad Almazied¹, Ru'aa Alharithy², Ahmed Alhumidi³

Review began 09/03/2022

Review ended 09/15/2022

Published 09/21/2022

© Copyright 2022

Albinhamad et al. This is an open access article distributed under the terms of the Creative Commons Attribution License CC-BY 4.0., which permits unrestricted use, distribution, and reproduction in any medium, provided the original author and source are credited.

1. College of Medicine, Imam Mohammad Ibn Saud Islamic University, Riyadh, SAU 2. Dermatology, Security Forces Hospital, Princess Nourah Bint Abdulrahman University, Riyadh, SAU 3. Pathology, College of Medicine, King Saud University, Riyadh, SAU

Corresponding author: Abdulaziz Albinhamad, albinhamadabdulaziz@gmail.com

Abstract

Prurigo nodularis (PN) is a chronic skin disease that manifests with severe itchy, firm, hyperkeratotic nodules distributed on the trunk and the extremities symmetrically. Here, we report a unique presentation of PN. A 26-year-old male presented with multiple itchy nodules over the hands and feet sparing the trunk, which were confirmed histologically as PN. This is the first reported case of PN with exclusive acral distribution.

Categories: Dermatology

Keywords: prurigo nodularis, itch, chronic pruritus, skin nodules, prurigo nodularis (pn), acral

Introduction

Prurigo nodularis (PN) is a skin disease that manifests with severe itchy lesions described as well-defined, scaly, firm, hyperkeratotic itchy nodules [1]. The lesions are usually distributed on the trunk and the extremities symmetrically. This disease is challenging to treat, resulting in psychological and physical impacts, which can affect the quality of life [2]. The diagnosis is usually clinical and supported by biopsy [3]. Herein, we present a case of PN with an unusual presentation, which is limited to hands and feet.

Case Presentation

A 26-year-old male presented to the outpatient clinic with itchy skin lesions over his hands and feet for five years. Physical examination showed multiple well-defined, scaly, hyperpigmented nodules surrounded by violaceous borders with erosions over the dorsum of hands and feet (as shown in Figures 1, 2) and no lesions over the trunk or other areas of the body. He was managed first by clobetasol propionate 0.05% ointment and sodium fusidate 2% ointment two times a day, and levocetirizine 5 mg tablets at night with slight improvement. Past medical history was significant for Crohn's disease for six years on adalimumab 40 mg subcutaneously weekly, with no history of atopy or psychiatric illness. Workup for the patient was done, including complete blood count, liver function tests, renal function test, C-reactive protein (CRP), erythrocyte sedimentation rate (ESR), and viral hepatitis B and C screening, all of which were normal. The differential diagnosis was PN, hypertrophic lichen planus, and Kaposi sarcoma. A skin biopsy was taken from the left foot lesion. The result showed parakeratosis, acanthosis, and papillary dermal fibrosis (Figure 3) with elongation of rete ridges and superficial perivascular lymphocytes (Figure 4). There was no evidence of lichen planus, which supports the diagnosis of PN. After the diagnosis was made, cyclosporine 350 mg orally daily was started. The lesions and pruritus improved on cyclosporine. However, due to unexpected exacerbation of diarrhea and other gastrointestinal symptoms, the gastroenterology consultant held the medication.

How to cite this article

Albinhamad A, Almazied M, Alharithy R, et al. (September 21, 2022) Acral Prurigo Nodularis: A Case Report. Cureus 14(9): e29405. DOI 10.7759/cureus.29405

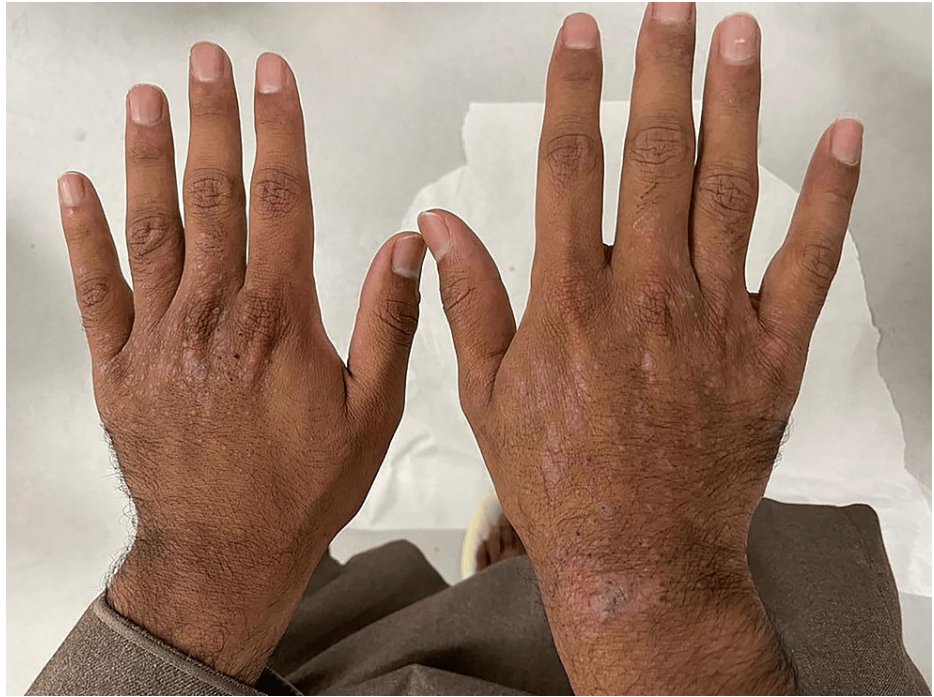

FIGURE 1: Multiple scaly, hyperkeratotic nodules and excoriations over the dorsal surface of both hands

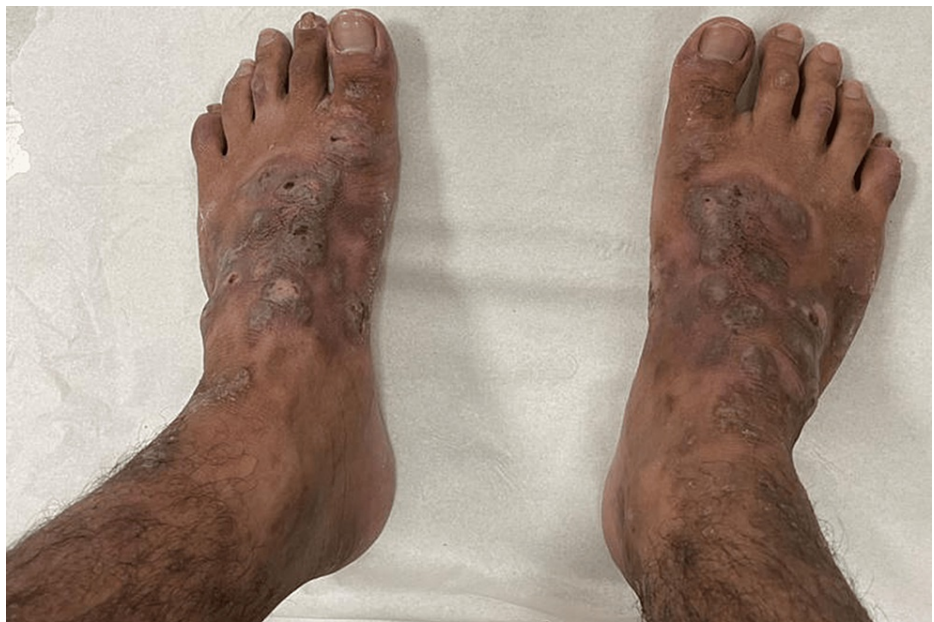

FIGURE 2: Multiple scaly, hyperkeratotic nodules and excoriations over the dorsal surface of feet

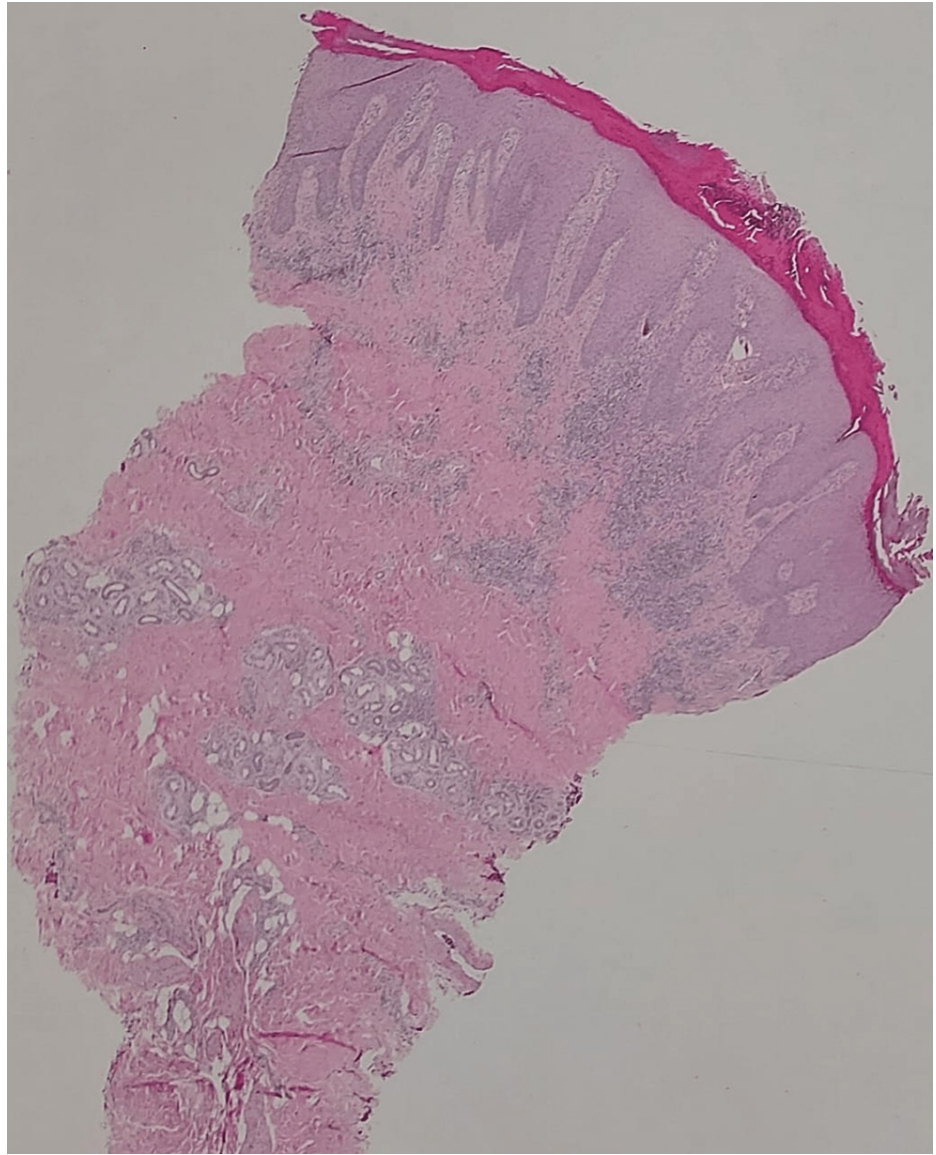


FIGURE 3: Hematoxylin and eosin stain showing a photomicrograph of low power view revealing hyperkeratosis, irregular acanthosis, and papillary dermal fibrosis (original magnification, 40x)

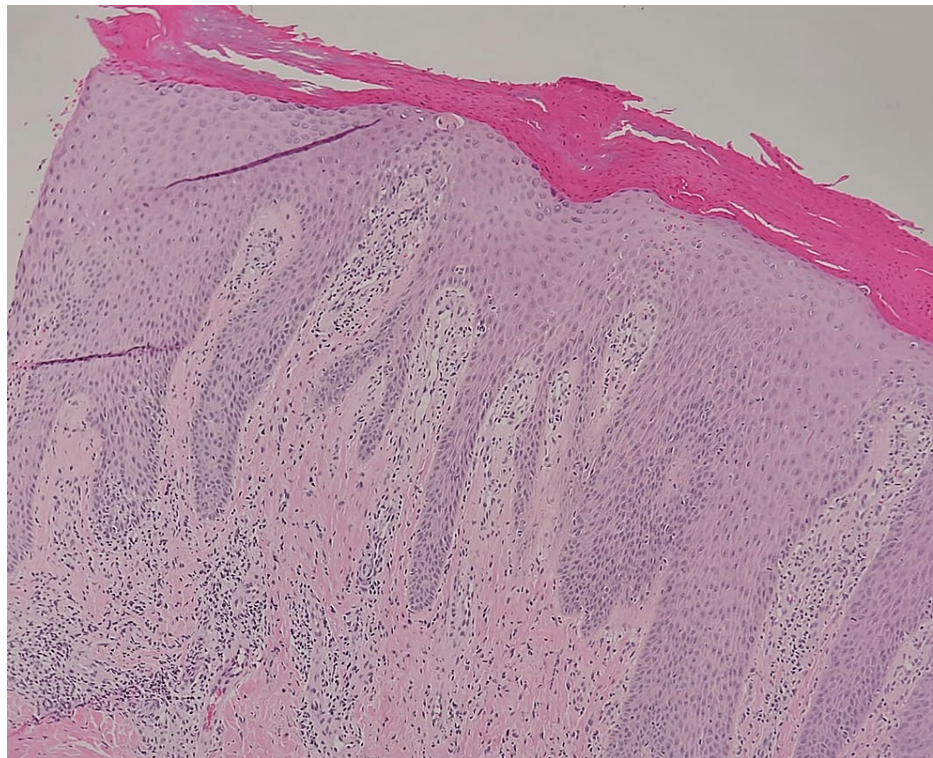


FIGURE 4: Hematoxylin and eosin stain with a higher power view showing elongation of rete ridges and superficial perivascular lymphocytes (original magnification, 200x)

Discussion

It is well known that PN presents as itchy nodules that symmetrically affect the trunk and the extensors. However, our patient developed PN lesions over the hands and feet only (as seen in Figures 1, 2), sparing other body regions. Limited cases reported on the MIDLINE database described unique distributions of PN. There were only five reported cases of distinctive PN presentations. In 1993, Chiewchanvit et al. reported a case of a 40-year-old male with positive human immunodeficiency virus who developed acquired immunodeficiency syndrome associated with cutaneous cytomegalovirus infection presented as multiple PN-like lesions on both legs and feet [4]. In 2007, De et al. reported a case of a 60-year-old female with PN limited to thigh and buttock after six months of herpes zoster lesion at exact distribution [5]. In 2008, Lezcano et al. reported a unique presentation of a child aged one year and seven months with PN limited only over the axillary area symmetrically [6]. In 2017, Paul et al. reported a case of a 73-year-old male who presented with a well-circumscribed white tumor over the inner corner of the upper eyelid. The tumor was excised, and the biopsy showed PN as a definitive diagnosis [7]. In 2017, Akhtar et al. reported a case of a 19-year-old female with pruritus vulvae for three years that was resistant to treatment. Physical examination showed a dry patch measuring 0.5 x 1 cm on her vulva and a biopsy revealed PN [8]. Despite a few reported cases of unique presentations of PN, our case is the first reported case of PN with limited involvement over the acral areas only.

Conclusions

PN is a dermatological disease that classically affects the trunk and extremities. Few cases reported unusual presentations. However, this is the first case that reported exclusively acral distribution that has been proven with histopathology. PN should be considered for any patient with complaints of itchy hyperkeratotic nodules, even in acral presentation. After this report, we hope that other cases on acral distribution will be reported in the future.

Additional Information

Disclosures

Human subjects: Consent was obtained or waived by all participants in this study. **Conflicts of interest:** In compliance with the ICMJE uniform disclosure form, all authors declare the following: **Payment/services info:** All authors have declared that no financial support was received from any organization for the submitted work. **Financial relationships:** All authors have declared that they have no financial

relationships at present or within the previous three years with any organizations that might have an interest in the submitted work. **Other relationships:** All authors have declared that there are no other relationships or activities that could appear to have influenced the submitted work.

References

1. Vaidya DC, Schwartz RA: Prurigo nodularis: a benign dermatosis derived from a persistent pruritus . *Acta Dermatovenerol Croat*. 2008, 16:38-44.
2. Kowalski EH, Kneiber D, Valdebran M, Patel U, Amber KT: Treatment-resistant prurigo nodularis: challenges and solutions. *Clin Cosmet Investig Dermatol*. 2019, 12:163-72. [10.2147/CCID.S188070](https://doi.org/10.2147/CCID.S188070)
3. Kwon CD, Khanna R, Williams KA, Kwatra MM, Kwatra SG: Diagnostic workup and evaluation of patients with prurigo nodularis. *Medicines (Basel)*. 2019, 6:97. [10.3390/medicines6040097](https://doi.org/10.3390/medicines6040097)
4. Chiewchanvit S, Thamprasert K, Siriunkgul S: Disseminated cutaneous cytomegalic inclusion disease resembling prurigo nodularis in a HIV-infected patient: a case report and literature review. *J Med Assoc Thai*. 1993, 76:581-4.
5. De D, Dogra S, Kanwar AJ: Prurigo nodularis in healed herpes zoster scar: an isotopic response . *J Eur Acad Dermatol Venereol*. 2007, 21:711-2. [10.1111/j.1468-3083.2006.02007.x](https://doi.org/10.1111/j.1468-3083.2006.02007.x)
6. Lezcano L, Di Martino Ortiz B, Rodríguez Masi M, Knopfmacher O, Bolla de Lezcano L: Prurigo nodularis. (Article in Spanish). *Arch Argent Pediatr*. 2008, 106:446-9.
7. Paul S, Ribback S, Tost FH: Discolouration of upper lid skin - prurigo nodularis . *Klin Monbl Augenheilkd*. 2017, 234:33-5. [10.1055/s-0042-120541](https://doi.org/10.1055/s-0042-120541)
8. Akhtar K, Ansari M, Mohsin Z, Abid TK: Unusual case of pruritus vulvae (prurigo nodularis): a rare case report. *MOJ Surg*. 2017, 5:181-3. [10.15406/mojs.2017.05.00105](https://doi.org/10.15406/mojs.2017.05.00105)