

Healthy Birth after Use of Sperm from a Male Who Suffered from Copper Toxicity

Murid Javed¹, Essam Michael²

1. Astra Fertility Centre 2. Astra Fertility Centre, Mississauga, ON L4Z 1S2 Canada

✉ **Corresponding author:** Murid Javed, murid.javed@gmail.com

Disclosures can be found in Additional Information at the end of the article

Abstract

We report the birth a healthy baby after use of sperm from a male who suffered from copper toxicity due to prolonged occupational exposure to copper dust. The male had been working as plumber for many years. Copper dust inhalation had been occurring very often. Two years ago, the male partner was diagnosed with copper toxicity. After proper treatment of copper toxicity, the couple tried one ICSI cycle elsewhere but failed. At our clinic, the semen evaluation revealed very rare motile sperm. One sample was cryopreserved for ICSI back up. Due to extremely poor acrosome morphology, the oocytes were artificially activated with calcium ionophore. Twenty-one oocytes were injected; sixteen showed normal fertilization. The embryo transfer was performed on day five, which resulted in a clinical pregnancy. At six-week ultrasound, one fetal sac and heartbeat were detected. A healthy baby boy was delivered after 36 weeks gestation. The results of this study indicate that pregnancy and healthy birth are possible in a couple when the young male partner has suffered from copper toxicity and has severely compromised sperm quality.

Categories: Miscellaneous

Keywords: copper toxicity, plumbing, oocyte activation, male factor, multiple sclerosis

Introduction

The level of copper (Cu) in seminal plasma has a significantly inverse relationship with sperm concentration [1]. In the subfertile male, the Cu level in serum and seminal plasma is significantly higher than that in the fertile male [2]. The Cu significantly decreases the percentage of progressively motile spermatozoa over a three-hour incubation at 37°C. The spermatozoa do not regain motility even after extensive washing, prolonged dialysis, or treatment with Cu-specific chelating agents [3]. Approximately 17% of Cu is either tightly bound to spermatozoa or is within the cell and cannot be removed by repeated washing [4]. After 120 minutes of in vitro exposure to Cu, the sperm show significant reduction in viability and hypo-osmotic swelling response [5]. Because of these toxic effects of Cu on sperm, a Cu intrauterine device (Cu-IUD) is the most effective method available for emergency contraception. This device prevents fertilization by impairing sperm function. In addition, if fertilization has already occurred, Cu influences female reproductive tract and prevents endometrial receptivity [6].

A study on Cu-zinc mineworkers has observed a significant increase in lung cancer [7]. In addition, significant elevation of non-Hodgkin's lymphoma incidence is observed for male underground mine employees [7]. Significantly lower serum Zn and higher serum Cu levels are found in the Iranian multiple sclerosis patients compared with the controls [8]. The Cu and Zn play important roles in the onset and/or progression of amyotrophic lateral sclerosis, Alzheimer's disease, and Parkinson's disease [9].

Copper oxide nanoparticles (CuO NP) are used for their biocide potential; however, they are also

Received 04/30/2014

Review began 05/02/2014

Review ended 05/09/2014

Published 05/13/2014

© Copyright 2014

Javed et al. This is an open access article distributed under the terms of the Creative Commons Attribution License CC-BY 3.0., which permits unrestricted use, distribution, and reproduction in any medium, provided the original author and source are credited.

How to cite this article

Javed M, Michael E (2014-05-13 03:54:44 UTC) Healthy Birth after Use of Sperm from a Male Who Suffered from Copper Toxicity. Cureus 6(5): e180. DOI 10.7759/cureus.180

shown to be highly toxic to mammalian cells. They are found to induce DNA fragmentation, lipid peroxidation, and micronucleus formation. The micronucleus assay is the most sensitive to evaluate CuO NP genotoxicity, and micronucleus frequency is increased significantly after 24 hours of treatment [10]. Despite widespread toxicity, exposure to Cu in certain occupations, like Cu tubing plumbing, is inevitable. The objective of this study is to report primary infertility in a male due to copper toxicity and achievement of healthy delivery after ICSI and artificial oocyte activation.

Case Presentation

A 36-year-old woman and 33-year-old male presented with primary male factor infertility. The male partner had been working as plumber for five years. Two years ago, he was diagnosed with copper toxicity. The most likely but not a definite cause of copper toxicity was exposure to copper dust during Cu tubing plumbing because he is a plumber by profession. After receiving proper medical treatment for copper toxicity, the couple had attempted a failed ICSI cycle elsewhere before coming to our clinic. Three semen analyses, two at the previous fertility clinic at which the couple had a failed ICSI cycle and one at our clinic, indicated presence of rare sperm and abnormal morphology. At our laboratory, the sample was diluted with an equal amount of Quinn's Advantage Medium containing HEPES and 5% human serum albumin (HSA-SAGE). It was then centrifuged at 1700 rpm for 10 min. The pellet was re-suspended in 100 μ L, and a 12 μ L drop was examined on a slide under a cover glass. Only two sperm were observed on the entire slide, and one was motile. The acrosomes were either very small or absent. One semen sample was cryopreserved for ICSI backup before initiating ovarian stimulation.

The investigation of the male serum hormonal profile indicated normal LH, FSH, and TSH levels; however, the testosterone level was lower than normal (4.1 nmole per liter). The male partner also suffered from multiple sclerosis (MS), most likely due to a long exposure to Cu. The male had a normal 46XY karyotype. No apparent infertility risk factors were detected in the female partner.

Ovarian stimulation was performed using long Lupron (AbbVie, Canada) and Gonal-F (EMD Serono, Canada). Daily doses of 0.1 mg per day of subcutaneous Lupron and 188 IU Gonal F were administered starting day three of the cycle for 12 days. Follicular development was monitored by serial serum estradiol monitoring and transvaginal ultrasound. Ovidrel, 250 IU (EMD Serono, Canada), was administered when optimal follicular development was achieved. Oocyte retrieval was performed by transvaginal ultrasound, 36 hours after Ovidrel administration. Prometrium (Merck, Canada) provided luteal support. All of the female partner's hormones were within normal limits.

On the day of ovum pick-up, the male partner provided two semen samples. Simple washing and centrifugation of the pooled samples retrieved motile sperm. However, after processing, very rare motile sperm were available. The sperm head morphology was extremely poor, with either very small or no acrosome present. At the time of ICSI, efforts were made to inject oocytes with relatively normal and motile sperm.

After retrieval, the oocytes were washed and cultured in Quinn's Advantage Fertilization Medium (QAFM; SAGE) supplemented with 10% Serum Protein Supplement (SPS-SAGE) in 6% CO₂ and 37° C for four hours before denudation which was carried out by mechanical pipetting in 40 IU/mL of hyaluronidase (Sigma, Canada) in Quinn's Advantage Medium containing HEPES and 10% SPS (QAM-H, SAGE). Subsequently, ICSI was performed in QAM-H at 400 X magnification using a Leica inverted microscope.

Artificial oocyte activation was carried out 30 minutes after ICSI with calcium ionophore (A23187, Ionomycin calcium salt; Sigma, St. Louis, MO). The oocytes were placed in QAFM containing 5 mM calcium ionophore, under humidified atmosphere of 6% CO₂ in air. Fertilization was checked

18 hours after ICSI. The embryo transfer took place on day five at blastocyst stage. Figure 1 presents the quality of oocytes, pronuclear, cleavage, and blastocyst stage embryos.

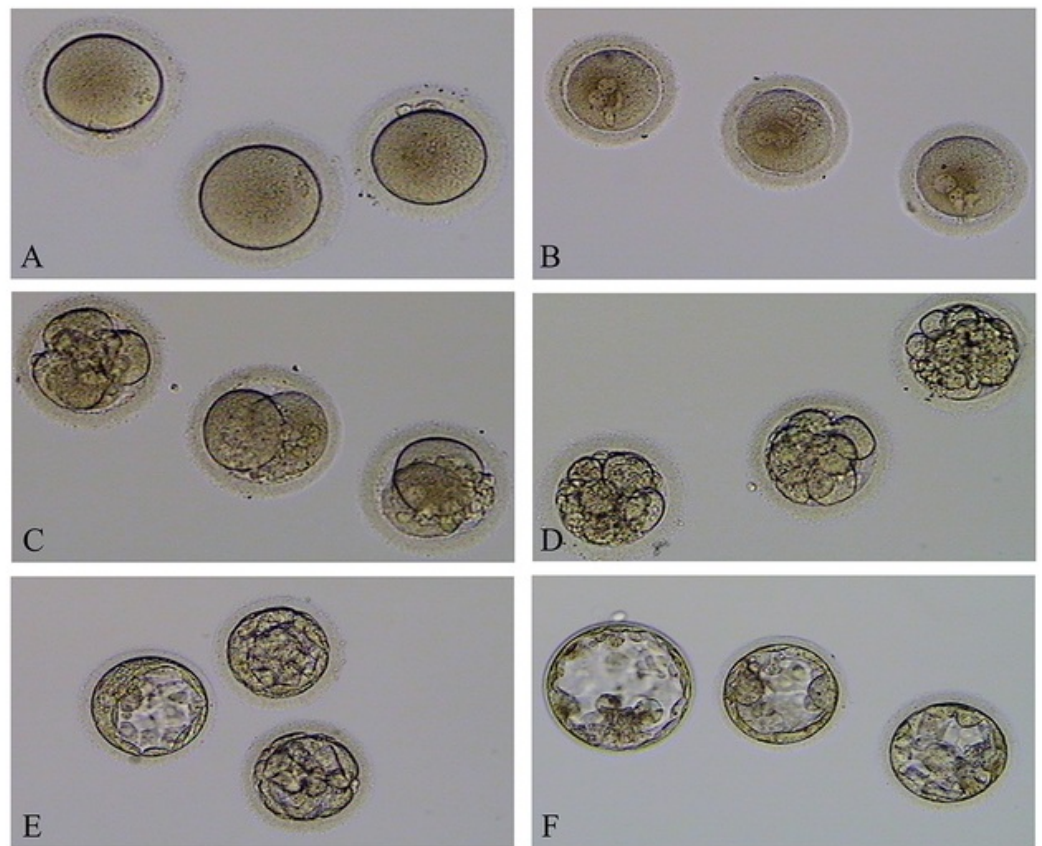


FIGURE 1: The quality of unfertilized oocytes, pronuclear, cleavage and blastocyst stage embryos.

A. Unfertilized oocytes; B. Pronuclear embryos; C. Day-2 embryos; D. Day-3 embryos; E. Day-5 transferred blastocysts and F. Cryopreserved embryos.

Twenty-one oocytes were retrieved; 11 were MII and the remaining, MI. After two hours in culture, the MI progressed to MII. All 21 oocytes were injected and artificially activated using Ca ionophore as described above. Sixteen eggs showed normal fertilization. On day two, all fertilized eggs cleaved but resulted in poor quality embryos. On day three, four embryos were at eight cells Grade II, three embryos were at 10 cells Grade II, and the remaining were highly fragmented. In our grading system, Grade I is the best and Grade V, the lowest grade. On day five, one embryo developed to blastocyst (early blastocyst one BB) and in the other two a small cavity was visible. These three embryos were transferred into uterus on day five (Figure 1 E). On day six, three embryos developed to blastocyst (expanded blastocyst four BB, blastocyst two BB, and blastocyst one BB; Figure 1F) and were vitrified. The remaining embryos degenerated and were discarded.

The embryo transfer resulted in clinical pregnancy. The hCG levels were 176 and 320 mIU/mL, 14 and 16 days post-oocyte retrieval, respectively. One fetal sac and a heart were detected on six-week ultrasound. A normal healthy baby boy weighing 4,252 grams was delivered after 36 weeks gestation.

Discussion

This study indicates that pregnancy and a healthy birth is possible in a couple when the male

partner has had a long exposure to copper. The Cu is an essential trace element for human physiological processes; however, overexposure of this metal exerts potential adverse health impacts/immunotoxicological effects [11]. Studies on the presence of Cu in human seminal plasma provide evidence for inverse relationships between human semen quality and Cu concentration. Of the 100 men, 21 had fertility problems and Cu concentrations were significantly higher in this group than that in the normal group [1]. The blood obtained from 60 subfertile men and 40 fertile volunteers indicated that Cu levels in serum and seminal plasma in the subfertile male group were significantly higher than those in the fertile group were. The earlier authors suggested that Cu might be mediator of the effects of oxidative damage and play an essential role in spermatogenesis and male infertility [2]. The results of in vitro studies indicate that Cu induces irreversible immobilization of human spermatozoa [3].

In vivo and in vitro studies in rats have indicated that Cu is highly toxic to spermatozoa. The Cu administration for eight weeks resulted in significant decrease in sperm concentration, motility, and viability [12] and an increase in the proportion of morphologically abnormal sperm forms [13]. The evidence of disorders in spermatogram's parameters was directly dependent on the duration of the influence [13]. Long-term Cu administration leads to histological impairments of testes. The Cu-treated groups show significant decrease in diameter of seminiferous tubules and sertoli cells nuclei, epithelial height, meiotic index, and the percentage of spermatogenesis [14]. A single injection of 10 mg metallic copper particles in oil into each caput epididymitis induces infertility in male rats, leaving the mating behavior and blood testosterone levels unchanged. The pachytene spermatocytes and early spermatids show different degrees of damage, including vacuolation, karyorrhexis, pyknosis, and cytolysis. The viability of epididymal sperm decreases more markedly than the decrease in sperm density [15].

The data obtained from in vitro studies evidently confirmed adverse effects of high copper sulphate concentrations on rabbit spermatozoa motility, morphology, and membrane integrity. The concentration of CuSO_4 in the medium varied from 3.57 to 4.85 $\mu\text{g/mL}$. After one hour of incubation with CuSO_4 , the motility significantly decreased almost in all experimental groups. After 24 and 48 hours of incubation, almost all the spermatozoa were dead at all concentrations. The total percentage of morphologically abnormal spermatozoa was significantly higher in the group with the highest copper concentration (46.20+/-5.54%) in comparison to control (30.60+/-2.91). Predominant morphological abnormalities were acrosomal changes, knob-twisted flagellum, and small heads [16]. The male partner discussed in this report had history of long exposure to copper dust. All sperm parameters were severely affected. The couple already had a failed ICSI cycle elsewhere; therefore, to avoid risk of poor or no fertilization, the oocytes were artificially activated by Ca ionophore.

The definite cause of MS is unknown. It may be due to the interaction of genetic and environmental factors [17-18]. It has been suggested that the environment acted long before MS became clinically evident [19]. The Cu plays key role in brain metabolism, and disorders of copper metabolism impact neural signaling. In vitro exposure of neuronal cells to copper decreases their survival significantly. In vivo, copper exposure impairs regulation of glutamate in the brain, increases production of nitric oxide, and markedly enhances the excitability. The excessive Cu interacts with oxygen and generates reactive species. Its overload induces mitochondrial dysfunction [20]. The Cu has been implicated in different neurological disorders, such as Wilson's, Menkes', Alzheimer's, and Parkinson's diseases [21] as well as MS [8]. Significantly higher serum Cu levels are found in the MS patients compared with that in the controls [8]. The intranasally-instilled copper nanoparticles not only cause lesions where the Cu accumulated, but also affect the neurotransmitter levels in the brain [22]. The Cu is also immunotoxic as Cu treated mice evidence immunotoxicity as indicated by dose-related decreases and increases, respectively, in thymic and splenic weights. Histomorphological changes evidenced in these organs are thymic atrophy, white pulp shrinkage in the spleen, and apoptosis of splenocytes and thymocytes [11]. The male patient under consideration had long Cu exposure before developing MS. It is likely

that Cu intoxication predisposed him to MS. The available literature supports this view [8-9].

Conclusions

The results of this study indicate that pregnancy and delivery of a healthy child is possible in a couple when the infertile male partner had a long history of exposure to Cu. Determination of Cu levels in serum and seminal plasma during infertility investigation in males at risk of exposure to Cu is recommended.

Additional Information

Disclosures

Conflicts of interest: The authors have declared that no conflicts of interest exist.

References

1. Li P, Zhong Y, Jiang X, Wang C, Zuo Z, Sha A: Seminal plasma metals concentration with respect to semen quality. *Biol Trace Elem Res.* 2012, 148:1-6. [10.1007/s12011-012-9335-7](https://doi.org/10.1007/s12011-012-9335-7)
2. Aydemir B, Kiziler AR, Onaran I, Alici B, Ozkara H, Akyolcu MC: Impact of Cu and Fe concentrations on oxidative damage in male infertility. *Biol Trace Elem Res.* 2006, 112:193-203.
3. Holland MK, White IG: Heavy metals and human spermatozoa. II. The effect of seminal plasma on the toxicity of copper metal for spermatozoa. *Int J Fertil.* 1982, 27:95-9.
4. Holland MK, White IG: Heavy metals and human spermatozoa. III. The toxicity of copper ions for spermatozoa. *Contraception.* 1988, 38:685-95.
5. Misro MM, Chaki SP, Chandra M, Maheshwari A, Nandan D: Release of copper from CuT 380A co-incubated with human semen and its effect on sperm function in vitro. *Indian J Physiol Pharmacol.* 2008, 52:267-73.
6. Gemzell-Danielsson K, Berger C, P G L L: Emergency contraception -- mechanisms of action . *Contraception.* 2013, 87:300-8. [10.1016/j.contraception.2012.08.021](https://doi.org/10.1016/j.contraception.2012.08.021)
7. Lightfoot NE, Berriault CJ: Mortality and cancer incidence in a copper-zinc cohort . *Workplace Health Saf.* 2012, 60:223-33. [10.3928/21650799-20120426-02](https://doi.org/10.3928/21650799-20120426-02)
8. Ghazavi A, Kianbakht S, Ghasami K, Mosayebi G: High copper and low zinc serum levels in Iranian patients with multiple sclerosis: A case control study. *Clin Lab.* 2012, 58:161-4.
9. Hozumi I, Hasegawa T, Honda A, Ozawa K, Hayashi Y, Hashimoto K, Yamada M, Koumura A, Sakurai T, Kimura A, Tanaka Y, Satoh M, Inuzuka T: Patterns of levels of biological metals in CSF differ among neurodegenerative diseases. *J Neurol Sci.* 2011, 303:95-9. [10.1016/j.jns.2011.01.003](https://doi.org/10.1016/j.jns.2011.01.003)
10. Perreault F, Melegari SP, da Costa CH, de Oliveira Franco Rossetto AL, Popovic R, Matias WG: Genotoxic effects of copper oxide nanoparticles in Neuro 2A cell cultures . *Sci Total Environ.* 2012, 441:117-24. [10.1016/j.scitotenv.2012.09.065](https://doi.org/10.1016/j.scitotenv.2012.09.065)
11. Mitra S, Keswani T, Dey M, Bhattacharya S, Sarkar S, Goswami S, Ghosh N, Dutta A, Bhattacharyya A: Copper-induced immunotoxicity involves cell cycle arrest and cell death in the spleen and thymus. *Toxicology.* 2012, 293:78-88. [10.1016/j.tox.2011.12.013](https://doi.org/10.1016/j.tox.2011.12.013)
12. Sakhaee E, Emadi L, Abshenas J, Kheirandish R, Azari O, Amiri E: Evaluation of epididymal sperm quality following experimentally induced copper poisoning in male rats. *Andrologia.* 2012, 44:110-6. [10.1111/j.1439-0272.2010.01147.x](https://doi.org/10.1111/j.1439-0272.2010.01147.x)
13. Romaniuk AM, Sauliak SV, Moskalenko RA, Moskalenko IuV: Spermatogenic function under the influence of heavy metal salts and its correction by preparation Tivortin (in Ukrainian). *Lik Sprava.* 2012, Jan-Mar:123-8.
14. Kheirandish R, Askari N, Babaei H: Zinc therapy improves deleterious effects of chronic copper administration on mice testes: Histopathological evaluation. *Andrologia.* 2014, 46:80-5. [10.1111/and.12047](https://doi.org/10.1111/and.12047)
15. Xu Y, Xiao FL, Xu N, Qian SZ: Effect of intra-epididymal injection of copper particles on fertility, spermatogenesis, and tissue copper levels in rats. *Int J Androl.* 1985, 8:168-74.
16. Roychoudhury S, Massanyi P, Bulla J, Choudhury MD, Straka L, Lukac N, Formicki G, Dankova M, Bardos L: In vitro copper toxicity on rabbit spermatozoa motility, morphology and cell membrane integrity. *J Environ Sci Health A Tox Hazard Subst Environ Eng.* 2010, 45:1482-91. [10.1080/10934529.2010.506092](https://doi.org/10.1080/10934529.2010.506092)

17. Marrie RA: Environmental risk factors in multiple sclerosis aetiology . *Lancet Neurol.* 2004, 3:709-18.
18. Spirin NN, Kachura DA, Ershov MB, Dzhurko IuA, Shitov LN: Clinical and epidemiological peculiarities of multiple sclerosis in patients with different level of essential and toxic chemicals in blood serum (in Russian). *Zh Nevrol Psikhiatr Im S S Korsakova.* 2011, 111:10-15.
19. Ramagopalan SV, Dobson R, Meier UC, Giovannoni G: Multiple sclerosis: risk factors, prodromes, and potential causal pathways. *Lancet Neurol.* 2010, 9:727-39. [10.1016/S1474-4422\(10\)70094-6](https://doi.org/10.1016/S1474-4422(10)70094-6)
20. Marmolino D, Manto M: Pregabalin antagonizes copper-induced toxicity in the brain: In vitro and in vivo studies. *Neurosignals.* 2010, 18:210-22. [10.1159/000322544](https://doi.org/10.1159/000322544)
21. Lung S, Li H, Bondy SC, Campbell A: Low concentrations of copper in drinking water increase AP-1 binding in the brain. *Toxicol Ind Health.* 2013, May 29:[Epub ahead of print].
22. Zhang L, Bai R, Liu Y, Meng L, Li B, Wang L, Xu L, Le Guyader L, Chen C: The dose-dependent toxicological effects and potential perturbation on the neurotransmitter secretion in brain following intranasal instillation of copper nanoparticles. *Nanotoxicology.* 2012, 6:562-75. [10.3109/17435390.2011.590906](https://doi.org/10.3109/17435390.2011.590906)