

Demyelinating Pseudotumour : A case report.

Abel Devadass , Duncan Lamont¹, Zakier Hussain², Thirayan Muthu², Venkataraman Balakrishnan², Kirsty Andrews³

Corresponding Author: Abel Devadass

1. Department of Pathology, Waikato Hospital, Hamilton, New Zealand 2. Department of Neurosurgery, Waikato Hospital, Hamilton, New Zealand 3. Medlab Central, Palmerston North Hospital

Categories: Neurological Surgery, Radiology, Pathology

Keywords: multiple sclerosis, demyelination, malignant brain tumour, pseudotumour

How to cite this article

Devadass A, Lamont D, Hussain Z, et al. (2013) Demyelinating Pseudotumour : A case report.. Cureus 5(11): e146. doi:10.7759/cureus.146

Abstract

Cerebral demyelinating disease is a neurological condition and cerebral lesions caused by demyelinating disease may simulate cerebral tumours. This is a case report of an 84 year old patient with progressively worsening neurological symptoms and an MRI scan showing a lesion resembling a malignant glioma. The histological examination of this lesion confirmed a demyelinating pseudotumour. A review of the literature revealed conflicting findings in the radiological and histological features of this lesion. It is imperative that careful analysis of these investigations be carried out before a definitive diagnosis of a demyelinating pseudotumour is made in order to ensure appropriate patient management.

Open Access

Case Report

Published 11/18/2013

DOI: 10.7759/cureus.146

Copyright

© 2013 Devadass et al.

Distributed under
Creative Commons CC-BY 3.0

Introduction

Demyelinating disease may present as a contrast-enhancing lesion in the brain causing clinical features similar to a malignant brain tumour.

Case Presentation

An 84 year old gentleman was admitted with a six week history of insidious onset, progressively worsening nominal aphasia, poor memory and loss of interest in daily activities. On examination he had receptive and expressive dysphasia and mild right sided facial weakness. Computerised tomography (CT) and Magnetic Resonance Imaging (MRI) demonstrated a large heterogenous complete ring-enhancing mass with mixed solid and cystic components in the left temporal lobe and surrounding oedema causing mass effect and midline shift. There was an incidental left temporal arachnoid cyst.

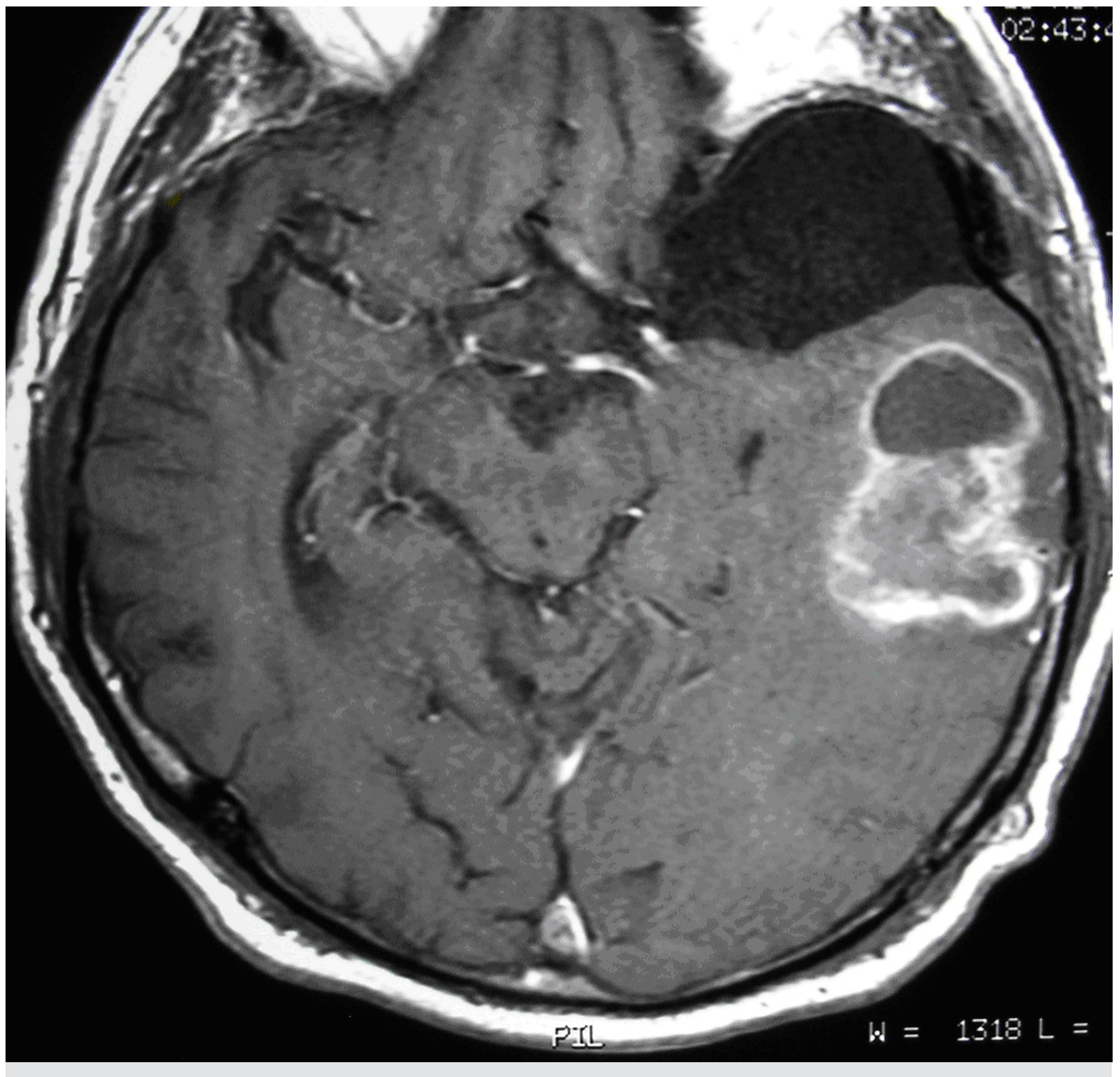


Figure 1:

Contrast enhancing left temporal lobe lesion. Incidental left temporal arachnoid cyst.

MR spectroscopy revealed elevated lactate and choline levels raising the suspicion of a malignant brain tumour. The patient underwent a left temporal craniotomy and debulking of the intrinsic brain lesion. Histologically, the lesion comprised numerous histiocytes, reactive gemistocytes and Creutzfeldt astrocytes containing granular mitoses with abundant associated necrosis and thrombosed vessels. No malignant cells were seen.

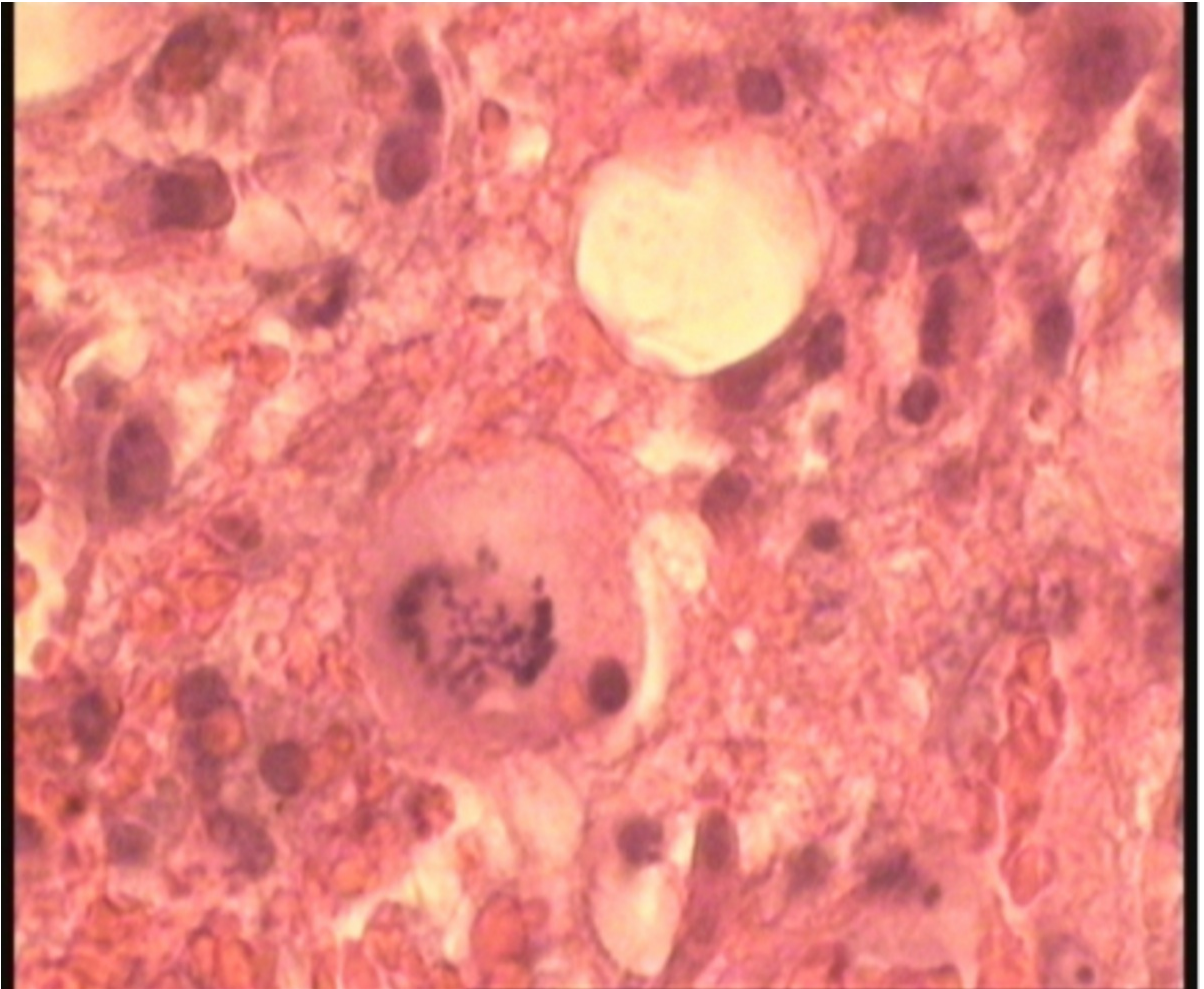


Figure 2:

Creutzfeldt astrocyte with abundant eosinophilic cytoplasm and tiny punctate chromatin bodies (granular mitoses)

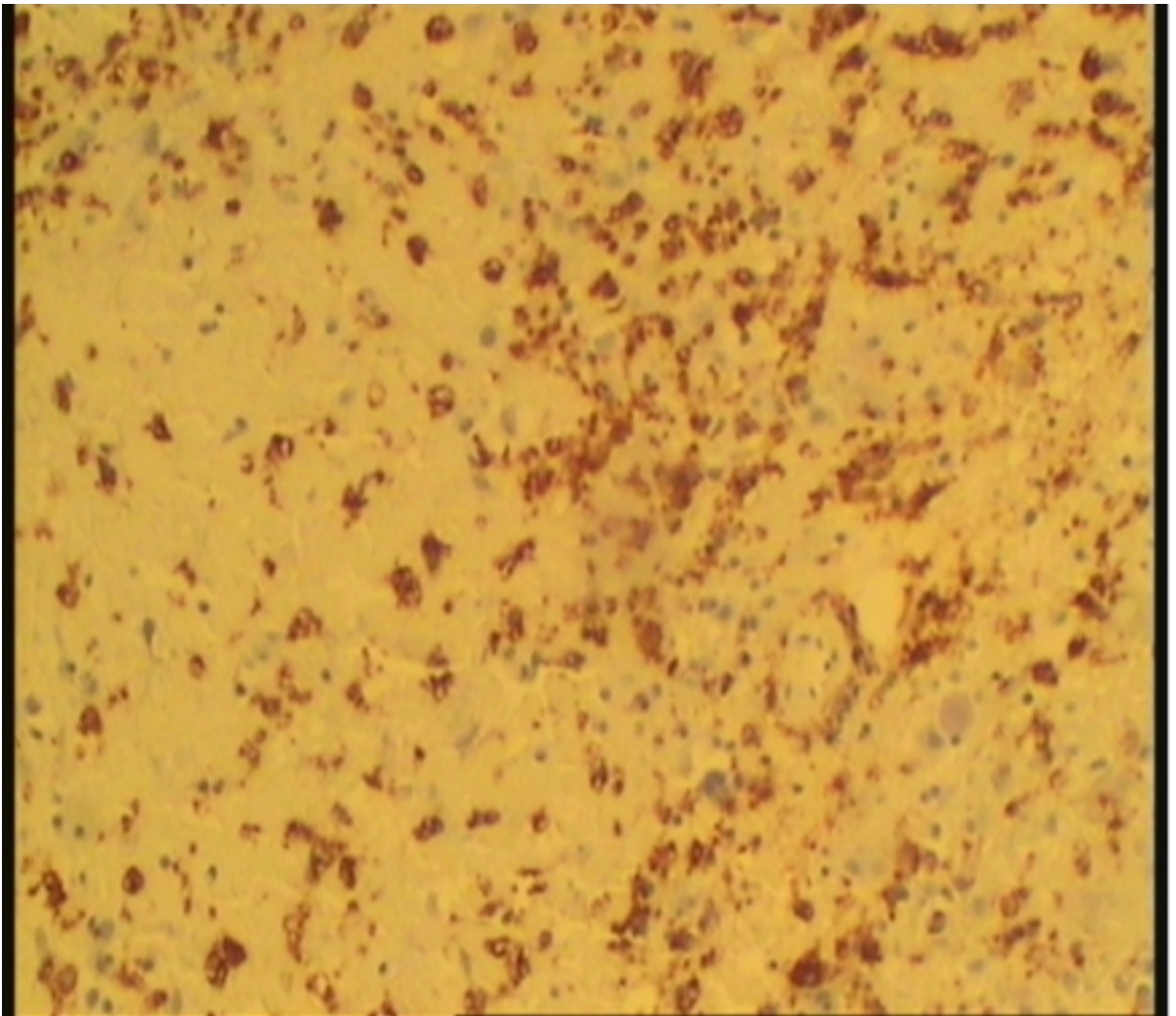


Figure 3:
CD68 stain showing evidence of macrophagic infiltration

Discussion

Demyelinating conditions of the brain and spinal cord can rarely present as a ring-enhancing lesion simulating a malignant brain tumour. It has been suggested that demyelinating lesions exhibit a particular appearance on CT with incomplete, C shaped or 'open ring' enhancement as opposed to the complete ring of enhancement displayed by abscesses and tumours [1]. However, this open ring sign is only present in 70% of demyelinating cases [2]. Our case had complete ring-enhancement thus falls into the 30% of cases which do not show the characteristic appearance on CT.

Our case also showed evidence of cerebral oedema and mass effect surrounding the lesion suggesting it could be a neoplasm. Review of the literature shows conflicting evidence as to whether or not this is a diagnostic finding. In a retrospective review of 40 patients with biopsy or autopsy proven demyelinating lesions, only 3 patients had

minimal oedema and mass effect while one patient had moderate oedema and severe mass effect on radiological imaging [3]. Three case reports describing cerebral demyelinating lesions also demonstrated conflicting evidence in relation to the presence of mass effect surrounding these lesions on radiological imaging [4,5,6].

Due to these variable findings on radiological imaging, careful histological examination is paramount in confirming the diagnosis. Histologically, specimens usually show diffuse infiltration by foamy, lipid laden macrophages and reactive astrocytes (gemistocytes) displaying enlarged, hyperchromatic nuclei with perivascular aggregates of small lymphocytes and occasional plasma cells [7]. Enlarged multinucleated 'Creutzfeldt astrocytes' with fragmented nuclei (granular mitoses) and abundant eosinophilic cytoplasm may be present [1,8]. Tissue infiltration by macrophages occurs as they enact myelin phagocytosis but there is usually no associated vascular proliferation [1]. In contrast, untreated gliomas very rarely show macrophagic infiltration and may have vascular proliferation [7]. To aid diagnosis further a modified silver stain (Luxol fast blue/periodic acid schiff) is used to stain myelin highlighting foci of demyelination in which axons are preserved [1].

There is conflicting evidence on whether these lesions have concomitant necrotic areas. One study suggested that these lesions are not associated with necrosis [9] but a separate study demonstrated central necrosis within these lesions [4]. In our case the lesion showed abundant necrosis.

Conclusions

Demyelinating disease should be considered in the differential diagnosis for patients presenting with ring-enhancing lesions in the brain. Careful histological analysis is important in confirming the diagnosis before any further treatment is considered. There is conflicting evidence in the literature with regards to radiological and histological findings such as the presence of oedema or necrosis. However, there are common features found in these cases such as contrast enhancement on radiological imaging, macrophagic infiltration and reactive astrocytes histologically.

Additional Information

Disclosures

The authors have no conflict of interest to disclose.

Acknowledgements

The authors wish to acknowledge Dr Glenn Coltmann (Radiologist, Waikato Hospital, Hamilton, New Zealand) for his contribution.

References

1. Di Patre PL, Castillo V, Delavelle J, Vuillemoz S, Picard F, Landis T: [‘Tumour-mimicking’ multiple sclerosis](#). Clinical Neuropathology 2003, 22:235-239.
2. Erana-Rojas IE, Barboza - Quintana A, Ayala AG, Fuller GN: [Demyelinating Pseudotumor](#). Annals of Diagnostic Pathology 2002, 6:265-271.
3. Iwamoto K, Oka H, Utsuki S, Ozawa T, Fujii K.: [Late onset multiple sclerosis mimicking brain tumour : a case report](#). Brain Tumour Pathology 2004, 21:83-86.
4. Jain D, Rajesh LS, Vasishtha RK, Radotra BD, Banerjee AK.: [Demyelinating disease simulating brain tumours : A histopathologic assessment of seven cases..](#) Indian Journal of Medical Science 2006, 60:47-52.
5. Masdeu JC, Quinto C, Olivera C, Tenner M, Leslie D and Visintainer P: [Open-ring imaging sign. Highly specific for atypical brain demyelination](#). Neurology 2000, 54:1427-1433.
6. Mastrostefano R, Occhipinti E, Bigotti G, Pompili A: [Mastrostefano R, Occhipinti E, Bigotti G, Pompili A..](#) Neurosurgery 1987, 21:244-246.
7. Nesbit GM, Forbes GS, Scheihauer BW, Okazaki H, Rodriguez M: [Multiple Sclerosis : Histopathologic and MR and/or CT correlation in 37 cases at biopsy and three cases at autopsy](#). Radiology 1991, 180:467-474.
8. Rosai J: [Rosai and Ackerman’s Surgical Pathology](#). New York: Mosby; 2004.
9. Sofroniew MV, Vinters HV: [Astrocytes : biology and pathology](#). Acta Neuropathologica 2010, 119:7-35.