

Endovascular Repair of a Ruptured Giant 11 cm Abdominal Aortic Aneurysm

James L. West¹, Hakan Charles-Harris²

1. Florida International University Herbert Wertheim College of Medicine 2. FIU Endovascular Institute, Jackson North Medical Center; Florida International University Herbert Wertheim College of Medicine

✉ **Corresponding author:** James L. West, jwest008@fiu.edu

Disclosures can be found in Additional Information at the end of the article

Abstract

Rupture of an abdominal aortic aneurysm (AAA) can be a catastrophic event for a patient, with many patients who rupture dying before they ever make it to the hospital for assessment. Once assessed and treated, patients are by no means out of the woods, as the overall mortality for patients undergoing repair of AAA is still quite high post-intervention. Here we present an interesting case of a 62 year old African-American male who presented to our community hospital with a ruptured AAA measuring 11 cm at its maximum diameter. This is one of the largest ruptured AAA's to ever be reported in the literature. We treated this patient with endovascular placement of stent-grafts, making this one of the largest ever endovascular repairs undertaken. This patient made an optimal recovery post-intervention and is alive and well today.

Categories: Radiology, General Surgery, Neurosurgery

Keywords: endovascular repair, giant abdominal aortic aneurysm, ruptured aneurysm, community hospital

Introduction

Ruptured abdominal aortic aneurysms (AAA) represent an emergency that mandates immediate attention. This condition is the 13th leading cause of death in the United States, and as such, aneurysms represent a pathology that needs to be better understood and studied if improved interventions and treatments are to be developed [1]. To this end, the mortality rate of patients who survive long enough to present to the ED for open repair is only 40%. This extremely high mortality, combined with the fact that most AAA's are asymptomatic until they bleed, only enhances the need for improved interventions that can be applied quickly and effectively by a wide spectrum of healthcare providers. It is important that the interventions developed be able to be implemented in more settings than highly specialized academic Vascular Departments, because for these patients, survival depends on quick, effective interventions implemented as close as possible to the level of care where they most commonly present, e.g. a community hospital setting.

Currently, there are two modalities used in the repair of an abdominal aortic aneurysm; open and endovascular repair. Endovascular interventions for AAA were first pioneered by Parodi in elective repairs in 1991 [2]. Since then, the use of the endovascular approach to AAA repair has gained support because of its minimally invasive nature as well as proven decreases in the 30 day mortality [3]. In 2000 the FDA approved the use of endovascular repair (EVAR); since then it has been proven to decrease the perioperative mortality, decrease blood loss, transfusion requirement and intensive care unit stay [4]. The EVAR procedure involves transfemoral insertion of a stent graft made of fabric and self-expanding metal stents that attach to a segment of healthy aorta below the renal arteries and again to the healthy iliac arteries below, thereby excluding the aneurysm [5]. Not everyone is a candidate for EVAR. In order to be a candidate for

Received 02/15/2013

Review began 02/15/2013

Published 02/17/2013

© Copyright 2013

West et al. This is an open access article distributed under the terms of the Creative Commons Attribution License CC-BY 3.0., which permits unrestricted use, distribution, and reproduction in any medium, provided the original author and source are credited.

How to cite this article

West J L, Charles-harris H (2013-02-17 05:01:45 UTC) Endovascular Repair of a Ruptured Giant 11 cm Abdominal Aortic Aneurysm. Cureus 5(2): e95. DOI 10.7759/cureus.95

EVAR, there must be an adequate segment of healthy aorta below the renal arteries as well as adequate access vessels (iliac arteries). This is typically assessed by preoperative computerized tomography (CT) angiography [6]. Because of these limitations imposed by the vascular anatomy of the patient, only about 12% of ruptured AAA's are currently being repaired using endovascular interventions [7]. We present this case in order to demonstrate the effectiveness of the endovascular approach to repair a giant 11 cm ruptured AAA in the setting of a local community hospital.

Case Presentation

A 62 year old African American male with a history of hypertension, smoking for over 30 years, excessive alcohol consumption, and living in an assisted living facility was in bed and sat up; he tried to stand up when he felt faint and collapsed. He was rushed to the emergency room; while there he was noted to have a pulsatile mass in the abdomen. After resuscitation and stabilization, a CT scan of the abdomen and pelvis was performed. He was also noted to be hypertensive upon arrival. The CT scan revealed a rupture in the right lower quadrant of a very large abdominal aortic aneurysm measuring 11 cm in diameter (Figures 1, 2). The rupture was deemed to be infra-renal in nature extending from 2 cm below the renal arteries to the level of the bifurcation into the right and left common iliac arteries. There appeared to be normal flow into the iliac and femoral arteries; however, on the right side, the CT scan revealed stenosis of the right external iliac artery.

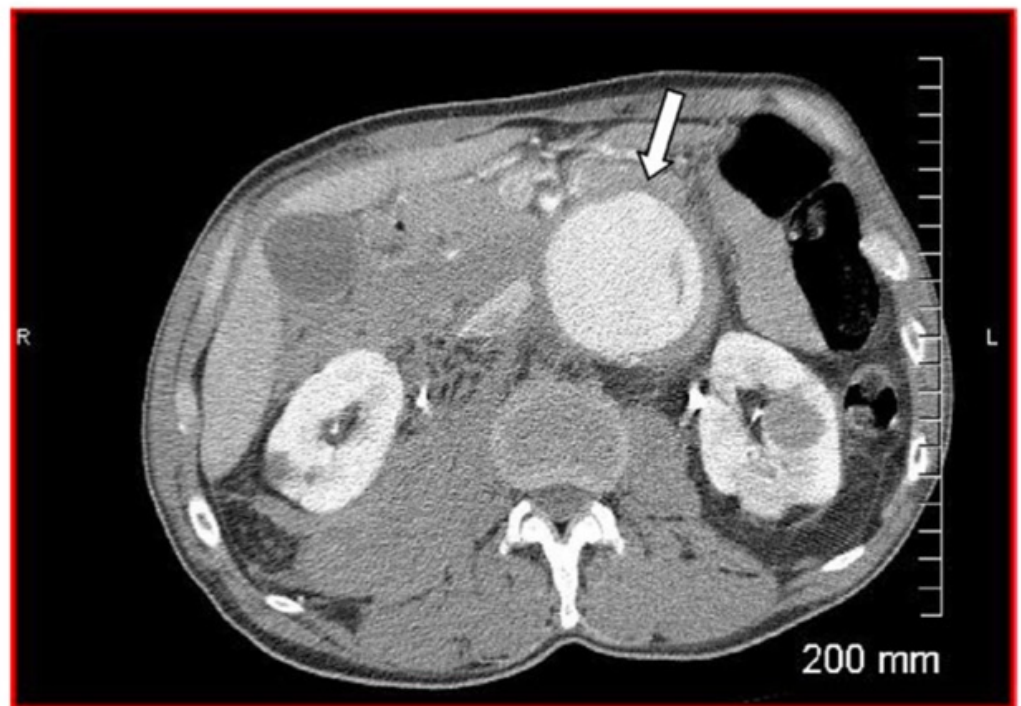


FIGURE 1: Axial CT image of the abdomen with IV contrast showing large abdominal aortic aneurysm (arrow).

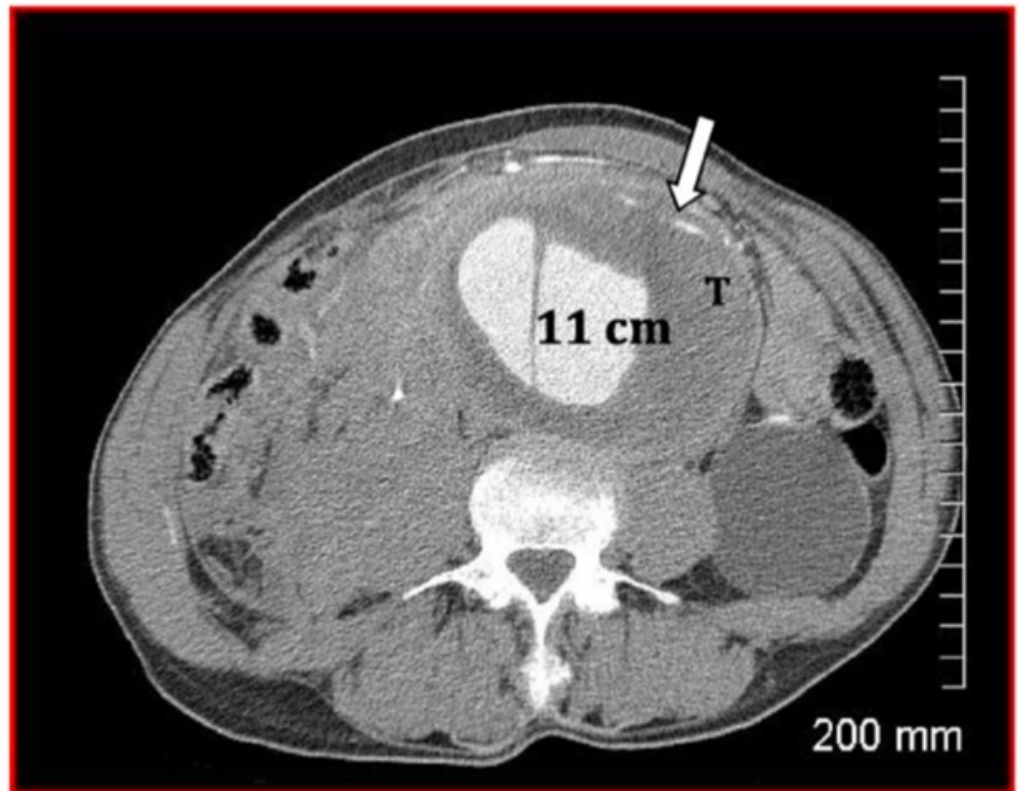


FIGURE 2: An intramural thrombus, T, dissection and rupture into the right retroperitoneum.

Upon physical examination he was found to be afebrile, with vital signs showing a blood pressure of 110/70, heart rate of 130 and respiration of 24. Heart sounds 1 and 2 were heard with no murmur or rubs. His peripheral pulses were abnormal with no palpable pulse in the right groin and no palpable distal pulse in the right foot. The left groin had a normal palpable pulse and dopplerable dorsalis pedis and posterior tibial pulse in the left foot. His abdomen was soft with a large, expansile and pulsating mass in the central upper abdomen occupying most of the abdomen. Bowel sounds were present and of normal character. No masses or organomegaly were otherwise detected.

The patient was alert and oriented to time, place and person. Therefore, emergency surgery was discussed. The planned surgery was endovascular repair of the ruptured abdominal aortic aneurysm with a possibility of conversion to an open traditional repair. Endovascular stent graft repair of the ruptured abdominal aortic aneurysm along with selective right and left iliac artery angiograms and angioplasty of the right external iliac artery and the left common iliac artery was performed. The patient tolerated the procedures well and there were no complications. The patient was placed in the intensive care unit until he was stable and extubated. Hematocrit and electrolytes were monitored in addition to his distal pulses. He was also placed on aspirin and clopidogrel. Subsequent CT scans at one month, six months and 12 months after the procedure were arranged in order to check for the lack of an endoleak and to monitor the size of the aneurysm.

The patient was hospitalized for a total of 21 days. During that time repeat CT scans were performed one week after surgery and revealed no endoleak as well as a decrease in the size of the aneurysm (Figures 3, 4). The patient tolerated treatment well, remained stable and was discharged.

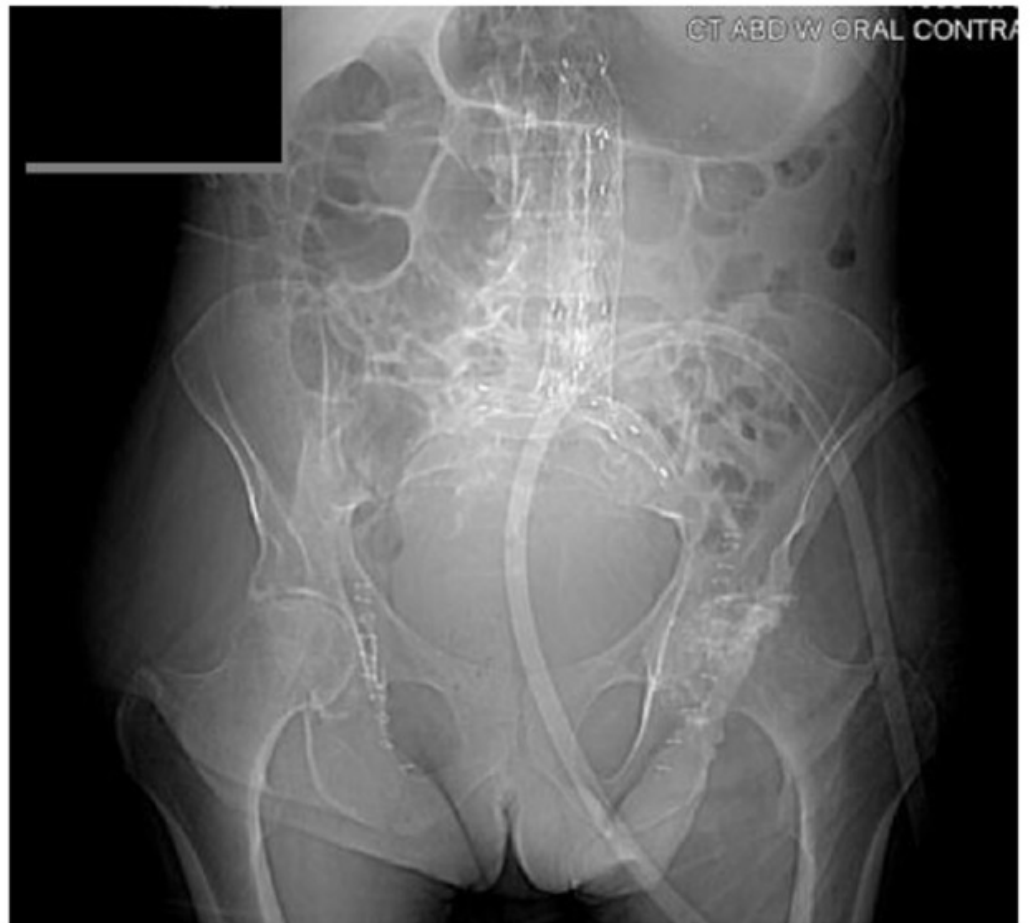

FIGURE 3: Plain CT scout film showing endovascular AAA stent graft in place

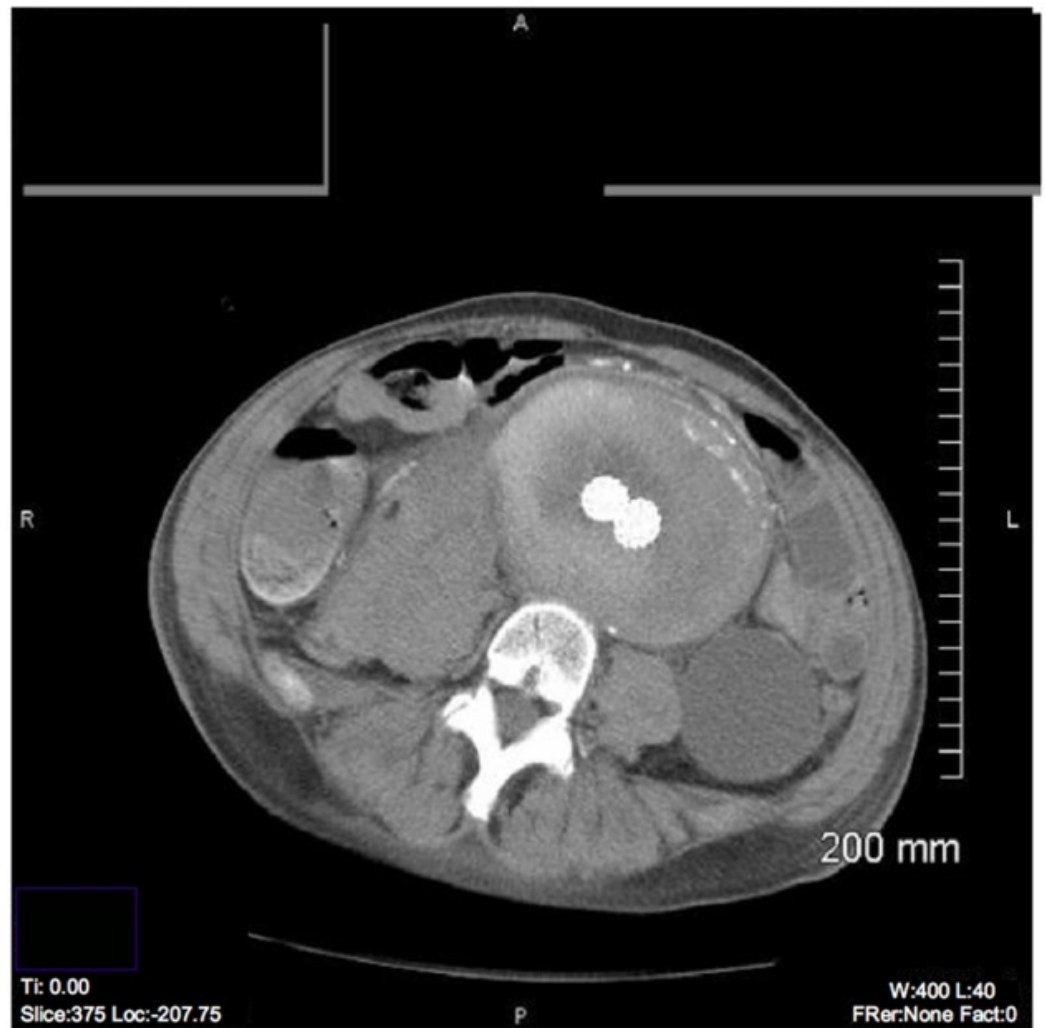


FIGURE 4: Post-operative CT showing endovascular stent graft

Post-operative CT showing endovascular stent graft in the center of the aneurysm, with contrast flowing through the two limbs of the graft. No endoleak is appreciated.

Procedure: The patient was brought to the endovascular suite and placed supine on the endovascular table. A Foley catheter was placed, and the abdomen, both groins, and from the knees to the nipple line was cleaned and prepared in a sterile manner. The entire procedure was done using angiographic and fluoroscopic guidance. The procedure was started by making incisions in the right and left groins down to the femoral arteries. Right and left groin dissections were made to the investing vascular bundles, the common femoral, superficial femoral, and the profundus femoris artery were isolated with large vessel loops, respectively. With the femoral artery exposed, access was first obtained in the right common femoral artery using a single wall entry needle, and a 0.035 guide wire was advanced with fluoroscopic guidance to the abdominal aorta. A 5 French sheath was placed over the guide wire in the common femoral artery for hemostasis. Similar access was obtained for the left common femoral artery. A guide wire was placed and a 5 French sheath also placed for hemostasis. An aortogram was performed visualizing the renal arteries, the neck of the aneurysm and the aneurysm itself from the bifurcation to the proximal iliac arteries.

An angioplasty of a high-grade stenosis of the right external iliac artery and left common iliac artery was done to facilitate device passage to the aorta. A repeat hand-injected angiogram was

done which revealed complete resolution of the stenosis. An AneuRx® (Medtronic, Santa Rosa, California) stent graft was then passed up into the suprarenal aorta, carefully pulled back to just below the lowest renal artery, then deployed to the distal portion of the aneurysm. Medtronic compliant balloons were used at the level of the proximal aorta and then in a kissing fashion all the way down to the separate iliac limbs simultaneously. This was done via right and left access. A pigtail catheter was placed in the suprarenal aorta, and using 20m1 bolus of contrast a view of the renal arteries and the distal runoff was obtained. No obstruction or endoleaks were seen in both proximal and distal iliac limbs. The sheaths were withdrawn and the femoral incisions irrigated. The arteries were closed on both sides using 5-0 Prolene endovascular suture. The wounds were irrigated and closed. There were no complications. The patient was sent to the recovery room in stable condition still intubated, and was extubated without incident before going to the intensive care unit.

Discussion

When a patient presents to the emergency department with the signs and symptoms of a ruptured AAA, the emergency department physician must move quickly to establish hemodynamic stability. The physician must then contact the surgeon, who then must evaluate the patient and the diagnostic results in order to determine whether an open repair or an endovascular repair is the most appropriate for the patient. Although the traditional open repair has been the established approach, there are substantial risks from this surgical procedure. In recent years, the use of endovascular repair for ruptured AAA's has been on the rise [8]. In several studies, the feasibility and the effectiveness of EVAR in the reduction of short-term mortality has been documented [9-10]. One meta-analysis of over 50 years of data determined the overall mortality rate for open repair of ruptured AAA repair to be 48% [11]. This study also concluded that the mortality rate for ruptured AAA repair has actually been decreasing over time. An additional meta-analysis conducted using outcomes from 1991-2006 found the overall mortality rate was steady at 48.5% when using an open approach to repair ruptured AAA [12]. In contrast to this, the overall mortality rate for endovascular of ruptured AAA has been reported at 24% by one literature review [13-14]. This is taken in context with the acknowledgement that there is a patient selection bias involved when designating some patients to receive endovascular versus open repair. These statistics indicates that EVAR has a lower mortality rate than the open repair, and that EVAR may be a better option for treating ruptured AAA provided there is favorable anatomy, a surgical team knowledgeable in endovascular repair, and there are effective protocols in place at the treating institution [15].

This case of the endovascular repair of an enormous 11 cm ruptured AAA highlights some very important issues facing the delivery of competent, quality medical care in the community hospital setting. This repair was done by a general surgeon with additional training in endovascular procedures in the setting of a primary, community hospital without the highly specialized facilities or staff which one would find at a tertiary or quaternary provider. If this patient had presented to another community hospital in the area, which lacked specialized vascular intervention services or a surgeon trained in endovascular repairs, this patient very well may have died while waiting on transfer. Because of the well-documented issues with transfer, even since the implementation of EMTALA, it is important for community general surgeons to be trained for and ready to treat any of a myriad of emergencies that could walk through the door [16].

The patient tolerated surgery and recovered well. CT angiography was repeated one and six months after the procedure and showed no evidence of endoleak (data not shown). A CT angiogram was scheduled for 12 months after the procedure. The patient relocated to an assisted living facility and every attempt has been made for a follow-up. Life expectancy for a patient with AAA is lower than the general population [5]. The average life expectancy of a 65 year old is 11 years post AAA repair [5]. Loss to follow-up usually poses significant problems to the evaluation of the interventions, since patients cannot be assessed postoperatively. Our patient,

however, is still alive and remains stable. A CT angiogram to assess his status and size of aneurysm is pending.

Conclusions

This is one of the largest ruptured AAA's to ever be successfully managed and reported in the literature. We present this case to demonstrate the potential effectiveness of the endovascular approach for managing even very challenging cases in the setting of a local community hospital.

Additional Information

Disclosures

Conflicts of interest: The authors have declared that no conflicts of interest exist.

Acknowledgements

To date this is one of the largest endovascular repaired ruptured abdominal aortic aneurysm done at this community hospital and in the literature as far back as 1992. The procedure was done at North Shore Medical Center in South Florida, and was carried out by Hakan Charles-Harris, M.D, Vice-Chief of Staff, a general surgeon who has over the years acquired the skills needed to be proficient in the field of endovascular procedures. He recently became an Endovascular Diplomate in the American Board of Vascular Medicine, Endovascular which demonstrates knowledge skills and expertise to practice within the field of endovascular medicine, such as this endovascular repair of ruptured AAA. This surgeon has done in excess of 1600 endovascular cases since 2004. His most recent appointment is Director of Endovascular Institute for Florida International University, Herbert Wertheim College of Medicine, at Jackson North Medical Center. He is responsible for developing this program de novo.

References

1. Patel MI, Hardman DT, Fisher CM, Appleberg M: Current views on the pathogenesis of abdominal aortic aneurysms. *J Am Coll Surg* . 1995, 181:371-382.
2. Parodi JC, Palmaz JC, Barone HD: Transfemoral intraluminal graft implantation for abdominal aortic aneurysms. *Ann Vasc Surg*. 1991, 5:491. [10.1007/BF02015271](https://doi.org/10.1007/BF02015271)
3. Rayt HS, Sutton AJ, London NJM, Sayers RD, Brown MJA: systematic review and meta- analysis of endovascular repair (EVAR) for ruptured abdominal aortic aneurysm. *Eur J Vasc Endovasc Surg*. 2008, 36:536-544. [10.1016/j.ejvs.2008.08.008](https://doi.org/10.1016/j.ejvs.2008.08.008)
4. Lederle FA, Freischlag JA, Kyriakides TC: Outcomes Following Endovascular vs Open Repair of Abdominal Aortic Aneurysm. *JAMA*. 2009, 302:1535-1542. [10.1001/jama.2009.1426](https://doi.org/10.1001/jama.2009.1426)
5. Schermerhorn M: A 66-Year-Old Man With an Abdominal Aortic Aneurysm: Review of Screening and Treatment. *JAMA*. 2009, 302:2015-2022. [10.1001/jama.2009.1502](https://doi.org/10.1001/jama.2009.1502)
6. Leurs U, Buth J, Laheij RJF: Long-term Results of Endovascular Abdominal Aortic Aneurysm Treatment with the First generation of Commercially Available Stent Grafts. *Arch Surg* . 2007, 142:33-41. [10.1001/archsurg.142.1.33](https://doi.org/10.1001/archsurg.142.1.33)
7. McPhee J, Eslami MH, Arous EJ, Messina LM, Schanzer A: Endovascular treatment of ruptured abdominal aortic aneurysms in the United States (2001-2006): a significant survival benefit over open repair is independently associated with increased institutional volume. *J Vasc Surg* . 2009, 49:817- 826. [10.1016/j.jvs.2008.11.002](https://doi.org/10.1016/j.jvs.2008.11.002)
8. McPhee JT, Hill JS, Eslami MH: The impact of gender on presentation, therapy, and mortality of abdominal aortic aneurysm in the United States, 2001-2004. *J Vasc Surg* . 2007, 49:817- 826.
9. Orend KH, Kotsis T, Scharrer-Palmer R, et al: Endovascular repair of aortic rupture due to trauma and aneurysm. *Eur J Vasc Endovasc Surg*. 2002, 23: 61-67. [10.1053/ejvs.2001.1546](https://doi.org/10.1053/ejvs.2001.1546)
10. Yılmaz N, Peppelenbosch N, Cuypers PW, et al: Emergency treatment of symptomatic or ruptured abdominal aortic aneurysms: the role of endovascular repair. *J Endovasc Ther*. 2002, 4:449-457. [10.1583/1545-1550\(2002\)009<0449:ETOSOR>2.0.CO;2](https://doi.org/10.1583/1545-1550(2002)009<0449:ETOSOR>2.0.CO;2)
11. Bown MJ, Sutton AJ, Bell PR, Sayers RD: A meta-analysis of 50 years of ruptured abdominal aortic

- aneurysm repair. *Br J Surg* . 2002, 89:714-73. [10.1046/j.1365-2168.2002.02122.x](https://doi.org/10.1046/j.1365-2168.2002.02122.x)
12. Hoornweg LL, Storm-Versloot MN, Ubbink DT, Koelemay MJ, Legemate DA, Balm R: Meta analysis on mortality of ruptured abdominal aortic aneurysms. *Eur J Vasc Endovasc Surg* . 2008, 35:558- 570. [10.1016/j.ejvs.2007.11.019](https://doi.org/10.1016/j.ejvs.2007.11.019)
 13. Rayt HS, Sutton AJ, London NJM, Sayers RD, Brown MJ: Asystematic review and meta-analysis of endovascular repair (EVAR) for ruptured abdominal aortic aneurysm. *Eur J Vasc Endovasc Surg*. 2008, 36:536-544. [10.1016/j.ejvs.2008.08.008](https://doi.org/10.1016/j.ejvs.2008.08.008)
 14. Alsac JM, Kobeiter H, Becquemin JP, Desgranges P: Endovascular repair for ruptured AAA: a literature review. *Acta Chir Belg*. 2005, 105:134-139.
 15. Veith FJ, Lachat M, Mayer D, et al: Collected World and Single Center Experience With Endovascular Treatment of Ruptured Abdominal Aortic Aneurysms. *Annals of Surgery* . 2009, 250:818-824. [10.1097/SLA.0b013e3181bdd7f5](https://doi.org/10.1097/SLA.0b013e3181bdd7f5)
 16. Menchine MD, Baraff U: On-call specialists and higher level of care transfers in California emergency departments. *Acad Emerg Med*. 2008, 15:329-36. [10.1111/j.1553-2712.2008.00071.x](https://doi.org/10.1111/j.1553-2712.2008.00071.x)